

Laparoscopic Evidence of Perforated Diverticulitis without CT, Colonoscopic or Laboratory Correlation.

A Peter, H Robert

Citation

A Peter, H Robert. *Laparoscopic Evidence of Perforated Diverticulitis without CT, Colonoscopic or Laboratory Correlation.* The Internet Journal of Surgery. 2007 Volume 15 Number 2.

Abstract

Diverticulitis is a well-recognized disease. Patients mostly present with pain in the lower left quadrant. On physical examination, a tender mass can be palpated. Laboratory findings usually show leukocytosis. In the majority of cases the diagnosis could be reached based on clinical and laboratory findings. The treatment constitutes bowel resting, i.v. antibiotics and high fiber diets. In unclear cases, ultrasound, CT and flexible colonoscopy could be carried out. Uncomplicated cases are treated medically. Exploratory laparoscopy is recommended in cases where a diagnosis could not be reached with the above mentioned tests. Surgical treatment is usually reserved for complicated cases. An early elective surgery is also recommended in young patients. This is, however, just a recommendation.

INTRODUCTION

Colon diverticula are mucosal pouches that protrude through the colonic musculature. Diverticulosis is the occurrence of many diverticula. The sigmoid is involved in about 90% of cases. Diverticulitis occurs when a fecalith is trapped within a diverticulum. This usually leads to thinning of the diverticular wall, resulting to micro-perforation and peridiverticular inflammation.

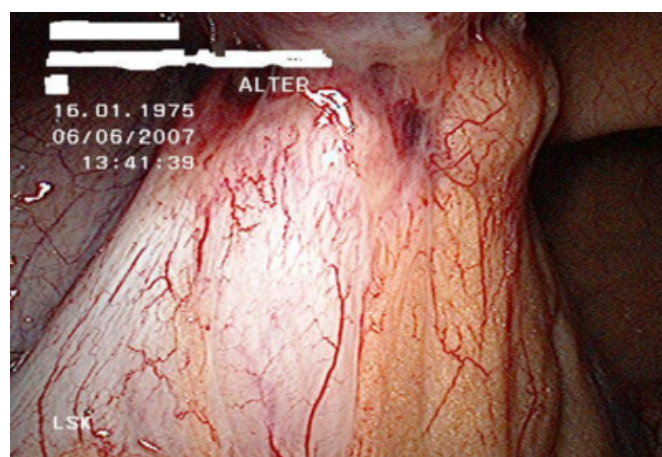
Diverticulitis of the sigmoid is a well-defined disease which is diagnosed based on characteristic clinical, radiological and coloscopy findings.

Patients present with left lower quadrant pain, fever and leukocytosis. Physical examination may reveal a palpable mass. An enhanced CT scan is the best diagnostic test for acute diverticulitis. Total colonoscopy with a flexible coloscope is performed after the acute phase of the disease.

We recently encountered a case of diverticulitis of the sigmoid that was not diagnosed on colonoscopy, with CT or with laboratory parameters but was later diagnosed on explorative laparoscopy.

Figure 1

Figure 1: Local peridiverticular inflammation with adhesion



CASE REPORT

A 33-year-old man was referred to the surgical department for evaluation of left lower quadrant pain. Five days prior to admission, he noted a gradual onset of crampy LLQ pain. He had had an episode of left lower quadrant pain 2 years earlier. A colonoscopy performed then was within normal limits. Physical examination revealed a palpable tender mass in LLQ with guarding and rebound.

A CT scan of the abdomen showed minimal signs of inflammation at the descendens-sigmoid junction without any sign of diverticles, perforation and/or abscess. The patient was put on a low-residue diet and treated with

intravenous (i.v.) antibiotics (Metronidazol 0.5g twice a day and cefuroxim 1.5g three times a day). Within 6 days, the clinical picture had improved, so a colonoscopy was performed. This showed no pathologies. Clinical chemistry was within normal limits.

We performed an explorative laparoscopy on the 7th day. This revealed a sealed perforated diverticle with local inflammation. The patient was discharged on day 8 and put on oral antibiotics.

Figure 2

Figure 2: Sealed perforation following adhesiolysis

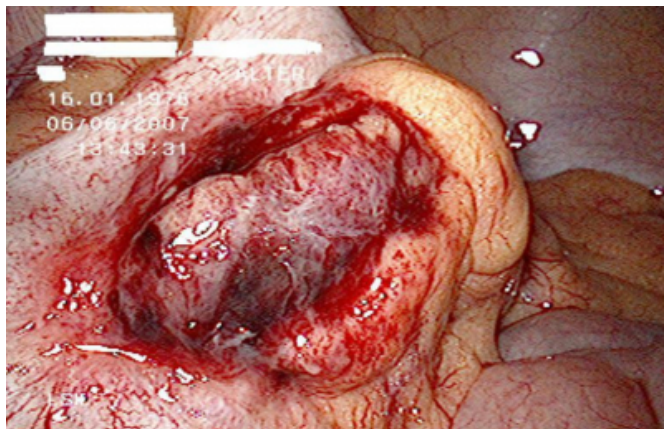
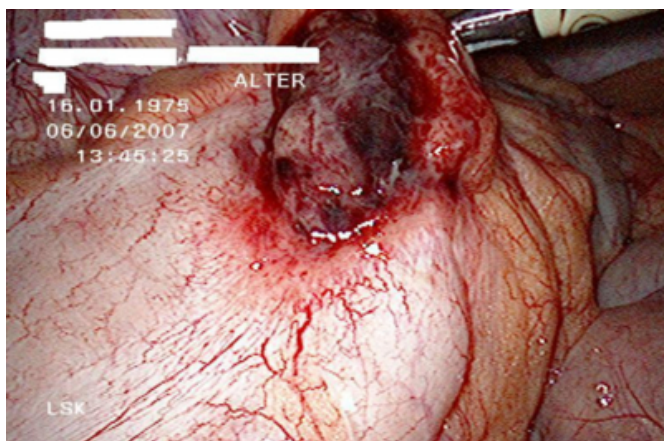


Figure 3

Figure 3: Sealed perforation with peridiverticular inflammation



DISCUSSION

Patients with acute diverticulitis usually present with fever, leukocytosis and left LLQ pain¹. The diagnosis could be made on the basis of clinical criteria; when the picture is clear; no other tests are indicated². In some cases, a tender mass could be palpated in the LLQ. The clinical scenario is not always a clear one. In such cases, ultrasound, CT or

colonoscopy is used. Ultrasound is fast, cheap and non-invasive with a sensitivity of about 90% and specificity close to 95%³. It is, however, operator-dependent. Moreover, the diagnostic value of ultrasound could be limited by the patient's physical state (obesity, or flatulence). In the acute phase of diverticulitis, a contrast enhanced CT scan is the preferred imaging test^{4,5}. Sigmoidocoloscopy is relatively contraindicated in acute diverticulitis.⁶

Prior to the advent of antibiotics, the surgical treatment was rare. The indications for surgery were restricted to the complications only (bleeding, obstruction and perforation). Today, the indication for elective surgery in diverticular disease is grossly made. Initially, the patients are treated with i.v. analgesics and broad spectrum antibiotics chosen to cover both anaerobes and aerobes. Patients who improve are sent home on low-residue diet. After the acute inflammation a high-fiber diet is recommended^{7,8}.

Elective surgery is recommended for patients with repeated episodes of diverticulitis, patients below 50 years or following pericolic abscess drainage.⁹

We believe the diagnosis of this disease should not be limited to the clinical criteria as proposed by Roberts et al.¹ We recommend a CT scan with oral, rectal and intravenous contrasting on the day of admission, or shortly after admission. In so doing, the degree of severity could be objectively determined. Possible complications could be anticipated and the appropriate therapy initiated in time to prevent complications.

Our patient was treated with i.v antibiotics and analgesics. He was put on low-residue diet and laxatives.

Based on the patient's subjective feelings and the surgeon's clinical impression, an early colonoscopy could be done to confirm the diagnosis and rule out other pathologies.

It is generally recommended that young patients undergo elective surgery after the first episode of diverticulitis. We believe that our patient (as many other young patients) had a solitary diverticle. Solitary diverticula could occur at any part of the colon, including the sigmoid. We recommend a gross indication for exploratory laparoscopy. The decision to do a resection of the sigmoid should be individualized, since the recurrence of the disease could be influenced by life style modification.⁸

CORRESPONDENCE TO

Dr. med. Peter C. Ambe Department of General and

Abdominal Surgery DRK Klinikum Westerwald Leuzbacher
Weg 21 57610 Altenkirchen, Germany E-mail:
peter.ambe@drk-kh-altenkirchen.de

References

1. Roberts P, Abel M, Rosen L, et al. Practice parameters for sigmoid diverticulitis. The Standard Task Force American Society of Colon and Rectal Surgeons. *Dis Colon Rectum* 1995; 38: 125-32
2. Wong WD, Wexner SD, Lowry A, et al. Practice parameters for the treatment of sigmoid diverticulitis--supporting documentation. The Standard Task Force. American Society of Colon and Rectal Surgeons. *Dis Colon Rectum* 2000; 43: 290-7
3. Schwark WB, Schwarz S, Rothmund M, Arnold R. Colon diverticulitis: imaging diagnosis with ultrasound - a prospective study. *Z Gastroenterol* 1993; 31: 294-300
4. Doring E. Computerized tomography of colonic diverticulitis. *Crit Rev Diagn Imaging* 1992;33:421-35
5. Hulnick DH, Megeibow AJ, Balthazar EJ, Naidich DP, Bosniak MA. Computed tomography in the evaluation of diverticulitis. *Radiology* 1984; 152: 491-495
6. Schechter S, Mulvey J, Eisenstat TE. Management of uncomplicated acute diverticulitis: results of a survey. *Dis Colon Rectum* 1999; 42: 470-5
7. Larson DM, Masters SS, Spiro HM. Medical and surgical therapy in diverticular disease: a comparative study. *Gastroenterology* 1976; 71: 734-7
8. Painter NS. Diverticular disease of the colon: the first of western diseases shown to be due to deficiency of dietary fiber. *S Afr Med J* 1982; 61: 1016-20
9. Eijssbouts QA, Cuesta MA, de Brauw LM, Sietses C. Elective laparoscopic-assisted sigmoid resection for diverticular disease. *Surg Endosc*; 1997; 11: 750-753

Author Information

Ambe Peter

Department of general and abdominal surgery, DRK Krankenhaus

Hanisch Robert

Department of general and abdominal surgery, DRK Krankenhaus