

Orbital Osteoma Of Ethmoidal Origin

A Cherkaoui, A Oudidi, N El alami

Citation

A Cherkaoui, A Oudidi, N El alami. *Orbital Osteoma Of Ethmoidal Origin*. The Internet Journal of Otorhinolaryngology. 2008 Volume 10 Number 2.

Abstract

Introduction:

Osteoma is the most frequent benign tumor of paranasal sinuses. Various theories have been advanced to explain the pathogenesis with difficulty to establish cause-effect relationship. Generally osteoma are asymptomatic and usually discovered by chance during radiological imaging. Resection of small and medium-sized osteomas of the paranasal sinuses can be safely and radically performed using endoscopic techniques with very good cosmetic effects. Giant osteomas can be effectively approached by a combined external and endoscopic procedure.

Observation

: Mr K.A. is a 19 years-old Caucasian male who came to consultation for a swelling of the medial angle of the left eye. Computed tomography images showed a ethmoidal process displaying a bone density consistent with an osteoma. The tumor was removed through an external ethmoidectomy. The patient was free of symptoms at 15 months follow-up. Conclusion: The rarity of ethmoidal osteoma with orbital growth made our cases interesting to report.

INTRODUCTION

Osteomas are the most frequent bone tumors of the facial region [1].

They frequently arise in the paranasal sinuses [2] mainly in the frontal and ethmoid ones. It rarely invades the orbital cavity and results in complications with ocular symptoms. We report a young man with an osteoma of his left ethmoid sinuses extending into the orbital cavity. This patient underwent an external ethmoidectomy approach for total removal of the huge tumor without any postoperative complications. The symptomatic presentation, diagnostic, evaluation and management of this uncommon tumor will be discussed.

CASE REPORT

A 19-year-old man visited our consultation in otorhinolaryngology department Hassan II university hospital for left orbital swelling, tracing his medical history, he had a minor left orbital trauma in playing soccer 1 year before. He took personally some pain drugs and he was too busy with his school work to comply with the doctor's advice. Unfortunately, progressing swelling was noted in the past few months in his medial angle of his left eye. We took him to ophthalmologist's consultation and ophthalmic examination showed normal visual acuity and visual field

without limited movement of the left eye.

Computed tomographic (CT) scans of the sinuses revealed a bony density lesion involving the left ethmoid sinus with extension to left orbital cavity (Fig. 1).

Due to the huge, hard and deeply embedded mass, a left lateral ethmoidectomy (Fig.2), was performed for total removal of the tumor from the ethmoid sinus and the orbital cavity. The tumor measured 3,5×3×3 cm in size (Fig.3) and the final pathology reports confirmed the clinical impression of osteoma. The vision of the left eye was well preserved. No residual tumor was found in the post-operative CT scan of sinuses. The patient was free of symptoms at 15 months follow-up.

Figure 1

Figure 1: CT-scan of the head showing the ethmoidal osteoma with intraorbital extension

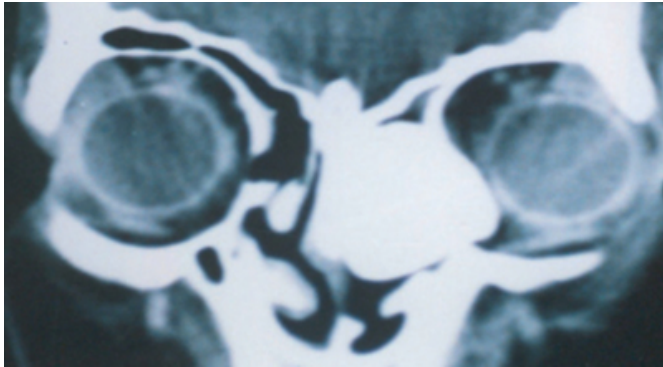


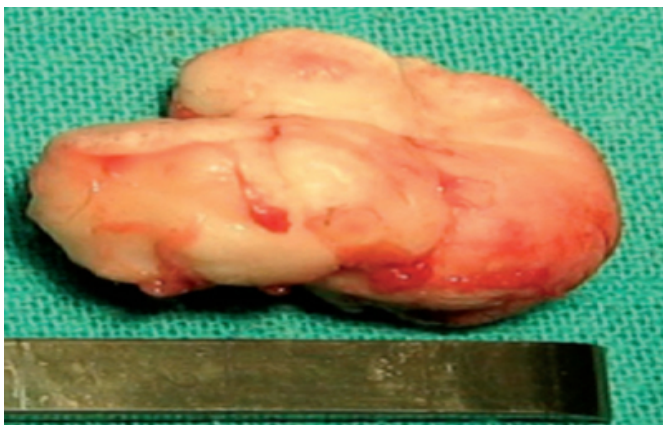
Figure 2

Figure 2: Perioperative aspect of the ethmoidal osteoma

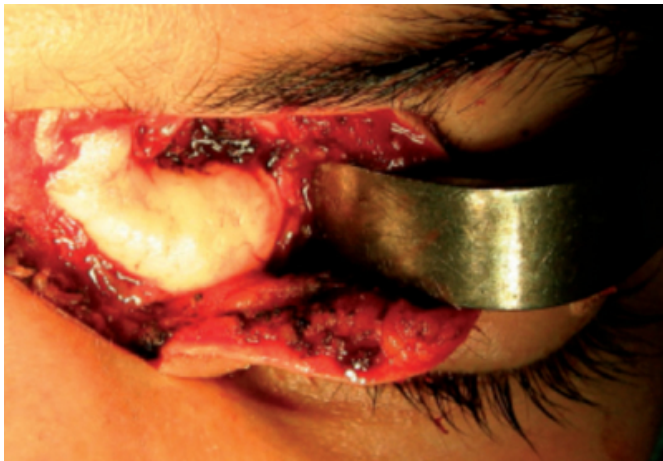

Figure 3

Figure 3: Aspect of the osteoma after it's surgical debulking



DISCUSSION

The osteoma is a mesenchymal tumor that develops at the expense of bones and sinuses of the face. The most frequent sites of origin are the frontal sinus in 71.8% [3] of cases, the

ethmoidal sinus in 16.9% (as described in our case), the maxillary sinus in 6.3% and the sphenoidal sinus in 4.9%.

Orbital localization of osteomas is particularly rare, and their incidence represents 0.9 to 5.1% of all orbital tumors [45].

The pathogenesis of these tumours still remains to be elucidated, but several theories have been advanced in this respect: [678].

The embryological theory suggests that these osteomas arise from osseous proliferation due to the apposition of membranous and enchondral tissue forming particularly close to the bone sutures.

The genetical factors are probably playing an important role in the development of osteomas included in Gardner's syndrome characterized by intestinal polyps and multiple osteomas.

The traumatic theory suggests that the development of these tumours is due to skeletal trauma in the past giving rise to a proliferative remanagement of the bone, particularly in males and during puberty, when skeletal growth is at its peak.

Infectious and inflammatory theory: very discussed, according to which the bony metaplasia is secondary to a chronic infectious and inflammatory state.

The majority of osteomas is asymptomatic at early stage and is found incidentally on radiographic examinations for other reasons. Symptoms and signs are related to the tumor size, location, and rate of growth. [9]. Headache or facial pain localized over the area of osteoma is the most common one [10]. The other symptoms include facial deformity, anosmia, rhinorrhea or secondary sinusitis [11]. When they extend beyond the confines of the sinuses, they may also produce orbital disorders including proptosis, orbital pain, decreased visual acuity, chemosis, diplopia, epiphoria or intracranial complications.

Radiological imaging, particularly A CT scan is a fundamental tool that not only permits diagnosis but also allows the correct surgical approach to be planned. The three-dimensional CT scan is even described as a tool to define the extension of ethmoid osteomas [12].

Due to the serious potential risks of surgery, osteomas of ethmoid sinus can be followed radiographically when they are asymptomatic. Surgery is performed only in the presence of symptoms and signs and rarely for aesthetic worries.

Surgical techniques are adapted to different indications. For large ethmoid osteomas lateral rhinotomy, midfacial degloving, osteoplastic flap, external ethmoidectomy [13].

In selected cases, endoscopic excision offering some aesthetic advantages and lowering the morbidity noted in the classical surgical technics [14]. For our patient, we chose the lateral ethmoidectomy approach in stead of the endoscopic approach because it would allow closer and more direct approach to the tumor as well as the best visualization of the orbital contents and the tumor extent during surgery.

Adequate resection of the tumor and lack of recurrences should be confirmed by postoperative imaging studies particularly CT scan in bone window [15].

CONCLUSION

Osteomas are slow-growing benign lesions. A ethmoidal osteoma as our case with deep extension into the orbit cavity is rare. Most osteomas are asymptomatic and are incidentally found on radiologic examinations. The CT scans are standard tests required for the planning of treatment. Surgery is generally accepted for symptomatic osteomas. Whether intranasal endoscopic or external approach, the best decisions must be made based on individual presentation.

References

1. Aldren CP, Soames JV, Birchall JP: Bony remodelling in an osteoma of the paranasal sinuses. *J Laryngol Otol*, 1993; 107: 633–35
2. Mikaelian DO, Lewis WJ, Behringer WH: Primary osteoma of the sphenoid sinus. *Laryngoscope*, 1976; 86: 728–33.
3. FOBE L.P., MELO E.C., CANNONE L.F., FOBE J.L. –[Surgery of frontal sinus osteoma. *Arq Neuropsiquiatr*. 2002; 60:101-5.
4. SELVA D., WHITE V.A., O'CONNELL J.X., ROOTMAN J. –[Primary Bone Tumors of the Orbit. *Surv Ophthalmol*. 2004; 49: 328-42.
5. SIRES B.S., BENDA P.M., STANLEY R.B. Jr, ROSEN CE. –[Orbital osteoid osteoma. *Arch Ophthalmol*.1999; 117: 414-5.
6. HALHAL M., NACIRI M., BERBICH O., BENABDELLAH W., BERRAHO A. –[Osteoma of the orbit, a case report. *J Fr Ophtalmol*. 2000; 23: 888-91.
7. Sudhoff H, Theegarten D, Luckhaupt H. Osteoma of the maxillary sinus *Laryngorhinootologie*. 2001 May;80(5):275-7.
8. WHITSON W.E., ORCUTT J.C., WELWINSHAW M.D. –[Orbital osteoma in Gardner's syndrome. *Am J Ophthalmol*. 1986; 101: 236-41.
9. GOLDENBERG D., GILBOA M., DANINO J., FLAX-GOLDENBERG R., MILLER B., JOACHIMS H.Z. –[A large ethmoido-orbital osteoma presenting with in an 11-year-old boy. *J Pediatr Ophthalmol Strabismus*. 2000; 37: 238-240.
10. Atallah N, Jay MM. Osteomas of the paranasal sinuses. *J Laryngol Otol* 1981;95:291-304.
11. Huang HM, Liu CH, Lin KN, Chen HAT. Giant ethmoid osteoma with orbital extension, a nasoendoscopic approach using an intranasal drill. *Laryngoscope* 2001; 111:430-432.
12. Karapantzios I, Detorakis E, Drakonaki E, Ganasouli D, Danielides V, Kozobolis P. Ethmoidal osteoma with intraorbital extension: excision throuh a transcutaneous paranasal incision. *Acta Ophthalmologica Scand*. 2005;83:392–394.
13. Yiotakis I, Eleftheriadou A, Giotakis E, Manolopoulos L, Ferekidou E, Kandiloros D. Resection of giant ethmoid osteoma with orbital and skull base extension followed by duraplasty *World J Surg Oncol*. 2008 Oct 14;6:110
14. Gerbrandy SJ, Saeed P, Fokkens WJ. Endoscopic and trans-fornix removal of a giant orbital-ethmoidal osteoma. *Orbit*. 2007 Dec;26(4):299-301.
15. Strek P, Zagólski O, Składziel J, Kurzyński M, Dyduch G Osteomas of the paranasal sinuses: surgical treatment options. *Med Sci Monit*. 2007 May;13(5):CR244-50.

Author Information

Amine Cherkaoui

Senior resident, Department of Otolaryngology-Head and Neck Surgery, Hassan II, University Hospital

Abdelatif Oudidi

Professor, Department of Otolaryngology-Head and Neck Surgery, Hassan II, University Hospital

Nouredine El alami

Professor, Department of Otolaryngology-Head and Neck Surgery, Hassan II, University Hospital