

# Subperiosteal Hematoma Of The Orbit Secondary To Sinusitis: Report Of An Unusual Case

M Turgut, Y Özsunar, ? Meteo?lu, H Eyigör

## Citation

M Turgut, Y Özsunar, ? Meteo?lu, H Eyigör. *Subperiosteal Hematoma Of The Orbit Secondary To Sinusitis: Report Of An Unusual Case*. The Internet Journal of Neurosurgery. 2008 Volume 5 Number 2.

## Abstract

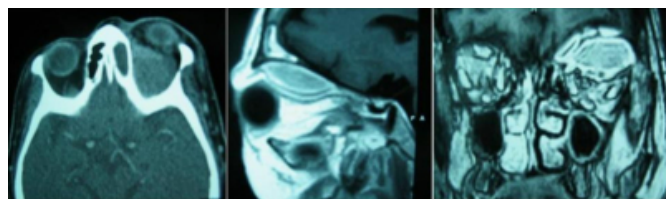
Subperiosteal hematoma of the orbit is a rare complication of ethmoidal sinusitis presenting most commonly in adults. The authors report a unique case who had subperiosteal hematoma of the orbit secondary to ethmoidal sinusitis. She was referred to our hospital with the diagnosis of orbital abscess and magnetic resonance imaging disclosed an extraconal mass in the upper part of the left orbit. A left frontal craniotomy was performed after aspiration of purulent material from ethmoid sinus using endoscopic approach, and a brownish black hematoma material was removed. This patient is the second reported case of subperiosteal hematoma of the orbit misdiagnosed as orbital abscess in the current literature. The presented case exemplifies the fact that early diagnosis and prompt intervention is very important to avoid possible complications often associated with this disease.

## CASE REPORT

A 70-year-old woman was presented with sudden onset of severe pain in the left orbital region and proptosis. The patient had been treated with systemic antibiotic treatment with the diagnosis of orbital cellulitis at another institution for two weeks, but she was afebrile and had no history of trauma, bleeding disorder, severe physical exertion, straining, or vomiting. Her medical history revealed hypertension. There was no change in the complaints of the patient over the course of the medical treatment, and she had been referred to our hospital with the diagnosis of orbital abscess.

### Figure 1

Figure 1: Axial contrast enhanced computed tomography (CT) scan (left), sagittal (centrum) and coronal (right) T1-weighted magnetic resonance images (MRIs), demonstrating a biconvex mass in the upper part of the orbit with downward displacement of the left eyeball

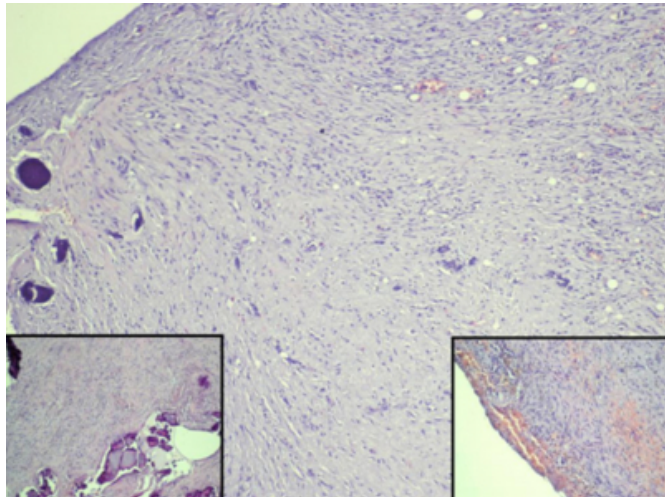


On clinical examination, neurological evaluation disclosed severely limited eye movement on upward gaze and associated prominent exophthalmos on the left. Her visual

acuity decreased to finger counting at 25 cm in the left eye and was 20/20 in the right eye. Fundusoscopic examination revealed edema of the left optic nerve head. No bruit or pulsation over the eyeball was detected. Laboratory findings were within normal limits. Computed tomography (CT) showed a slightly high-density mass without contrast enhancement in the left orbit as well as soft tissue obliteration of the maxillary, ethmoid and frontal sinuses on the left side suggesting sinusitis (Figure 1). Magnetic resonance imaging (MRI) disclosed a biconvex extraconal mass with isointense intensity both in T1- and T2-weighted images with downward displacement of the eyeball, suggesting methemoglobin of subacute hematoma (Figure 1).

## Figure 2

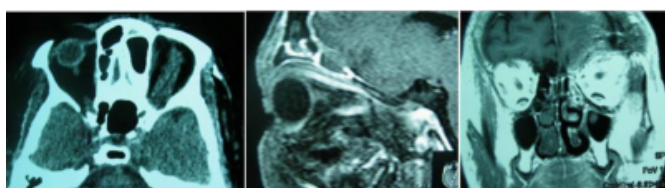
Figure 2: Microscopically, it was observed the capsule of an organized subperiosteal hematoma constituted by conjunctive tissue with the infiltration of inflammatory cells, focus of calcifications (left inset) and recent to old hemorrhages (right inset) (hematoxylin and eosin, original magnification, x100, x40, and x40, respectively)



Under general anesthesia, a left frontal craniotomy was performed after aspiration of purulent material from ethmoid sinus using endoscopic approach, and a brownish black hematoma material was removed after opening the orbital roof by the transcranial extradural approach. It was noted that there was no active bleeding. Histopathological examination of the subperiosteal material yielded a diagnosis of blood cyst wall composed of granulation tissue, scattered calcifications, and microhemorrhage (Figure 2). Her postoperative course was uneventful. The orbital pain disappeared completely, the proptosis and vision improved completely, and ocular movement became normal. Control CT and MRI studies confirmed the removal of the hematoma and no recurrence has occurred for two months after surgical intervention (Figure 3).

## Figure 3

Figure 3: Postoperative contrast enhanced axial CT scan (left), sagittal (centrum) and coronal (right) T1-weighted MRIs, showing complete removal of the hematoma and sinusitis material



## DISCUSSION

Subperiosteal hematoma of the orbit, also known as

subperiosteal hemorrhage or hematic cyst, is a relatively rare entity, presenting most commonly in adults, caused by trauma in the most of the patients. However, the subperiosteal orbital hematoma secondary to sinusitis is an unusual complication, only seven cases, including the present one, have been reported in literature written in the English language ( <sup>1,2,3,4,5,6</sup> ). It is suggested that subperiosteal orbital hematoma represents a stage preceding the development of subperiosteal abscess ( <sup>3</sup> ). To the best of our knowledge, this patient is the second reported case misdiagnosed as orbital subperiosteal abscess in the current literature.

Anatomically, subperiosteal orbital hematoma occurs in the superior orbital wall, because the periosteum is loosely attached to the underlying bone in the orbital roof with a large surface ( <sup>3,7</sup> ). Harris et al. ( <sup>1</sup> ) speculated that the pathogenesis of subperiosteal hematoma was the transmission of increased pressure from adjacent venous network to the orbital veins. When there is association with sinusitis, however, the pathogenesis of this disease is more associated to phlebitis in the sinus mucosa, which may extend to veins in the periorbita resulting in subsequent rupture of the vessels, than the transmission of increased pressure ( <sup>6</sup> ). Although subperiosteal orbital hematoma can be conservatively managed, surgical evacuation is necessary to identify the underlying causative disorder and to prevent late complications such as visual loss and restricted ocular movement, when visual function is compromised, as so in our case.

From the surgical point of view, a transcranial approach with removal of the orbital roof is the best choice for the evacuation of the subperiosteal material in some cases, although a less aggressive superior orbitotomy or anterior orbital drainage via a trans-lid access may be adequate to evacuate the subperiosteal material in some cases. The advantage of superior orbital decompression via a frontal craniotomy is that a very large amount of orbital bone can be removed, alleviating the mass effect of the intraorbital lesion. In these cases, early diagnosis and appropriate surgical therapy are very important to avoid severe risks, such as impaired vision, often associated with this disease, as did in our case.

In conclusion, the present article is a case report of a relatively unusual clinical condition, subperiosteal hematoma of the orbit. When one deals with a patient with acute onset proptosis and the imaging appearance we have

described, the differential diagnosis should also include a hematoma associated with paranasal sinusitis, although subperiosteal abscess is more common in association with sinusitis than hematoma.

## **CORRESPONDENCE TO**

Dr. Mehmet Turgut Cumhuriyet Mahallesi Cumhuriyet  
Caddesi No:6 Daire:7 TR-09020 Aydıncı, Turkey Tel:  
+90-256-2134874 Fax: +90-2562132172 E-mail:  
drmturgut@yahoo.com

## **References**

1. Harris G.J., Kay M.C., Nilles J.J. Orbital hematoma secondary to frontal sinusitis. *Ophthalmology* 1978;85:1229-1234.
2. Calcaterra T.C., Trap T.K. Unilateral proptosis.

- Otolaryngol Clin North Am 1988;21:53-63.
3. Choi S., Lawson W., Urken M.L. Subperiosteal orbital hematoma. *Arch Otolaryngol Neck Surg* 1988;114:1464-1466.
4. Ichino Y., Nagata M., Ishikawa T. Subperiosteal orbital hemorrhage associated with chronic sinusitis: a case report and review of the literature. *Auris Nasus Larynx* 1985;12:27-30.
5. Woo K.I., Kim Y.D. Subperiosteal hematoma of the orbit associated with sinusitis. *Korean J Ophthalmol* 1997;11:118-122.
6. Zalzal G.H. Periorbital hematoma secondary to sinusitis in a child. *Arch Otolaryngol Head Neck Surg* 1991;117:557-559.
7. Matsumoto S., Yamamoto T., Ban S., et al. Spontaneous subperiosteal hematoma of the orbit. Case report. *Neurol Med Chir (Tokyo)* 1994;34:27-29.
8. Chaves J.B., Batista M.S., Piske R.L., et al. Subperiosteal hematoma of the orbit: case report (in Portuguese). *Arq Bras Oftalmol* 2007;70:693-697.

**Author Information**

**Mehmet Turgut, MD, Ph.D.**

Assistant Professor of Neurosurgery, Department of Neurosurgery, Adnan Menderes University Medical Faculty

**Yelda Özsunar, MD**

Associate Professor of Radiology, Department of Radiology, Adnan Menderes University Medical Faculty

**İbrahim Meteolu, MD**

Assistant Professor of Pathology, Department of Pathology, Adnan Menderes University Medical Faculty

**Hülya Eyigör, MD**

Assistant Professor of Throat, Nose and Ear, Department of Throat, Nose and Ear, Adnan Menderes University Medical Faculty