

Layered Dermabrasion: A Simple Controlled Method For The Treatment Of Tattoos

J Mohammad

Citation

J Mohammad. *Layered Dermabrasion: A Simple Controlled Method For The Treatment Of Tattoos*. The Internet Journal of Plastic Surgery. 2006 Volume 3 Number 1.

Abstract

Objectives: Many methods of decorative skin tattoos removal have been attempted with varying rates of success. An innovative technique of combined operative and postoperative therapeutic method to remove such kind of tattoos is presented.

Methods: The study was conducted from 2002 till 2006. All patients with skin decorative tattoos were treated according to a standard surgical technique and protocol. Layered dermabrasion of the tattoos consists of deeper dermabrasion of the tattooed skin accompanied with superficial dermabrasion of the surrounding normal (non-tattooed) skin. Post operative skin care consists of applying different types of anti-scarring ointments with a silicone sheath.

Results: There were 26 male patients with decorative skin tattoos. The success rate was remarkable with high satisfaction rate by all patients. Post operative hypertrophic scarring rate was less than 9%.

Conclusion: Layered dermabrasion is a simple dermabrasion method which helps in treating decorative skin tattoos very efficiently. Such technique, with adequate post operative anti-scarring skin care, will ensure efficient removal of the tattoo pigments with loss of its features once the treated skin heals.

INTRODUCTION

Decorative skin tattoos represent colored foreign –body implantation into various depths of the dermis. As the desire for tattoo removal increases, researchers continue to explore safe, innovative and efficacious methods of tattoo removal (1,2,3). A technique for tattoo removal which produces selective removal of each tattoo pigment, with minimal risk of Layered Dermabrasion. A simple controlled method for the treatment of Tattoos scarring, is needed. Treatment options for tattoos are well described in the literature and must be individualized to each patient by the treating physician (4,5,6,7,8,9,10,11,12,13,14,15,16).

Most popular therapeutic technique of tattoos removals is utilizing laser therapy (17,18,19,20,21,22,23). Lasers continue to be a reliable and efficacious tool in treating amateur, professional, cosmetic and traumatic tattoos. However the financial cost of laser treatment prevents patients from undergoing such treatment (21, 23).

Another popular method of tattoo removal is dermabrasion, where the surgeon scrapes away the outermost layer of skin

with a rough wire brush, or a burr containing diamond particles, attached to a motorized handle (24, 26).

Dermabrasion surgical technique stimulates the production and growth of new collagen and skin tissue in which skin cells are more plentiful and better vascularized.

Layered dermabrasion is a method incorporates the use of equipment that is present in the usual plastic surgical office. The method is presented as a treatment of tattoos that are too large for simple excision. The surgeon can dermabrade deeply, if needed, and remove the skin pigments followed by more superficial dermabrasion of the surrounding normal skin. Once the skin heals, the residual skin scar will have a different shape from its previous tattoo. This method has produced excellent improvement in removal of skin tattoos, with acceptable obliteration of the original tattoo shape with high patient's satisfaction.

METHODS

Patient's data were collected from the year 2002 till 2006.

Twenty-six patients with a mean age of 26 years participated with 34 tattoos treated over a 4 years period (Fig-1).

Both types of amateur and professional tattoos were encountered. Local and general anesthetics were used depending on the size of the tattoo. A classical dermabrasion instruments with diamond head were used in this procedure. Layered dermabrasion of the tattoo first was performed till complete removal of all pigments. Pattern of dermal bleeding did help in assessing depth of skin layers removal. The skin was continuously moistened with wet gauze soaked with a mixture of saline and 1/200,000 epinephrine. Following complete removal of the tattoo, superficial dermabrasion of the normal skin was carried out in an irregular fashion to smoothen the skin edges around the tattoo (Fig-2). Topical broad-spectrum antibacterial ointment soaked gauze dressing is applied immediately to the wound following the procedure. All patients followed a post operative well established skin care regimen and supervised regularly by the author (27,28). All dressing was left intact for approximately a week and then the outer dressing was removed leaving the direct meshed gauze intact over the treated skin to separate spontaneously in 2-3 weeks. Once the gauze removed, the patient should apply moisturizing mixture of ointments, Alfacort (Julphar, UAE) containing 1% of hydrocortisone mixed with Contratubex gel (Merz pharma, Germany) twice daily for one more month. In the second month the patient were instructed to apply a silicone sheath over the skin. The treated areas were assessed on monthly basis for clinical evaluation of tattoos pigment removal and complications. All patients were asked to avoid direct exposure to the sun to the treated skin.

RESULTS

Twenty one patients (81%) had one tattoo, whereas five (19%) possessed bilateral tattoos. Most tattoos were applied for the sake of fashion. In those patients attending for removal, most tattoos are applied impulsively and inexpensively in youth. The main reasons for removal were enhancement of self-esteem and social, domestic and family reasons.

Following the surgery heavy eschar forms which separates in approximately 2 to 3 weeks. The residual skin results were excellent with remarkable patient satisfaction. The tattoos did disappear and the tattoos features were obscured by the surrounding healed skin (Fig-3).

Figure 1

Figure 1: A young 23 year old adult male with large decorative tattoo of his right arm.




Figure 2

Figure 2: Layered dermabrasion is completed. Pattern of dermal bleeding can guide the deep and superficial dermabrasion procedure.

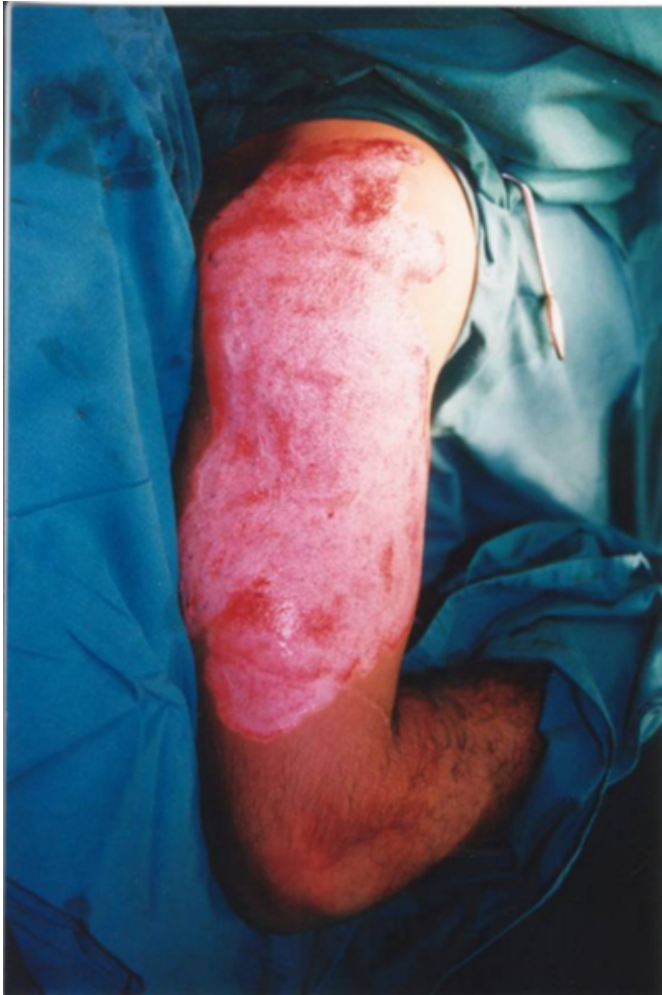
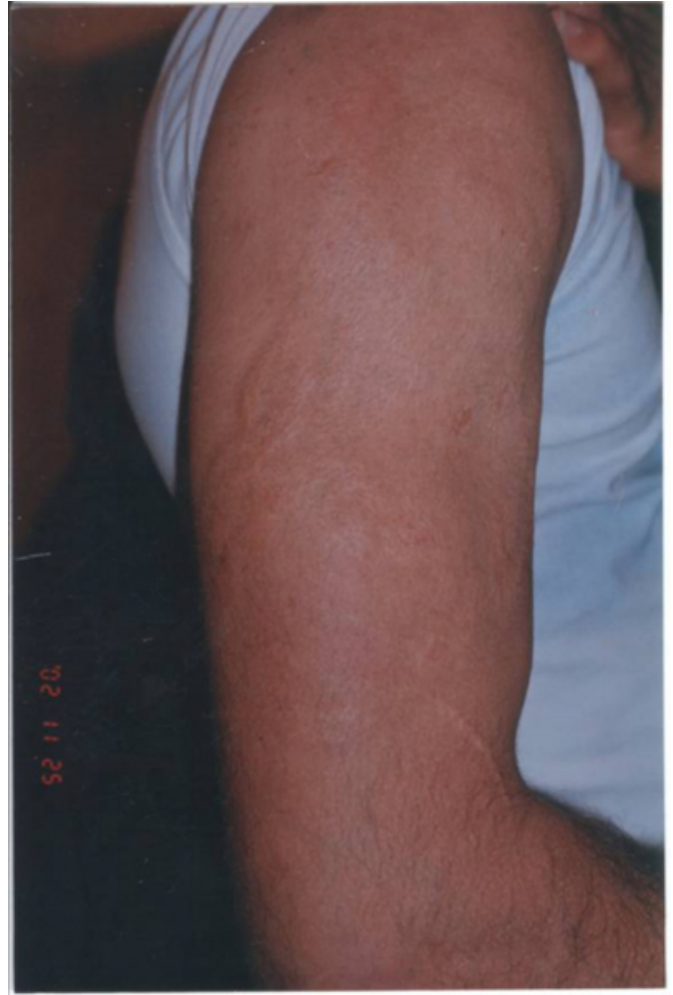
Figure 3

Figure 3: The patient 6 months following Layered dermabrasion. Excellent scar quality, with complete loss of definition of the previous patient tattoo.



Postoperative complications did occur in dark skin colored patients in which hypertrophic scarring rate were less than 8 % in two patients. Whereas, four patients (14%) experienced permanent hyper pigmented derma-braded skin. Incomplete removal of all tattoos pigments in the skin did occur in only one patient (4%) of which another session of layered dermabrasion was performed after 6 months from the initial procedure.

DISCUSSION

There are five types of tattoos: amateur, professional, cosmetic, medicinal, and traumatic (_{1,2,3,4,5}). Poor decision making and subsequent personal regret seem to be frequent motivations for tattoo removal. Important factors to consider when evaluating tattoos for removal are: location, age and the skin type of the patient (_{6,7,8,9}). We like also to add other important factors related to the tattoo such as: size, form and

shape of the tattoo.

Many authors have published numerous articles on the use of different methods with one aim, complete removal of tattoos with less scarring (16). Laser removal of tattoos is not

generally or readily available to the public and removal in privately run clinics is expensive. Limitations to laser treatment include the need for multiple treatment sessions, minimal to incomplete responses in some cases, and the possibility of pigment and textural changes with higher cost to the patient. Also, for those seeking removal of their tattoo this can create significant financial hardship. Chemical and surgical methods of tattoo removal usually associated with scars complications (8,9,10,11,12,13,14,15,16).

Regular dermabrasion method usually gives satisfactory results. Once used in an appropriate clinical setting, dermabrasion provides relatively efficacious clearance of decorative tattoo pigment. However, we have noticed the shape of the tattoo following dermabrasion still persist despite lacking some pigments. With layered dermabrasion technique it was possible to remove tattoo pigments in one session. The deep scraping of the pigmented skin will eventually heal within a superficially derma-braded surrounding normal skin. Thus, final shape of the healed skin will be poorly defined.

We should emphasize for the role of adequate post operative skin care to the operated skin. Such adjunct method will allow normal skin layers to heal, preventing further hypertrophic scar s formation.

CONCLUSION

Layered dermabrasion is a method of controlled surgical removal of decorative skin tattoos. Once combined with adequate postoperative scar skin care treatment, it will results in a complete removal of the tattoo with minimal scaring of the skin. It is a promising method for treating of decorative skin tattoos.

References

1. Buncke HJ Jr, Conway H. Surgery of decorative and traumatic tattoos. *Plast Reconstr Surg.* 1957 Jul; 20(1):67-77.
2. Boo-Chai K. The Decorative Tattoo: It's Removal by Dermabrasion. *Plast Reconstr Surg.* 1963 Nov; 32:559-63.
3. Bailey BN. Treatment of tattoos. *Plast Reconstr Surg.* 1967 Oct; 40(4):361-71.
4. Scutt RW. The chemical removal of tattoos. *Br J Plast Surg.* 1972 Apr; 25(2):189-94
5. Penoff JH. The office treatment of tattoos: a simple and effective method. *Plast Reconstr Surg.* 1987 Feb; 79(2):186-91
6. Koerber WA Jr, Price NM. Salabrasion of tattoos. A correlation of the clinical and histological results. *Arch Dermatol.* 1978 Jun; 114(6):884-8
7. Apfelberg DB, Manchester GH. Decorative and traumatic tattoo biophysics and removal. *Clin Plast Surg.* 1987 Apr; 14(2):243-51.
8. Dvir E, Hirshowitz B. Tattoo removal by cryosurgery. *Plast Reconstr Surg.* 1980 Sep; 66(3):373-9.
9. Lindsay DG. Tattoos. *Dermatol Clin.* 1989 Jan; 7(1):147-53.
10. Milroy BC. Tattoos and their removal. *Med J Aust.* 1993 Dec 6-20; 159(11-12):717-9
11. Dupont C. Decorative tattoos: analysis of 100 cases. *Acta Derm Venereol.* 1994 May; 74(3):236.
12. O'Donnell BP, Mulvaney MJ, James WD, McMarlin SL. Thin tangential excision of tattoos. *Dermatol Surg.* 1995 Jul; 21(7):601-3.
13. Camirand A, Doucet J. Needle dermabrasion. *Aesthetic Plast Surg.* 1997 Jan-Feb; 21(1):48-51
14. Sun B, Guan W. Treating traumatic tattoo by micro-incision. *Chin Med J (Engl).* 2000 Jul; 113(7):670-1.
15. Takushima A, Okazaki M, Harii K. Tattoo removal by grafting enzymatically separated epidermis. *Ann Plast Surg.* 2001 Oct; 47(4):398-403
16. Sweeney SM. Tattoos: a review of tattoo practices and potential treatment options for removal. *Curr Opin Pediatr.* 2006 Aug; 18(4):391-5. Review
17. Ruiz-Esparza J, Goldman MP, Fitzpatrick RE. Tattoo removal with minimal scarring: the chemo-laser technique. *J Dermatol Surg Oncol.* 1988 Dec; 14(12):1372-6.
18. Lanigan SW, Sheehan-Dare RA, Cotterill JA. The treatment of decorative tattoos with the carbon dioxide laser. *Br J Dermatol.* 1989 Jun; 120(6):819-25.
19. Troilius AM. Effective treatment of traumatic tattoos with a Q-switched Nd: YAG laser. *Lasers Surg Med.* 1998; 22(2):103-8.
20. Chang SE, Choi JH, Moon KC, Koh JK, Sung KJ. Successful removal of traumatic tattoos in Asian skin with a Q-switched alexandrite laser. *Dermatol Surg.* 1998 Dec; 24(12):1308-11
21. Varma S, Lanigan SW. Reasons for requesting laser removal of unwanted tattoos. *Br J Dermatol.* 1999 Mar; 140(3):483-5.
22. Suchin KR, Greenbaum SS. Successful treatment of a cosmetic tattoo using a combination of lasers. *Dermatol Surg.* 2004 Jan; 30(1):105-7.
23. Mariwalla K, Dover JS. The use of lasers for decorative tattoo removal. *Skin Therapy Lett.* 2006 Jun; 11(5):8-11. Review
24. Clabaugh WA. Tattoo removal by superficial dermabrasion. Five-year experience. *Plast Reconstr Surg.* 1975 Apr; 55(4):401-5.
25. Cronin ED, Haber JL. A new technique of dermabrasion for traumatic tattoos. *Ann Plast Surg.* 1996 Apr; 36(4):401-2.
26. Peris Z. Removal of traumatic and decorative tattoos by dermabrasion. *Acta Dermato-venereol Croat.* 2002 Mar; 10(1):15-9.
27. Hagerman RD, Cranmer LG, Bartok WR, Wilson JW. Topical medications on dermabrased tattoos. *Arch Dermatol.* 1970 Oct; 102(4):438-9
28. Willital GH, Heine H. Efficacy of Contractubex gel in the treatment of fresh scars after thoracic surgery in children and adolescents. *Int J Clin Pharm Res* 1994; 14:193-202

Author Information

Jamal A. Mohammad, MD, FRCSC (CANADA)

Consultant, Plastic and Reconstructive Surgery, Ministry of Health