

External jugular vein aneurysm: Clinical and radiologic imaging findings

B Battal, E Dursun

Citation

B Battal, E Dursun. *External jugular vein aneurysm: Clinical and radiologic imaging findings*. The Internet Journal of Head and Neck Surgery. 2008 Volume 3 Number 1.

Abstract

The venous aneurysm is a rare cause of a neck mass. Among neck veins, involvement of the anterior jugular vein is uncommon. The diagnosis is suggested by clinical features and can be confirmed by noninvasive radiology. There have been reports of assessment of cervical venous aneurysms by Doppler ultrasonographic examination and magnetic resonance (MR) angiography. In this case, we report clinical features and multi-detector computed tomography angiography (MDCTA) imaging findings of an external jugular vein aneurysm.

INTRODUCTION

Venous ectasias or aneurysms in the neck are rare entities. It may affect any vein in the neck [1]. The internal jugular vein is the commonest site of a venous aneurysm. The cause of venous aneurysm remains unknown. In some cases characteristic histological changes consisting of elastic tissue dysplasia have been demonstrated in the resected aneurysm wall [2]. The diagnosis of venous aneurysms can be achieved using ultrasonography (US) combined with doppler flow imaging, CT angiography and MR venography [3]. In this case, we report clinical features and MDCT angiography imaging findings of an external jugular vein aneurysm that enlarges on valsalva maneuver.

CASE REPORT

A 22-year-old male patient with a history of a mass in the right supraclavicular region was admitted to our otorhinolaryngology department. Physical examination revealed a soft, intermittent, non-tender, non-pulsatile swelling at the supraclavicular region. The mass became more prominent with valsalva maneuver. There was no history of trauma. The physical examination of the other systems was normal. Laboratory tests, chest and neck radiographs were normal.

The patient was referred to radiology department and scanned with a 16-detector CT scanner. Scan parameters were 120 kV, 340 mAs, 420 msec rotation time with a slice thickness of 1 mm and increments of 0.5 mm, using a detector collimation of 16 x 0.75mm (pitch: 0.2). A hundred

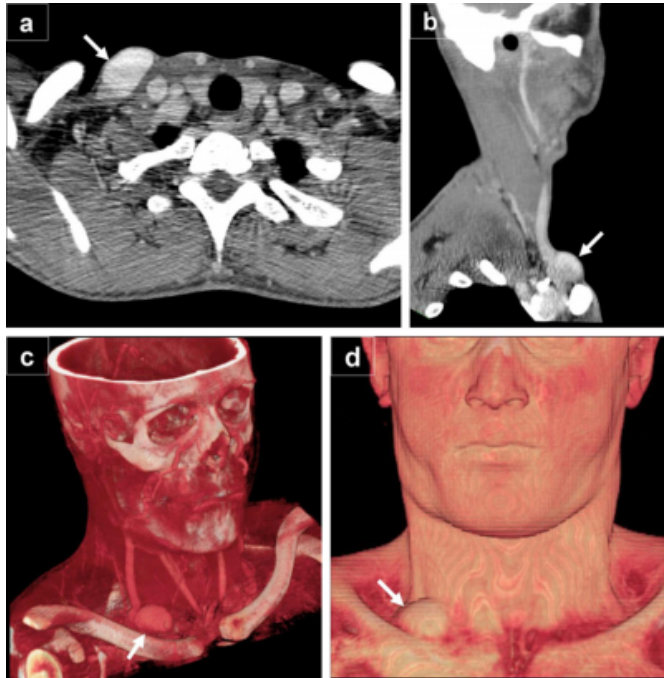
milliliters of non-ionic, iodinated, low-osmolar, contrast medium (Omnipaque® 350 mgI/ml) was injected through antecubital vein at a rate of 5 ml/sec. An automatic bolus tracking method was used to optimize visualization. CT examination was performed during valsalva maneuver. Arterial and venous structures of the neck were evaluated with post-processed images obtained by Multiplanar Reformation, Maximum Intensity Projection (MIP) and Volume Rendering techniques based on the axial scan.

MDCT angiography images demonstrated a saccular aneurysmatic dilatation at the proximal part of the right external jugular vein (Fig 1a-d). The internal jugular veins and carotid arteries were patent and normal.

We recommended surgical treatment but the patient refused surgery.

Figure 1

Figure 1: Axial (a), oblique sagittal maximum-intensity-projection (MIP) (b), and Volume-rendered (c,d) MDCT images show a saccular aneurysmatic dilatation at the proximal part of the right external jugular vein (arrows).



DISCUSSION

Venous aneurysm is a term describing an isolated saccular or fusiform dilatation of a vein [4]. Other terms have also been used in the literature including phlebectasia, venous cyst, venous ectasia, aneurysmal varix and venectasia [45]. They can be classified into primary (congenital) and acquired lesions; the former seem to be true aneurysms because they have an intact venous wall [6]. Venous aneurysms of the neck and chest are mostly congenital [7].

The causes of venous aneurysms remain unknown. Some reports suggest that venous aneurysms are developmental, perhaps secondary to a weakness of elastic fiber in the vessel wall [389]. Thinning in the elastic and muscular layers in the venous aneurysm has been observed during pathologic investigation. Matsuura et al [10] report that the thinning in the elastic layer is the most significant cause in terms of congenital fragility. Acquired aneurysms in the venous system develop with changes in the flow of blood and blood pressure. True venous aneurysms are rarely observed localized dilatations with no observations of hemodynamic changes. Etiologic factors of the neck venous aneurysms are tumors, thoracic outlet syndromes, trauma and inflammation.

Venous aneurysms have been reported in several anatomic

locations including cervical, thoracic, visceral, and lower extremities veins. Several cases of venous aneurysms involving the external jugular vein have been described in the literature [361112]. Jugular venous aneurysms should be included in the differential diagnosis of any neck soft tissue mass where it can be easily confused with cavernous hemangioma, cystic hygroma, laryngocele, lymphocele, enterogenous cyst, lymphadenopathy, thyroid swelling, thyroglossal cyst, dermoid cyst, and branchial cleft cyst [6].

The diagnosis of jugular aneurysm can be achieved using Doppler ultrasonography, contrast-enhanced CT examination, MR Venography and MDCT angiography. Following the introduction of ultimate MDCT equipment that has high temporal and spatial resolution, better depiction of the vascular structures has been possible. In addition to vessel lumen, the vessel wall can be evaluated with the help of MDCT images, which is an advantage over conventional coronary angiography. Reformatted and volume rendered images of MDCT facilitate to understand the malformations and anatomical variations, for both the radiologist and the clinician.

Venous aneurysms can produce complications like thrombus formation, pulmonary embolism, spontaneous rupture, and thrombophlebitis [13]. Venous aneurysms affecting the face and the neck tend to be asymptomatic and potential complications such as thromboembolism and rupture have not been reported. Surgical excision is indicated for cosmetic purposes or when there is a doubt in the diagnosis. Treatment is in the form of surgical excision [36].

CONCLUSION

Venous aneurysms in the neck are rare entities and it can be easily confused with other neck pathologies. MDCT has a wide range of applications, and enables both surgeon and radiologist to produce vascular mapping. Multiplanar and 3D reconstructed MDCT images are useful in the evaluation of the vascular pathologies, especially in complex part such as the neck.

CORRESPONDENCE TO

Bilal Battal, MD Sarikamis Military Hospital, Department of Radiology 36500, Sarikamis, Kars, Turkey E-mail: bilbat_23@yahoo.com Phone: 090 533 4330667 Fax: 090 474 4136264

References

1. Gilbert MG, Green berg LA, Brow WT, et al. Fusiform venous aneurysm of the neck in children: a report of four

- cases. *J Paediatr Surg* 1972;7:108-111.
2. Danis RK. Isolated aneurysm of the internal jugular vein: a report of three cases. *J Paediatr Surg* 1982;17:130-131.
3. Karapolat S, Erkut B, Unlu Y. Multiple Aneurysms of the Left External Jugular Vein *Turk J Med Sci* 2005;35:43-45.
4. Bowdler DA, Singh SD. Internal Jugular phlebectasia. *Int J of Pediatr Otorhinolaryngol* 1986;12:165-171.
5. Palleri V, Gopalakrishnan S. Jugular phlebectasia: theory of pathogenesis and review of literature. *Int J of Pediatr Otorhinolaryngol* 2001;57:155-159.
6. Al-Shaikh A, Kay S, Laberge JM. External jugular venous aneurysm: an unusual cause of a neck mass in a young child. *J Pediatr Surg*. 2003;38:1557-9.
7. Regina G, Squeo MA, Lillo A, et al. Aneurysm of the internal jugular vein-A case report. *Vasc Surg* 1988;22:169-171.
8. Chahlaoui J, Julien M, Nadeau PU, et al. Popliteal venous aneurysm a source of pulmonary embolism. *AJR* 1981;136:415-416.
9. Schatz IJ, Fine G. Venous aneurysms. *N Engl J Med* 1962;266:1310-1312.
10. Matsuura Y, Higo M, Yamashina H, et al. A case report of venous aneurysm of the neck. *Jpn J Surg* 1981;11: 39-42.
11. Ekim H, Özen S. Primary venous aneurysm of the external jugular vein. *EJM* 2002;7: 24-25.
12. Ceyran H, Akçalı Y, Oğuzkaya F, et al. Isolated jugular vein aneurysms. *Turk J Vasc Surg* 1999;1: 32-35.
13. Friedman SG, Krtishnasastry KV, Doscher W, et al. Primary venous aneurysms. *Surgery* 1990;108: 92-95.

Author Information

Bilal Battal, MD

Department of Radiology, Sarikamis Military Hospital

Engin Dursun, MD

Department of Otorhinolaryngology, Sarikamis Military Hospital