

Hemangioma of the Prepuce

E Santos, D Sarma

Citation

E Santos, D Sarma. *Hemangioma of the Prepuce*. The Internet Journal of Dermatology. 2005 Volume 4 Number 1.

Abstract

Hemangiomas (angiomas) are benign tumors of blood and lymphatic vessels commonly found in infants and children. They are usually superficial in nature, localized, and commonly involve the head or neck, although up to one-third may be seen in the liver. Total or partial regression of these lesions occurs in the majority of cases before puberty. Rarely has hemangiomas of the foreskin been described.

CASE REPORT

A 59-year-old white man presented with a 2-year history of progressively worsening post-void dribbling. No associated symptoms of hematuria, fever or dysuria were noted. On physical examination, the patient was uncircumcised with very tight phimosis of his foreskin. No genital skin lesions were noted. Multiple attempts to retract the foreskin were unsuccessful and he subsequently underwent an elective circumcision with no complications.

On gross examination, the received specimen consisted of two fragments of unremarkable foreskin with no grossly identifiable lesions.

On microscopic examination, the dermis showed numerous vascular spaces of various sizes with focal perivascular chronic inflammation. The overlying epidermis was unremarkable (Figures 1 & 2).

Figure 1

Figure 1: Foreskin, hemangioma (20x)

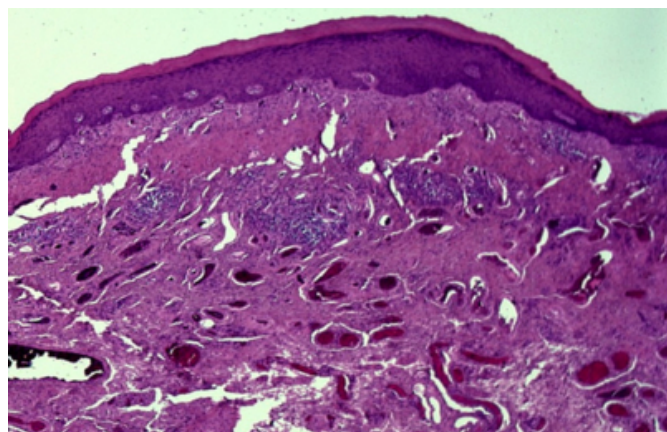
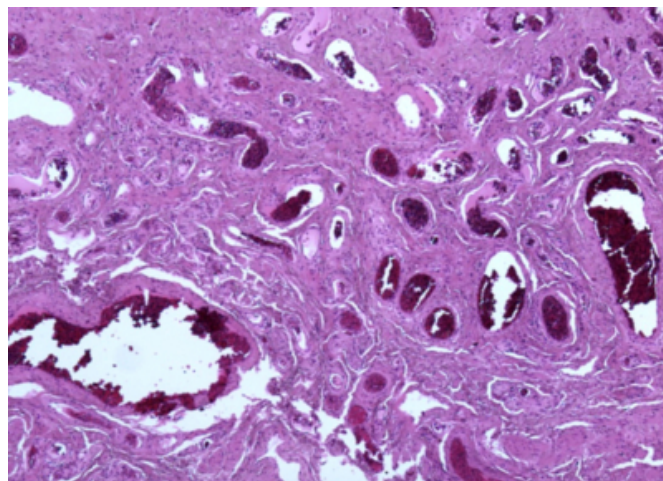


Figure 2

Figure 2: Hemangioma, higher magnification (40x)



COMMENTS

Hemangiomas (angiomas) are benign tumors of blood and lymphatic vessels commonly found in infants and children. They are usually superficial in nature, localized, and commonly involve the head or neck, although up to one-third may be seen in the liver. [1] Histologically, they are composed of aggregates of closely packed, thin-walled vessels, lined by flattened endothelial cells and usually blood-filled. Despite the numerous histological variants, total or partial regression of hemangiomas occurs in the majority of cases before puberty. [2]

Hemangiomas of the glans penis is a rare entity but has been previously reported. [3] Usually they are found in infants, children and young adults. After an extensive literature search, no well-documented cases of benign hemangiomas involving the foreskin of either a child or adult could be found. Two reasons probably account for the rarity of this

benign prepuce lesion. First, despite a steady decline in circumcision rates over the past 25 years, over half of the newborn, male population within the United States are circumcised. [4] Therefore, the availability of specimens to be examined from both children and adults is significantly limited. Secondly, if foreskin surgical specimens are made available for examination, the chances of seeing a hemangioma macroscopically are low. Subsequently, the chances of submitting the right representative section for microscopic examination are also low, leading to the rarity of this benign penile lesion.

CORRESPONDENCE TO

Deba Sarma, MD Creighton University Medical Center
Department of Pathology 601 North 30th Street Omaha, NE
68131 Email: dpsarma@yahoo.com

References

1. Kumar, Vinay, Abul Abbas, and Nelson Fausto. Robbins and Cotran Pathologic Basis of Disease. 7th ed. Philadelphia: Elsevier Saunders, 2005. 545-546.
2. Weedon, David. Skin Pathology. 2nd ed. London: Churchill Livingstone, 2002. 1009-1010.
3. Sharma, Gyanendra R. "Hemangioma of Glans Penis." The Internet Journal of Urology 3 (2005). 24 Feb. 2006 <http://www.ispub.com>.
4. Bollinger D. (2003) Intact Versus Circumcised: Normal versus Circumcised: U.S. Neonatal Male Genital Ratio. Circumcision Reference Library (an original online publication), 22 April 2003.

Author Information

Eric E. Santos, M.D.

Department of Pathology, Creighton University Medical Center

Deba Sarma, M.D.

Department of Pathology, Creighton University Medical Center