

Iopamidol Myelography Induced Status Epilepticus

H Dib, K Agan, I Midi, C Aykut-Bingol

Citation

H Dib, K Agan, I Midi, C Aykut-Bingol. *Iopamidol Myelography Induced Status Epilepticus*. The Internet Journal of Neurology. 2008 Volume 11 Number 1.

Abstract

A forty-eight year old woman presented with convulsive status epilepticus and respiratory arrest 45 minutes after a lumbar myelogram with iopamidol. Status epilepticus in epileptic patients are very rare complication after myelography with iopamidol and to our knowledge status epilepticus in non epileptic patients have been previously reported only in one patient. Although it is a rare complication, physicians should be aware of this potential complication, myelogram should be performed in a full organized hospital. It will be better to observe patients carefully after the procedure.

INTRODUCTION

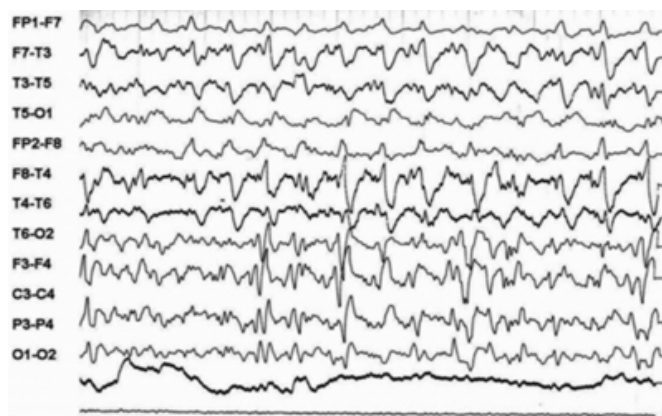
Iopamidol is a non ionic, water soluble contrast media, frequently used in myelography. Iopamidol myelography is associated with a risk of seizures in non-epileptic individuals^[1,2,3,4,5] and may induce status epilepticus (SE) in epileptic patients^[2]. We report that iopamidol myelography can induce SE in non-epileptic individuals.

CASE REPORT

A 48-year-old female patient with the history of spondilolisthesis was admitted to the hospital for a lumbar myelogram as a part of an investigation for intractable back pain. The patient's past medical history and medications was unremarkable except of this spondilolisthesis with instrumentation which is incompatible for MRI. There was no family history of seizure. Complete blood count and metabolic profile including calcium and function liver tests were normal. Forty five minutes after the injection of iopamidol the patient had generalized weakness, nausea and generalized tonic-clonic seizure of one minute duration. Subsequent to this convulsive seizure at some stage in the recording of EEG (Figure1) patient had two more seizures without improving consciousness.

Figure 1

Figure 1: Generalized high amplitude semi-rhythmic, synchronized spike or sharp and slow wave complexes with right sided predominance.



According to our SE treatment protocol we gave phenytoin (1250 mg) infusion. Due to the development of respiratory arrest under phenytoin infusion, she was immediately transferred to intensive care unit, intubated and set on mechanical ventilation. Intravenous midazolam infusion at a rate of 2 mg/kg/h was administered to control the seizures. Diagnosis of iopamidol myelography induced SE was made because other causes for the development of status could not be identified. EEG obtained at 72 hours after the contrast injection showed no epileptiform abnormality. A CT scan of the head at 72 hours was normal. She was slowly withdrawn from the intravenous administration of midazolam and demonstrated spontaneous movement of her extremities. She was able to follow verbal commands. The patient was successfully extubated and recovered without any sequels. She remained seizure free on follow up three year later

without any maintenance antiepileptic drug.

DISCUSSION

In this report, a female patient with SE after iopamidol myelography with normal laboratory, radiological findings and EEG is discussed.

Iopamidol is a non ionic contrast medium, safe, effective with fewer side effects in comparison with the oldest contrast medium. Seizures induced by iopamidol myelography in non-epileptic patients are very rare condition with the incidence of 0-0.847 %^[2]. The mechanism of seizure is due to idiosyncratic reaction or neurotoxic^[5]. Carchietti et al^[1], reported status epilepticus after iopamidol myelography in a non-epileptic patient and the authors postulated chronic alcoholism as a possible cause. Klein et al^[2] reported SE after iopamidol myelography in an epileptic patient despite antiepileptic drug used. Our patient differs from these two cases by no history of seizures, medications and any systemic illness. Although there is higher incidence of seizure induction for cervical as compared to lumbar myelography due to the different techniques used^[2], this report and the report previously described by Carchietti et al^[1] shows that SE is higher after lumbar myelography in comparison to cervical one reported by Klein^[2]. SE is an unpredictable

complication of iopamidol and is probably related to individual sensitivity. SE occurred 45 to 90 minutes after the injection of iopamidol^[12]. The prompt recognition of this complication is fundamental. The therapeutic approach of this rare side effect is to stabilize patient's vital sign and early mechanical ventilation until loading antiepileptic therapy is initiated. There is no need for maintenance antiepileptic drug therapy in the follow-up period.

In conclusion, iopamidol myelography is a very rare cause of SE and physicians should be aware of this potential side effect. If myelography should be performed for patients with contraindication to MR or CT imaging, it might be better to observe patients carefully after the procedure.

References

1. Carchietti E, Baldassarre M, Penco T, Leonardi M. Iopamidol 300-induced epilepsy: intensive treatment and pathogenic hypothesis. *Neuroradiology* 1988;30:256-7.
2. Klein KM, Shiratori K, Knake S, et al. Status epilepticus and seizures induced by iopamidol myelography. *Seizure* 2004;13:196-9.
3. Levey AI, Weiss H, Yu R, Wang H, Krumholz A. Seizures following myelography with iopamidol. *Ann Neurol.* 1988;23:397-9.
4. Lipman JC, Wang AM, Brooks ML, Schick RM, Rumbaugh CL.. Seizure after intrathecal administration of iopamidol. *Am J Neuroradiol.* 1988 ;9:787-8.
5. Olsen J. Seizures after myelography with iopamidol. *Am J Emerg Med.* 1994;12:329-30.

Author Information

H. Dib

Department of Neurology, Marmara University School of Medicine and Yeditepe University Hospital

K. Agan

Department of Neurology, Marmara University School of Medicine and Yeditepe University Hospital

I. Midi

Department of Neurology, Marmara University School of Medicine and Yeditepe University Hospital

C. Aykut-Bingol

Department of Neurology, Marmara University School of Medicine and Yeditepe University Hospital