

Fractal Analysis Of The Normal Human Retinal Vasculature

H Jelinek, M de Mendonça, F Oréface, C Garcia, R Nogueira, J Soares, R Junior

Citation

H Jelinek, M de Mendonça, F Oréface, C Garcia, R Nogueira, J Soares, R Junior. *Fractal Analysis Of The Normal Human Retinal Vasculature*. The Internet Journal of Ophthalmology and Visual Science. 2009 Volume 8 Number 2.

Abstract

Purpose: It has been proposed that retinal vessels are fractal and that fractal analysis could be applied in automated diagnosis of retinal diseases. Nevertheless, no standardized method has been proposed for image acquisition, processing and segmentation or for calculating the fractal dimension, resulting in great variability among the diverse research reports. The present study was designed to identify a suitable method for fractal analysis of retinal vessels without ocular disease and propose a standard for image acquisition, processing and fractal analysis. **Patients and Methods** Sixty-degree red-free retinographies with the fovea centralized were analysed. Images were segmented to extract their vascular trees using the wavelet transforms method and the fractal dimension of vascular trees was calculated by the box-counting method. **Results:** The box-counting fractal dimension of vascular trees followed a Gaussian distribution, with mean 1.43 and standard deviation 0.04. **Conclusion:** A standardized method was developed to accomplish fractal analysis of retinal vessels and is suggested for subsequent studies designed to evaluate the use of fractal dimensions in retinal neovascularization modeling and in developing methods for automated diagnosis of retinal vascular diseases.

INTRODUCTION

Past studies have proposed that the retinal vasculature is fractal and that fractal analysis could be applied to automated diagnosis of retinal vascular diseases^[1-6, 8, 9, 11, 12]. These studies have been conducted with the perspective that, since fractal geometry describes the morphogenetic laws of complex structures, they could be used in the mathematic modeling of blood vessel formation and in creating automated methods to diagnose retinal diseases.

In order to achieve this goal, a fundamental step when applying fractal analysis and automated diagnosis of retinal diseases is to identify/extract just the pixels corresponding to vessels from the rest of the retinal image, a process termed vascular segmentation^[7]. Various computational programs have been developed to accomplish vessel segmentation and have been compared with manual segmentation by an experienced retinal ophthalmologist (gold standard among vascular segmentation methods)^[16].

Segmentation directly alters the characteristics of the vascular image leading to differences in the fractal dimension values obtained with different segmentation methods^[1-5, 9-12] and the results are due to these

methodological differences including fractal analysis methods, rather than a reflection of real differences between their vascular trees.

An initial study observed that the utilization of different vascular segmentation and fractal analysis methods introduced significant differences on the estimation of the retinal vasculature fractal dimension^[14]. This result imposed the necessity to develop a vascular segmentation method whose effectiveness would be similar to that of the manual (gold standard) segmentation and propose a suitable fractal analysis method that differentiates with high accuracy between “healthy” vascular trees and “unhealthy” ones.

A suitable vascular segmentation program using wavelet transforms was developed by Soares and colleagues^[15]. The applicability of this segmentation software to fractal analysis was tested in another study in which it was shown that segmentation using wavelet transforms did not modify the values of the retinal vasculature fractal dimensions in relation to manual (gold standard) segmentation^[13].

The present study was designed to provide a range of fractal dimension values characterizing retinal vessels without

ocular disease, using a standardized image acquisition, processing and vascular segmentation method and to derive a suitable fractal dimension value for health images.

METHODS

SAMPLE CHARACTERIZATION, IMAGE ANALYSIS AND VASCULAR SEGMENTATION

Sixty retinographies under mydriasis from 30 volunteers were taken using a Canon CF-60UV camera. The subjects varied in age from 20 to 44 years, had normal visual acuity of 6/6, no ocular disease and small refractive error (less than 6 diopters). Ophthalmological examinations were conducted at the Hospital das Clinicas of the Federal University of Rio Grande do Norte and at Prontoclinica de Olhos, in Natal, Brazil. The volunteers gave informed written consent and the project was approved by the Research Ethics Committee of the University.

All the retinographies covered a 60 degrees field of view with the area of highest acuity, the fovea, centered. All images were obtained under redfree light and transformed to 8-bit grey scale, with a resolution of 936 * 936 pixels. The images were segmented using the wavelet transforms method by submitting each image to 20 Gaussian filters and adopting a binarization threshold fixed at 126. Fig. 1 shows the results of the segmentation method utilizing different numbers of Gaussian filters. The computational strategy adopted by the wavelet transforms method, patient retinal images and the results of the segmentation process applied to the retinographies from all of the patients and during the various stages of development has been reported^[15] and is also available at the projects website: www.ime.usp.br/~australia/mendonca.

After vascular segmentation, the box counting fractal dimension of the vascular trees were calculated.

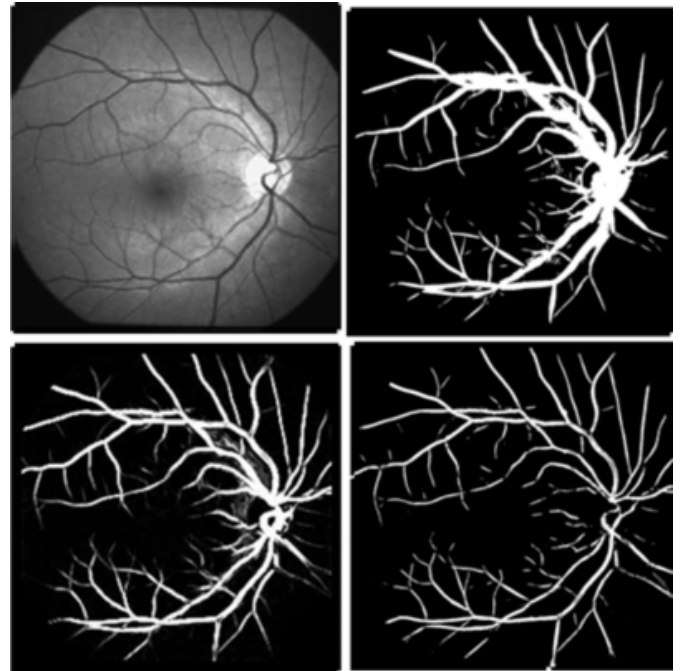
CALCULATION OF FRACTAL DIMENSIONS

To calculate the box-counting fractal dimension, 21 grids composed of quadrangular boxes with variable side length (r) were superimposed onto the images; the largest box size corresponded to one quarter of the side length of the image (234 pixels) and box size (measure scale) decreased according to a geometric progression, which was obtained by dividing box size by 1.3 at each stage, until the smallest box size of 2 pixels was reached. Each box was rotated in 10-degree increments, counting the number of boxes, $N(r)$, occupied by at least one pixel of the image, and recording, for each box size, the minimum number of boxes occupied

among the measures obtained when rotating the box, for each of the box sizes (scales).

Figure 1

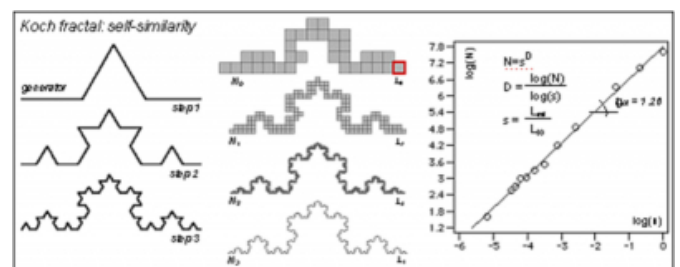
Fig. 1. Retinal image of patient A.L.C. Upper left original images, upper right, using just one Gaussian filter. Bottom left, using 5 Gaussian filters. Bottom right, 20 Gaussian filters.



The logarithmic values of $N(r)$ were represented as a function of the logarithm of the inverse of the side length of the boxes ($1/r$) and submitted to linear regression by the least squares method. The modulus of the first-degree coefficient of the resulting function (the slope of the log-log plot) is the box counting fractal dimension, as shown for a theoretical fractal, the von Koch curve in Fig. 2.

Figure 2

Fig. 2. The fractal dimension of Koch curve.



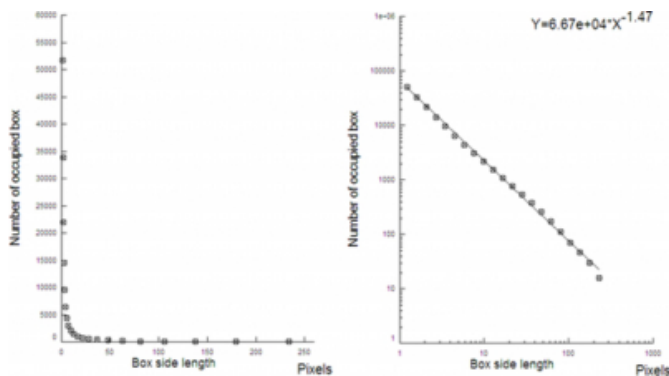
RESULTS

Fig. 3 shows the representation of the number (N) of boxes occupied by the vasculature as a function of the box side length (s), for the retinal vasculature. On the right, the log-

log plot of N as a function of s is shown with the corresponding regression line. The points are adjusted to fit the regression line for a range of scales equaling approximately 24, with Pearson's coefficient greater than 0.997 for all images. The modulus of the first degree coefficient (the slope) of the regression line is equal to the box-counting fractal dimension.

Figure 3

Fig. 3. Fractal dimension for image shown in Fig. 1.



The fractal dimension of the vascular trees followed a normal distribution, with mean (\pm standard deviation) 1.43 (\pm 0.04). There was no significant statistical difference between the right and left eyes and between the genders.

DISCUSSION

The values of fractal dimensions obtained in the present study were significantly lower than the values obtained in previous studies^[3, 5, 8, 9, 11, 12]. It is important to question whether the values of the fractal dimension could have deviated because of a possible “effect of the margins” of the image, such as rectangular versus circular margins, being the margins of the image “free” from vessels. It is also important to question if the restriction of the fractal analysis to a circular region of interest would generate higher values of the fractal dimension, annulling an eventual “effect of the margins”. In spite of this, no effort was made in the previous studies^[3, 5, 8, 9, 11] to annul the possible effect of the margins. Thereby the difference between fractal dimension values obtained in the present study and that obtained in the previous studies was not due to the effect of the margins nor to the absence of the use of a circular region of interest.

It is probable that the highest values of the fractal dimension obtained in some of the previous studies are a result of the utilization of the “mass-radius” method for calculating the fractal dimension^[5, 11]. In a previous study it was shown that the mass-radius method has low reliability to calculate the

fractal dimension of the retinal vasculature^[14]. Likewise the mass-radius method can lead to dimension values mistakenly high if the circles for counting of the “mass” are put in the foveal avascular zone. This subject has been extensively discussed in a previous article and therefore it is suggested to reject the mass-radius method to accomplish fractal analysis of retinal vasculature^[13].

Another possible explanation for obtaining higher fractal dimension values in some previous studies include angiofluoresceinographic images^[8, 11], where the contrast leak, or even the hyperfluorescence from the coriocalpilaris leads to misclassification of pixels as part of the vessel network. In addition, there was a large inter and intra-study variability among values of fractal dimensions in previous studies. This variability may be due to the utilization of retinal images with different resolution of retinal fundus^[5], different location of optic disk on the retinal image^[1, 3-5, 8, 9, 11], different methods for image acquisition (redfree, color or angiofluoresceinographic images), different segmentation methods and a different method to calculate fractal dimensions^[1-5, 8, 9, 11].

The present study did not use images from a databank but a standardized method for image acquisition and processing, for segmenting the vascular tree and for calculating the fractal dimension. The wavelet transform algorithm used for segmenting the image identifies the vessel boundary with good accuracy and is highly correlated with manual (gold standard) segmentation. There was also no statistically significant difference between the fractal dimension obtained from the manual versus the automated segmented images^[14].

Finally, the present study used the largest sample size among studies on fractal analysis of retinal vessels and is the only study to utilize a standardized method to characterize fractal dimensions of the retinal vasculature among subjects with no ocular disease. The fractal dimensions obtained here should be used in subsequent studies designed to evaluate the applicability of fractal analysis to neovasogenesis modeling and to automated diagnosis of retinal vascular diseases.

References

1. Avakian A, Kalina RE, Sage HE, Rambhia AH, Elliott KE, Chuang EL, Clark JI, Hwang J-N and Parsons-Wingerter P. Fractal analysis of region-based vascular change in the normal and non-proliferative diabetic retina. *Current Eye Research*; 2002; 24: 274-281.
2. Daxer A. Characterisation of the neovascularisation process in diabetic retinopathy by means of fractal geometry: diagnostic implications. *Graefes Archive of Clinical and Experimental Ophthalmology*; 1993; 231: 681-686.

3. Daxer A. The fractal geometry of proliferative diabetic retinopathy: implications for the diagnosis and the process of retinal vasculogenesis. *Current Eye Research*; 1993; 12: 1103-1109.
4. Daxer A. Mechanisms in retinal vasculogenesis: an analysis of the spatial branching site correlation. *Current Eye Research*; 1995; 14: 251-254.
5. Family F, Masters BR and Platt DE. Fractal pattern formation in human retinal vessels. *Physica D*; 1989; 38: 98-103.
6. Hooymans PM and Merkus FW. Current status of cardiac glycoside drug interactions. *Clin Pharm*; 1985; 4: 404-413.
7. Kirbas C and Quek F. A review of vessel extraction techniques and algorithms. *ACM Comput Surv*; 2004; 32: 81-121.
8. Landini G, Misson GP and Murray PI. Fractal analysis of the normal human retinal fluorescein angiogram. *Current Eye Research*; 1993; 12: 23-27.
9. Landini G, Murray PI and Misson GP. Local connected fractal dimension and lacunarity analysis of 60 degree fluorescein angiograms. *Investigative Ophthalmology and Visual Science*; 1995; 36: 2749-2755.
10. Landini G and Ripplin JW. Notes on the implementation of the mass-radius method of fractal dimension estimation. *CABIOS*; 1993; 9: 547-550.
11. Mainster MA. The fractal properties of retinal vessels: embryological and clinical perspectives. *Eye*; 1990; 4: 235-241.
12. Masters BR. Fractal analysis of the vascular tree in the human retina. *Annual Review of Biomedical Engineering*; 2004; 6: 427-452.
13. Mendonca AM and Campilho A. Segmentation of retinal blood vessels by combining the detection of centerlines and morphological reconstruction. *IEEE Transactions on Medical Imaging*; 2006; 25: 1200.
14. Mendonça MB, Garcia CAA, Nogueira RA, Gomes MAF, Valença MM and Oréface F. Fractal analysis of retinal vascular tree: segmentation and estimation methods. *Arquivos Brasileiros de Oftalmologia*; 2007; 70: 413-422.
15. Soares JVB, Leandro JJG, Cesar-Jr RM, Jelinek HF and Cree MJ. Retinal vessel segmentation using the 2-D Gabor wavelet and supervised classification. *IEEE Transactions in Medical Imaging*; 2006; 25: 1214-1222.
16. Staal J, Abramoff MD, Niemeijer M, Viergever MA and van Ginneken B. Ridge-based vessel segmentation in color images of the retina. *IEEE Transactions on Medical Imaging*; 2004; 23: 501-509.

Author Information

Herbert F. Jelinek

School of Community Health and Centre for Research in Complex Systems, Charles Sturt University

Marcelo Bezerra de Melo de Mendonça

Department of Surgery (Ophthalmology), Federal University of Pernambuco

Fernando Oréfice

Department of Ophthalmology, Federal University of Minas Gerais

Carlos Alexandre de Amorim Garcia

Department of Ophthalmology, UFRN

Romildo Albuquerque Nogueira

Department of Morphology, Rural Federal University of Pernambuco

João Victor Baldini Soares

Institute of Mathematics and Statistics, University of Sao Paulo

Roberto Cesar Marcondes Junior

Institute of Mathematics and Statistics, University of Sao Paulo