

Metastatic Gallbladder Cancer Diagnosed in a Hernia Sac

S Peralta, R Goldenkranz

Citation

S Peralta, R Goldenkranz. *Metastatic Gallbladder Cancer Diagnosed in a Hernia Sac*. The Internet Journal of Surgery. 2006 Volume 11 Number 1.

Abstract

The presence of cancer in a hernia sac is uncommon. We report a case of a 77-year-old female who presented to emergency room with an incarcerated inguinal hernia. At inguinal hernia repair the sac appeared indurated with evidence of calcifications. Histological examination showed metastatic adenocarcinoma of gallbladder origin.

INTRODUCTION

The finding of a neoplasm in a hernia sac is extremely rare and is reported to occur in less than 0.5% of examined hernia sacs.¹ Most of the knowledge on this subject is from case reports or case series. Metastatic disease from different primary tumors has been previously described.^{1,2,3,4,5,6,7,8,9} We report the case of a gallbladder cancer metastatic to a hernia sac.

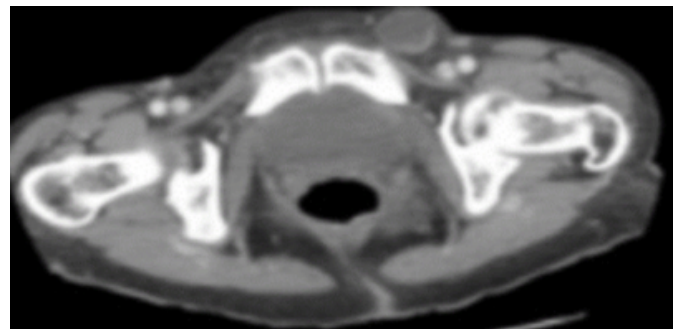
CASE REPORT

A 77-year-old African American female presented to the hospital with complaints of a painful mass in the left inguinal area. The patient had first noticed the mass 3 weeks before presenting to the hospital. She denied nausea, vomiting, diarrhea, constipation, chronic coughing, urinary hesitancy or heavy strain activity. The patient had an unremarkable past medical history.

On examination the patient was found to have a hernia in the left inguinal area, non reducible, of hard consistency, and tender. Her abdomen was soft, mildly distended, and there was no evidence of masses and a negative occult blood test at rectal examination. Laboratory results showed a hemoglobin of 12.4 g/dl., and electrolytes within normal limits. An abdomino-pelvic CT scan showed multiple low attenuation structures in the liver, evidence of omental caking, a contracted gallbladder and a 2.7 x 2.5 cm low attenuation structured on left inguinal region. (Figure 1)

Figure 1

Figure 1: Preoperative CT scan showing left inguinal hernia.

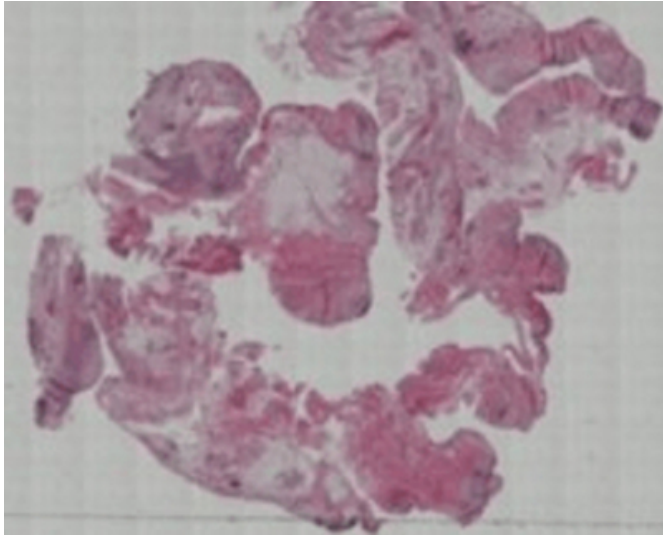


The patient underwent a left inguinal exploration; where an incarcerated inguinal hernia was found showing a 2x2 cm cystic structure mobile in the left inguinal ring, with evidence of calcification, induration and yellowish serous fluid. The hernia sac was dissected, removed and sent as a pathology specimen. The hernia was repaired in the usual manner with a Marlex mesh.

The pathology report showed that the hernia sac contained clusters of malignant cells adjacent to the lining. Malignant cells were of glandular structure, consistent with a neoplasm. Cam 5.2 was positive, CK 7 and CK 20 were focally positive. ER, PR and Vimentin were negative. BER EP 4 and E cadherin were positive. CEA was focally positive, Calretinin stains, mesothelial cells and mucin stains were positive. These findings were consistent with a mucin producing adenocarcinoma, most likely from the gastrointestinal tract. (Figure 2)

Figure 2

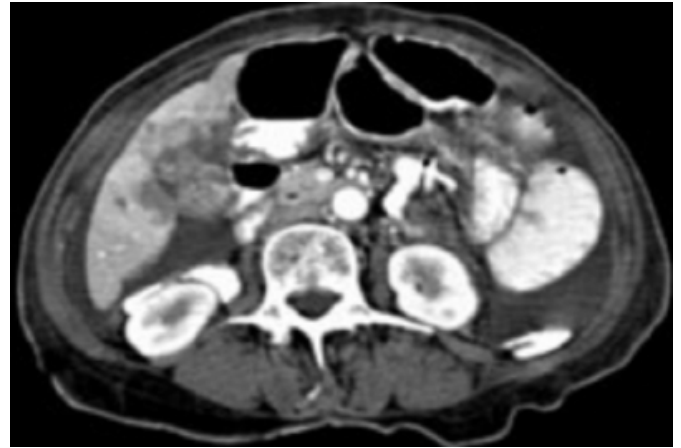
Figure 2: Histology of the hernia sac containing clusters of malignant cells adjacent to the lining, findings consistent with a mucin producing adenocarcinoma (hematoxylin and eosin staining magnification x 100)



A Thoraco/Abdomino/Pelvic CT scan showed a gallbladder full of stones and an adjacent inflammatory process involving the inferior portion of the liver and the gastric antrum, moderate ascites and mesenteric thickening (Figure 3). MRCP showed no evidence of a pancreatic mass; an abnormal enhancement of the gallbladder without obstruction or inflammation was evident. Endoscopy of the upper GI tract showed moderate gastritis and was positive for *Helicobacter Pylori*, colonoscopy showed a polyp of 1.5 cm in the descending colon, consistent with a hyperplastic polyp. Laboratory results disclosed that the patient's α -Fetoprotein (AFP) level was within normal limits at 1.6 ng/mL (reference range: <15 ng/mL), but CA 19-9, a marker for pancreatic cancer, was markedly high at 5724 U/mL (reference range: <33.0 U/mL).

Figure 3

Figure 3: Postoperative CT scan showing the gallbladder visualized full of stones and an adjacent inflammatory process involving the inferior portion of the liver and the adjacent gastric antrum, moderate ascites and mesenteric thickening.



The patient was referred for further treatment by the oncology service. A final diagnosis and treatment of metastatic gallbladder cancer was considered due to the pathologic and radiologic findings. She was advised about chemotherapeutic options and prognosis. The patient expired three weeks later before starting therapy.

DISCUSSION

The first case of a tumor within a hernia sac was reported in 1749.¹ Carcinoma of the colon is the most common primary tumor site associated with metastases to an inguinal hernia. Metastatic disease from cancers of the stomach, pericardium, tonsil, colon, rectum, breast and skin have been reported.^{1,2,3,4,5,6,7,8,9} There are previous reports of biliary tract disease metastatic to a hernia sac, but none of them has the gallbladder as a primary tumor.^{2,3}

Inguinal hernias are common, but metastatic lesions found within hernia sacs are extremely rare. The finding of an incarcerated hernia with constitutional symptoms such as weight loss and abdominal pain; and intraoperative findings of a calcified hernia sac, should raise suspicion of malignancy.^{1,2,6,7}

Previous studies have analyzed the use of routine histological examination of hernia sacs. The work of Kassan et al. examining 1020 herniorrhaphy specimens concluded that routine pathological study of normal-appearing hernia sacs was a poor diagnostic procedure and not cost-effective.⁸

When a clinician encounters a suspicious inguinal hernia, a preoperative CT scan should be considered, as discussed in previous reports.^{2,3,7} The discovery of a metastatic tumor in an inguinal hernia sac suggests advanced disease and short life expectancy.¹

CONCLUSION

A metastatic lesion in a hernia sac is a rare entity. The finding of a calcified hernia sac should prompt a histological analysis. The prognosis of a metastatic hernia sac tumor is dismal.

CORRESPONDENCE TO

Newark Beth Israel Medical Center Department of Surgery –
L3 Building 201 Lyons Avenue at Osborne Terrace Newark,
New Jersey 07112 Phone: (973)926-7000 E-mail:
soteroperalta@hotmail.com

References

1. Nicholson CP, Donohue JH, Thompson GB, Lewis JE. A

- study of metastatic cancer found during inguinal hernia repair. *Cancer* 1992 Jun. 1;69(12):3008-11.
2. Haseen, S. Metastatic carcinoma diagnosed in a hernia sac: a case report. *Contemporary Surgery* 2002; 58(11): 560-1.
3. Naoyuki Y, Shirai Y, Yamazaki, H, Hatakeyama, K. An inguinal hernia sac tumor of extrahepatic cholangiocarcinoma origin. *World Journal of Surgical Oncology* 2006 Mar 6; 4:13.
4. Oruc MT, Kulah B, Saylam B, Moran M, Albayrak L, Coskun F. An unusual presentation of metastatic gastric cancer found during inguinal hernia repair: case report and review of literature. *Hernia* 2002 Jul; 6(2):88-90.
5. Matsumoto G, Ise H, Inoue H, Ogawa H, Suzuki N, Matsuno S. Metastatic colon carcinoma found within an inguinal hernia sac: report of a case. *Surg Today* 2000; 30(1):74-7.
6. Lowenfels AB, Rohman M, Ahmed N, Lefkowitz M. Hernia-sac cancer. *Lancet* 1969; 1:651.
7. Goyal A, Mansel RE, Goyal S. Gastrointestinal stromal tumour in an inguinal hernia sac: an unusual presentation. *Postgraduate Medical Journal* 2003; 79:707-708.
8. Kassan MA, Munoz E, Laughlin A, Margolis IB, Wise L. Value of routine pathology in herniorrhaphy performed upon adults. *Surg. Gynecol. Obstet* 1986; 163:518-522.
9. Roslyn JJ, Stabile BE, Rangenath C. Cancer in inguinal and femoral hernias. *Am. Surg* 1980; 46:358-362.

Author Information

Sotero E. Peralta, M.D.

General Surgery Resident, Monmouth Medical Center

Robert Goldenkranz, M.D.

Director of General Surgery, Newark Beth Israel Medical Center