

# Giant mesenchymal hamartoma of the liver described as an ovarian cyst

G Ngom, C Moreira, G Woto-Gaye, M Fall, I Fall, M Ndoye

## Citation

G Ngom, C Moreira, G Woto-Gaye, M Fall, I Fall, M Ndoye. *Giant mesenchymal hamartoma of the liver described as an ovarian cyst*. The Internet Journal of Gastroenterology. 2007 Volume 7 Number 1.

## Abstract

We report a case of a giant mesenchymal hamartoma of the liver on a girl aged eighteen months. The suggested preoperative diagnosis based both on an ultrasonography and a CT scan was a right ovarian cyst. During the surgery a huge cystic mass of the liver was found, measuring 20cm diameter and which was easily extracted. Cytopathology examination of the surgical sample was then performed which revealed a mesenchymal hamartoma of the liver. The patient eventually recovered after four years outcome.

## INTRODUCTION

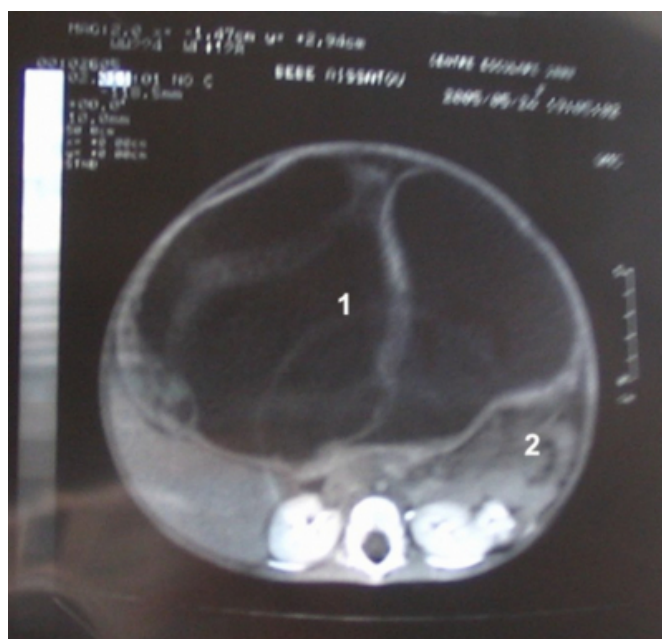
The mesenchymal hamartoma of the liver is a rare primitive tumour [1, 2]. It's seen essentially during childhood, especially during the first two years of life. Clinically there are no symptoms most of the time, whereas the diagnosis is suggested on a rapid abdominal enlargement or compression signs of neighbouring organs. The aspect on ultrasonography and on CT scan is strongly suggestive [3, 4]. However it might be difficult to diagnose it in front of a giant tumour occupying nearly the whole abdomen. We report an observation of a giant mesenchymal hamartoma of the liver described as an ovarian cyst on ultrasonography and CT scan.

## OBSERVATION

A girl aged 18 months was referred to our hospital for a rapid abdominal enlargement lasting for 4 months, without transit disorders or any notion of trauma previous to the symptoms. On examination, there was a huge liquid-like abdominal tumour, extended up to the pelvic area, with a major collateral venous circulation. The rectal digit examination did not feel the tumour. Blood tests were quite normal. Abdominal ultrasonography and CT scan showed a huge liquid density abdomino-pelvic mass with a thin wall and multiple septums, with compression signs (mass effect) on the abdominal viscera, suggesting rather a right ovarian cyst (figure 1).

## Figure 1

Figure 1: Aspect on CT scan

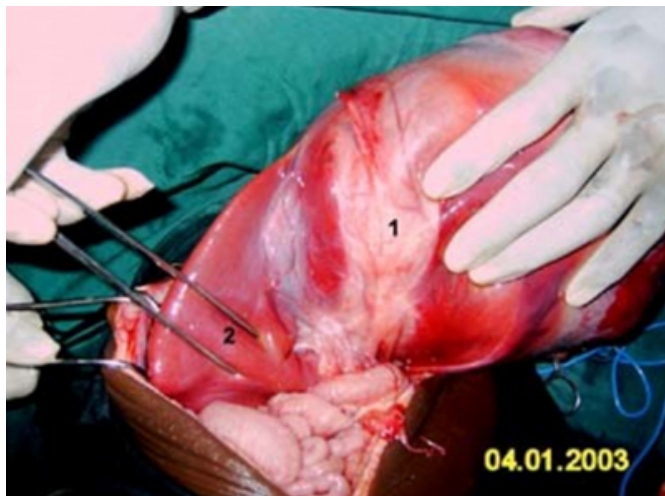


Legend: cystic mass (1) viscera on the right side (2).

A transverse laparotomy revealed a huge cystic tumour of the liver occupying the left lobe, measuring 20cm diameter and pulling back the loops at the level of the right lateral abdominal wall (figure 2).

**Figure 2**

Figure 2: Per operative view



Legend : tumour (1) normal liver (2)

A portion of the tumour was deep inside the liver parenchyma. The gall bladder, the ovaries and the other abdominal viscera were quite normal. There was also no ascites. A partial hepatectomy extracting the tumour had been done. The histopathology examination revealed a cystic mesenchymal hamartoma of the liver. The outcome after four years was favourable.

**DISCUSSION**

In our case, the preoperative diagnosis was difficult because of the size of the tumour. In fact, when an abdominal tumour is huge, it can hide the organ on which it has developed [5]. Thus, neither the ultrasonography nor less the CT scan could even suggest the diagnosis of hepatic tumour. It is the surgical exploration that has permitted to diagnose the

hepatic tumour which could have been in our case, taking the age of our patient in consideration, either a vascular hamartoma or a mesenchymal hamartoma of the liver. Finally it is the histopathology examination that has permitted us to diagnose mesenchymal hamartoma of the liver. As far as treatment is concerned, it seems to us that a large resection removing the tumour and a portion of the healthy parenchyma is the best option. In fact, some cases of malignant transformations have been described [7, 8].

**CORRESPONDENCE TO**

Dr Gabriel NGOM E-mail : gngom2004@yahoo.fr Tel: 00 221 77 552 00 80 BP: 6863 Dakar-Etoile

**References**

1. Barnhard DC, Hirschl RB, Garver KA, et al. Conservative management of mesenchymal hamartoma of the liver. *J Pediatr Surg* 1997; 32: 1495 - 8.
2. Stocker JT, Ishak KG. Hepatic tumor in children. *Clin Liver Dis* 2001; 5 : 259 - 81.
3. Rosenbaum DM, Mindell HJ. Ultrasonographic findings in mesenchymal hamartoma of the liver. *Radiology* 1981; 138: 425 - 427.
4. Liu P, Daneman A, Stringer DA. Diagnostic imaging in liver masses in children. *J Can Assoc Radiol* 1985; 36: 296 - 300.
5. Charles AR, Gupta AK, Bhatagar V. Giant congenital solitary cyst of the liver: Report of a case. *Surg Today* 2001; 31: 732 - 734.
6. Cavernani M, Vincenti A, Benci A, et al. Ecographic epidemiology of non-parasitic hepatic cysts. *J Clin Ultrasound* 1993; 21: 115-118.
7. O'Sullivan MJ, Swanson PE, Knoll J, et al. Undifferentiated embryonal sarcoma with unusual features arising within mesenchymal hamartoma of the liver: report of a case and review of the literature. *Pediatr Dev Pathol* 2001; 4: 482-9.
8. Ramanujam TM, Ramesh JC, Goh DW, et al. Malignant transformation of mesenchymal hamartoma of the liver: case report and review of the literature. *J Pediatr Surg* 1999; 34: 1684-1686.

**Author Information**

**Gabriel Ngom, MD**

Department of Pediatric Surgery, Aristide Le Dantec Hospital

**Claude Moreira, Ph.D.**

Department of Pediatric Oncology, Aristide Le Dantec Hospital

**Gisèle Woto-Gaye, PhD**

Department of Pathology, Aristide Le Dantec Hospital

**Mbaye Fall, MD**

Department of Pediatric Surgery, Aristide Le Dantec Hospital

**Ibrahima Fall, PhD**

Department of Pediatric Surgery, Aristide Le Dantec Hospital

**Mamadou Ndoeye, PhD**

Department of Pediatric Surgery, Aristide Le Dantec Hospital