

Nonsteroidal-Induced Benign Strictures of the Caecum: A Case Report And Review Of The Literature

S Gopalswamy, P Arumugam, M Feldman

Citation

S Gopalswamy, P Arumugam, M Feldman. *Nonsteroidal-Induced Benign Strictures of the Caecum: A Case Report And Review Of The Literature*. The Internet Journal of Surgery. 2007 Volume 17 Number 1.

Abstract

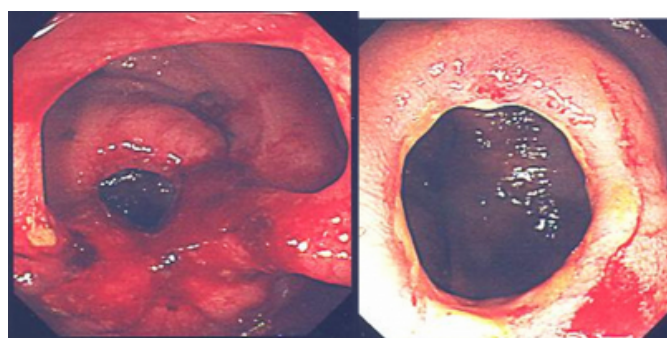
A rare complication seen with chronic use of sustained-release non-steroidal anti-inflammatory drugs (NSAIDs) is formation of bowel strictures and diaphragm-like disease with characteristic histological appearance of submucosal fibrosis. They are thought to result from alterations in enterocyte homeostasis. The strictures generally occur in the terminal ileum and right side of the colon with the symptoms of occult blood loss, change in bowel habits, weight loss, obstruction and rarely perforation. We report the case of a women diagnosed with caecal strictures who was taking slow-release diclofenac tablets for osteoarthritis.

CASE REPORT

A 70-year-old female referred to the outpatient clinic with 5 month history of change in bowel habits, weight loss, lethargy, iron deficiency anaemia and possible mass in the right iliac fossa. She had been taking diclofenac retard tablets for many years for her osteoarthritis. She was admitted for blood transfusion and started on iron therapy, and diclofenac was stopped. Gastroscopy was normal and CT colonoscopy showed possible Crohn's disease or malignant stricture in the caecum. Colonoscopy showed two strictures in the caecum (fig.) and the biopsies showed active chronic colitis.

Figure 1

Figure 1: Caecal strictures seen in colonoscopy.



In view of the uncertainty, she underwent right hemicolectomy with end to end anastomosis. She had uneventful recovery and remains well. Histology shows a circular stenosis in the caecal lumen measuring approximately 10 mm, the mucosa is otherwise normal. But

there is thickening of the muscularis mucosa and submucosal fibrosis consistent with diaphragm disease due to NSAIDs with no evidence of malignancy identified.

DISCUSSION

Side effects of NSAIDs on the upper gastrointestinal tract are well recognised. Less well known are the lesions of the lower gastrointestinal tract associated with their chronic use. Strictures and diaphragm-like disease in the proximal colon have been identified as rare complication of chronic use of some NSAIDs ¹. Diaphragm disease of the colon was first reported in 1989 ². There are only few case reports of diaphragm-like disease of colon in comparison to a large number of reported cases affecting the small bowel ⁴. The exact pathophysiology of colonic stricture is not clear. Nearly all documented cases have had iron deficiency anaemia. Patients presenting with these stricture have typically been elderly with chronic rheumatoid or osteoarthritis and symptoms of non-specific abdominal pain or change in bowel habits ^{1,6}. One case initially presented as perforation ⁷. The strictures can be difficult to differentiate macroscopically from cancer, diverticular disease and Crohn's disease ¹⁶.

The effects on the small and large bowel are thought to result from local phenomena related to prolonged contact of NSAIDs with bowel mucosa ¹¹. Localisation of inflammation in the distal ileum and proximal colon may be attributable to the hold-up of gastrointestinal contents there by the ileocaecal valve ⁶. However, Whittle ⁸ showed

mucosal effects in the small bowel with rectally administered preparations supporting a systemic postulate. NSAIDs provide analgesia by inhibiting cyclo-oxygenase (COX) 2. However, conventional NSAIDs also inhibit COX-1 which forms the cytoprotective prostaglandins (PGE, PGI). Another report proposed that enterocyte damage results from an uncoupling of oxidative phosphorylation in mucosal mitochondria with resulting depletion of adenosine triphosphate stores₃, leading to increased mucosal permeability and efflux of calcium ions. Injured enterocytes are also prevented from converting arachidonic acid into prostaglandins due to inhibited cyclooxygenase, making them susceptible to further damage by bile acids, enzymes and bacteria₅. Mucosal invasion by resident bacteria release chemotactic factors that recruit neutrophils into the submucosa with inflammatory sequelae. Progression of submucosal fibrotic lesions has been proposed to proceed from mucosal diaphragms resembling normal plicae circulares with fibrosis at their luminal margins to broad based stenoses that become dome-shaped and grossly fibrotic over time₁₂.

Colonic strictures have been described in children with cystic fibrosis taking methacrylic acid copolymer-coated pancreatic enzyme supplements₉, patients taking potassium supplementation₃ and also in those with secondary vasculitis in SLE and rheumatoid arthritis₁₀.

Treatment of colonic stricture includes endoscopic balloon dilatation with adjuvant prednisolone to promote healing and prevent restructuring₁₆. Resistant cases need segmental resection and anastomosis. Discontinuation of all NSAIDs is warranted, but may be problematic in chronic arthritis patients. Studies on a limited number of patients have demonstrated the efficacy of sulfasalazine₁₃, metronidazole₁₅ and misoprostol₁₄ in mitigating or preventing NSAID-induced enteropathy. It will be interesting to review the effect of selective COX-2 inhibitors on the incidence of colonic diaphragm disease with the passage of time.

CORRESPONDENCE TO

Dr Sivakumar Gopalswamy MS, DNB, MRCS, DMAS 101-D Kynance House, Royal Cornwall Hospital and Peninsula

Medical School Truro. United Kingdom TR1 3LZ Email: vgshiva@yahoo.com Work: +44-1872-250000 bleep 2302.

References

1. Pucius RJ, Charles AK, Adair HM, et al. Diaphragm-like strictures of the colon induced by non-steroidal anti-inflammatory drugs. *Br J Surg* 1993; 80: 395-6.
2. Sheers R, Williams WR. NSAIDs and gut damage. *Lancet* 1989; 2: 1154.
3. Bjarnason I, Hayllar J, MacPherson A, et al. Side effects of nonsteroidal anti-inflammatory drugs on the small and large intestine in humans. *Gastroenterology* 1993; 104: 1832-47.
4. Adrian W, Jeffrey W, Rupa M, et al. Diaphragm disease of the large bowel due to non-steroidal anti-inflammatory drugs. *New Zealand Med J* 2002; 115: 1156.
5. Eis MJ, Watkins BM, Philip A, Welling RE. Nonsteroidal-induced benign strictures of the colon. *Am J Gastroenterology* 2005; 93: 120-121.
6. Halter F, Weber B, Huber T, et al. Diaphragm disease of the ascending colon. Association with sustained-release diclofenac. *J Clin Gastroenterol* 1993; 16: 74-80.
7. Robinson MH, Wheatley T, Leach IH. Nonsteroidal anti-inflammatory drug induced colonic stricture. An unusual cause of large bowel obstruction and perforation. *Dig Dis Sci* 1995; 40: 315-9.
8. Whittle BJR. COX-1 and COX-2 products in the gut: therapeutic impact of COX-2 inhibitors. *Gut* 2000; 47: 320-5.
9. Littlewood J. Update on intestinal strictures. *J R Soc Med* 1999; 92(S37): 41-9.
10. Keating JP, King BR, Kenwright DN et al. Vasculitis-induced colonic stricture. *Dis Colon Rectum* 1998; 41: 1316-21.
11. Bjarnason I, Fehilly B, Smethurst P, et al. Importance of local versus systemic effects of nonsteroidal anti-inflammatory drugs in increasing small intestinal permeability in man. *Gut* 1991; 32: 275-7.
12. Lang J, Price AB, Levi AJ, et al. Diaphragm disease: Pathology of disease of the small intestine induced by nonsteroidal anti-inflammatory drugs. *J Clin Pathol* 1988; 41: 516-26.
13. Bjarnason I, Hopkinson N, Zanelli G, et al. The treatment of NSAID induced small intestinal inflammation. *Gut* 1988; 29: A1434.
14. Bjarnason I, Macpherson A. The changing gastrointestinal side effect profile of non-steroidal anti-inflammatory drugs. A new approach for the prevention of a new problem. *Scan J Gastroenterol* 1989; 163(suppl): 56-64.
15. Bjarnason I, Hayllar J, Smethurst P, et al. Metronidazole reduces intestinal inflammation and blood loss in non-steroidal anti-inflammatory drug induced enteropathy. *Gut* 1992; 33: 1204-8.
16. Weinstock L, Hammoud Z, Brandwin L. Nonsteroidal anti-inflammatory drug induced colonic stricture and ulceration treated with balloon dilatation and prednisolone. *Gastrointest Endosc* 1999; 50: 564-6.

Author Information

S. Gopalswamy

Department of Coloproctology, Royal Cornwall Hospital

PJ. Arumugam

Department of Coloproctology, Royal Cornwall Hospital

M. Feldman

Department of Coloproctology, Royal Cornwall Hospital