

Interdisciplinary Approach for Congenitally Missing Maxillary Lateral Incisors

G Aktas, S Canay, A Aktas, H El, I Bayramov

Citation

G Aktas, S Canay, A Aktas, H El, I Bayramov. *Interdisciplinary Approach for Congenitally Missing Maxillary Lateral Incisors*. The Internet Journal of Dental Science. 2009 Volume 8 Number 2.

Abstract

Several treatment options exist for the replacement of congenitally missing lateral incisors. These options include canine substitution, resin bonded fixed partial dentures, cantilevered fixed partial dentures, conventional fixed partial dentures and single tooth implants. Depending on which treatment option is chosen, specific criteria has to be addressed. Interdisciplinary treatment plays a vital role to achieve an excellent, esthetic result for a most predictable outcome. The aim of the study is to discuss the treatment plans of three patients with congenitally missing maxillary lateral incisors.

INTRODUCTION

The successful use of dental implants to replace missing teeth has been one of the most popular, exciting and evolving areas of clinical dentistry.¹ When implants are thought as a treatment option, treatment planning has become more complex for the dental practitioner, and an interdisciplinary team approach is recommended.^{2,3} Interdisciplinary approach would involve a preprosthetic and orthodontic treatment and following consultations with an oral surgeon and a restorative dentist, implant treatment was selected as a treatment modality.²

When planning for the placement of a single-tooth implant, there must be an adequate space between the crowns and roots. Both the quantity and quality of alveolar bone must be assessed before implant placement is considered.⁴ Where there is insufficient alveolar bone for implant placement, ridge augmentation may be necessary in addition to orthodontic repositioning of adjacent teeth.⁴ Adequate space for the implant position is also required between the adjacent roots.^{3,5} Creating adequate space between the roots must be specifically addressed since the first incisor and canine roots may be brought into closer proximity when the teeth are initially aligned orthodontically.⁶ If there is insufficient space for implant insertion, canines should be moved distally for creating space for lateral tooth region. This orthodontic movement makes bone development on canine region.^{4,5}

If implants are placed before growth is complete, the surrounding alveolar bone may continue to develop

vertically and adjacent teeth may continue to erupt. This creates a functional as well as an esthetic problem.⁶

An implant will preserve tooth structure and alveolar bone and provide esthetics and function. However, successful restorative treatment involving implants, depends on interdisciplinary treatment planning, especially if preprosthetic orthodontic tooth alignment is required.⁷

This clinical report describes an interdisciplinary approach for the treatment of three patients diagnosed with congenitally missing maxillary lateral incisors.

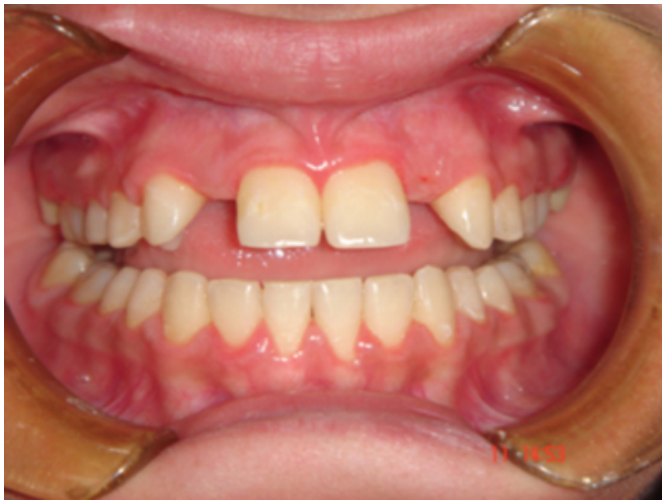CASE REPORTS

Three Female patients in age group of 19-23, with congenitally missing bilateral maxillary lateral incisors were referred to Department of Prosthodontic, Hacettepe University. After clinical and radiographic examination, patients were informed about the alternative treatments. Patients did not prefer to use removable prosthesis because of their age and the resultant poor esthetic. A three unit fixed partial denture option was not also accepted by the patients. They were not willing to undergo a preparatory treatment for their supporting teeth. Therefore an implant- supported fixed prosthesis was preferred for the treatment modality. As there was not sufficient space for the implant placement, the patients were referred to orthodontic clinic for creating space for the implants. (Fig 1) After orthodontic consultation, full appliance fixed orthodontic treatment was planned. The orthodontic treatment procedures include preparing space for lateral incisors, leveling and aligning the dental arches.

Before surgical procedures, wax set-ups were made on the models for the patients' opinion. After getting patients' approval, they were referred to oral and maxillofacial surgery clinic. Panoramic and CT radiographs were taken as a diagnostic guide.

Figure 1

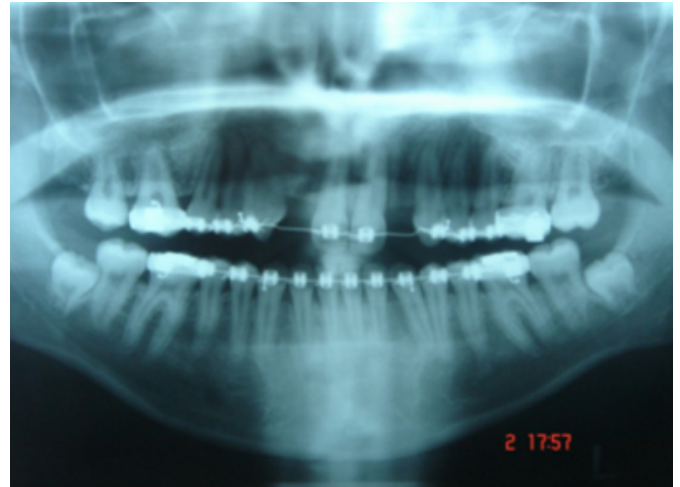
Figure 1: Sufficient space achieved after orthodontic treatment of case 1



In one case, CT radiographic examination showed that bone width in the edentulous region was insufficient. In this case the transfer of chin autograft was decided to apply. Full thickness flap was elevated on the anterior region of the mandible. Dimension of the graft was determined respecting at least 5 mm safety margin below the estimated apices of the frontal teeth in order to protect teeth from any neurosensory disturbances following osteotomy. Two piece of corticocancellous bone block was removed with the help of bone chisel. Blocks were adapted to the recipient graft site with the help of titanium screws. (Fig 2)

Figure 2

Figure 2: Panoramic radiograph of case 3 before prosthetic treatment



Under local anesthesia, a labial 2-sided full-thickness flap was reflected with a relieving incision on the mesial sides of the canines and intrasulcular incision extending to the left and right maxillary central incisors. The flap allowed inspection of the labial alveolar bone plate. It was observed that the bone formation was satisfactory for insertion of the selected implant dimensions Two Xive implants (13mm length, 3.0 mm diameter, Denstply–Friadent Co., Mannheim, Germany) were placed per one patient to the congenitally missing maxillary lateral area. After placing cover screws, primary closure was achieved with multiple 4-O polyglactin sutures (Vicryl; Ethicon Inc, Somerville, NJ).

Patients received the following postoperative medication: 1000 mg amoxicillin clavulanic acid 2 times daily, 275 mg naproxen sodium 2 times daily and chlorhexidine 0.2% mouth rinse 3 times daily. The sutures were removed after 7 days from the surgery.

After removal of the fixed appliances, Hawley retainers were prescribed to the patient for full time use to maintain spaces. During the fabrication stage of the Hawley retainers, special care was taken so that the acrylic plate of the retainer extending over to the implant region did not apply pressure on the already inserted implants.

Follow-up and maintenance examinations were provided at 2.5-3 months interval during osseointegration phase. At the end of this period, healing abutments were placed with minimal invasive surgery.

The provisional abutments were inserted and prefabricated provisional polycarbonate crowns (Polycarbonate Crown;

3M ESPE) were selected and relined with self curing acrylic resin (Dentalon; Kulzer, Wehrheim, Germany) to form a provisional restoration over the abutment and were cemented with temporary cement(Temp Bond; Kerr Corp, Orange, Calif). Soft tissues were conditioned by the provisional restorations to generate scalloped contours during four weeks. Then for definitive restorations Implant level impressions (Impregum Penta Soft; 3M ESPE, St. Paul, Minn) were made.

Then the abutments were selected on the models and glass-infiltrated aluminum oxide core material (In-Ceram alumina; Vita Zahnfabrik, Bad Sackingen, Germany) was chosen as a coping material. The In -ceram alumina cores were fabricated by a “slip-casting” technique, the process of preparing stable suspensions and fabricating structures by adding a solid layer on the surface of a porous mold.

The cores were evaluated on abutments for fit. Then they were veneered with VM 7 (Vita Zahnfabrik, Bad Säckingen, Germany). The full ceramic crowns were ultrasonically cleaned in distilled water for 10 minutes. The marginal fit and occlusion of the crowns were also evaluated intraorally and the crowns were then cemented on abutments with resin cement (Variolink II; Ivoclar Vivadent). The patients were pleased with the result and were motivated to maintain their oral hygiene (Fig 3-6). The patients were recalled for evaluating the clinical parameters-such as periodontal index and radiographical examinations at 1 week, 1 month, 6 months, 12 months, 24 months.

Figure 3

Figure 3: Panoramic radiograph of case 3

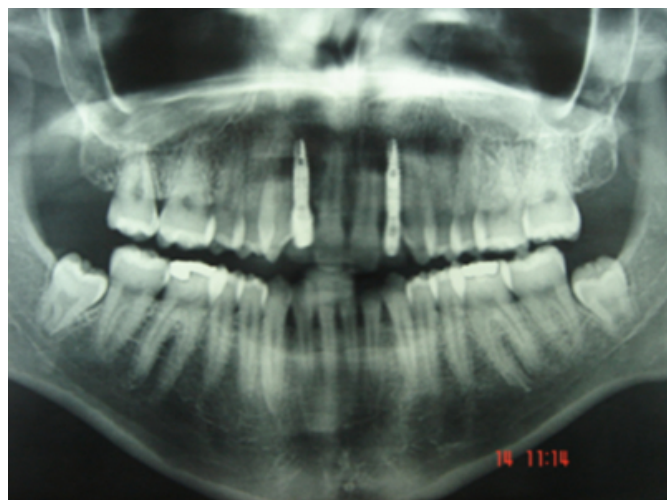


Figure 4

Figure 4: Intra oral view of case 3 in 1 year follow up

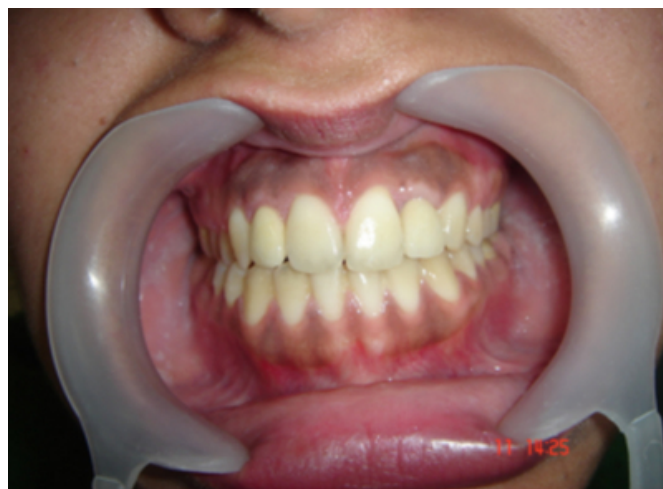

Figure 5

Figure 5: Post-op 1 year view of case 1

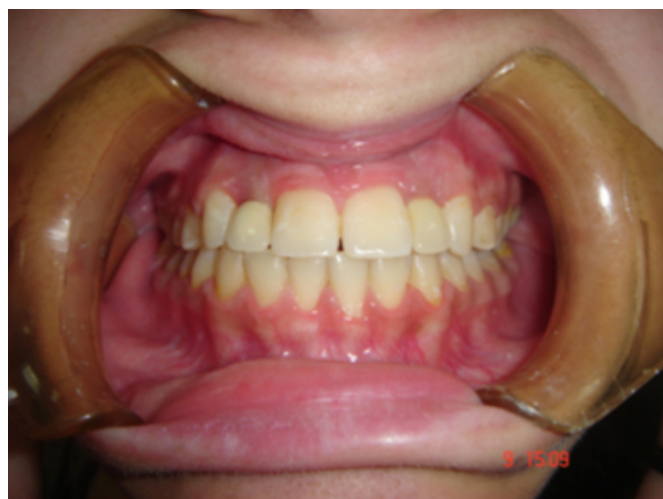
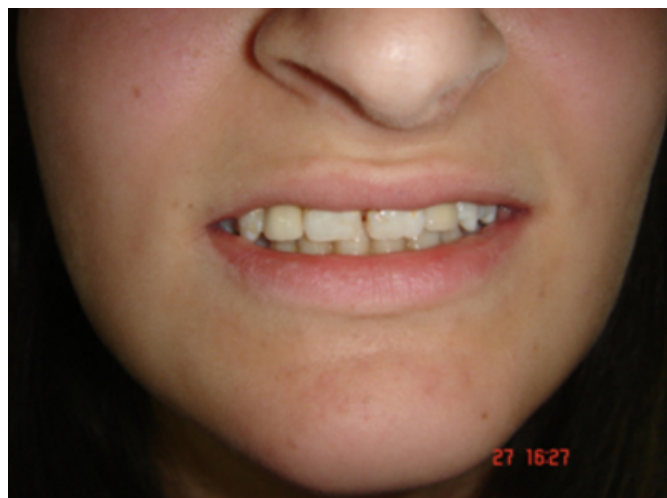
Figure 6

Figure 6: Extra oral view of case 2 in 1 year follow up



DISCUSSION

For the treatment of congenitally missing maxillary lateral incisor, esthetic approach is especially important as this is in esthetic zone, additional preprosthetic surgical procedures as bone or soft tissue regeneration often are necessary to improve the functional, biological and esthetic results of the prosthesis. Advantages and disadvantages of feasible treatments must be discussed and the patients' treatment expectance must be met.

Restoration of congenitally missing maxillary lateral incisors treatment could include removable partial dentures, tooth supported restorations, resin bonded fixed partial denture, canine substitution or a single tooth implant⁸. Space conditions and patient's age as well as on the patient's dental, skeletal and occlusal conditions. should be taken into consideration when selecting the proper treatment for each individual case. Wax seup study models are helpful involve the patient in the treatment plan.

Implant supported fixed partial prosthesis is the most conservative way of treatment because of protection of the

supported teeth, preventing of the alveolar bone resorption and esthetic outcomes.^{8,9} In this case report the patients were evaluated both radiographically and clinically at each appointment. All patients were placed in a recall system comprising periodic clinical, radiographic and hygiene controls. Neither bone nor soft tissue shrinkage was visible at both implant sites.

CONCLUSION

For a succesful outcome and patients satisfaction a coordinated orthodontic, prosthodontic, periodontic, and restorative treatments, with careful consideration of patient expectations and requests, are critical. For the replacement of congenitally missing upper lateral incisors implant-supported restorations should represent the treatment of choice.

References

1. Mantzikos T, Shamus I. Case report: Forced eruption and implant site development. *Angle Orthod* 1996; 68(2):179-86.
2. Schweizer CM, Schlegel AK, Rudzki-Janson I. Endosseous dental implants in orthodontic therapy. *Int Dent J* 1996; 46(2):61-8.
3. Richardson G., Russell KA. Congenitally missing maxillary lateral incisors and orthodontic treatment considerations for the single tooth implant. *J Can Dent Assoc* 2001; 67(1): 25-8.
4. Shroff B, Siegel SM, Feldman S, Siegel SC. Combined orthodontic and prosthetic therapy. Special considerations. *Dent Clin North Am* 1996; 40(4):911-43.
5. Kokich VG, Spear FM. Guidelines for managing the orthodontic-restorative patient. *Semin Orthod* 1997; 3(1):3-20.
6. Spear FM, Mathews DM, Kokich VG. Interdisciplinary management of single-tooth implants. *Semin Orthod* 1997; 3(1):45-72.
7. Grace R, Kathy A. R. Congenitally Missing Maxillary Lateral Incisors and Orthodontic Treatment Considerations for the Single-Tooth Implant *J Can Dent Assoc* 2001;67:25-8.
8. Rupp RP, Dillehay JK, Squire CF. Orthodontics, prosthodontics, and periodontics: a multidisciplinary approach. *Gen Dent* 1997; 45(3):286-9.
9. Strong SM. Replacement of congenitally missing lateral incisors with implant crowns. *Gen Dent* 2008; 56(6):516-9.

Author Information

Guliz Aktas, DDS, PhD

Department of Prosthodontics, Faculty of Dentistry, University of Hacettepe

Senay Canay, DDS PhD

Department of Prosthodontics, Faculty of Dentistry, University of Hacettepe

Alper Aktas, DDS, PhD

Department of Oral and Maxillofacial Surgery, Faculty of Dentistry, University of Hacettepe

Hakan El, DDS, PhD

Department of Orthodontics, Faculty of Dentistry, University of Hacettepe

Ilgar Bayramov, DDS, PhD