

# Disseminated Cryptococcosis: Case report

G Serrano Ocaña, J Ortiz Sablon, I Ochoa Tamayo

## Citation

G Serrano Ocaña, J Ortiz Sablon, I Ochoa Tamayo. *Disseminated Cryptococcosis: Case report*. The Internet Journal of Neurology. 2008 Volume 10 Number 2.

## Abstract

Life-threatening infections caused by the *Cryptococcus neoformans* have been increasing steadily over the past 20 years because of the onset of AIDS and the expanded use of immunosuppressive drugs. The incidence of Cryptococcal infection is higher among patients living with AIDS in Africa and Southeast Asia.

After the lungs and CNS infection, the next most commonly involved organs in disseminated cryptococcosis are the skin, prostate and medullary cavity of the bones. The diagnosis is established by the isolation of organism in culture, histopathology, or detection of its polysaccharide capsular antigen. The acute mortality rate for HIV infected patients is 10-25%; most deaths are attributable to cryptococcal meningitis.

## INTRODUCTION

*Cryptococcus neoformans* is an encapsulated basidiomycete yeast-like fungus with a predilection for the respiratory and nervous system of humans and animals with two varieties *Cryptococcus neoformans* var. *neoformans* (responsible for 98% of all cryptococcal infections in patients with AIDS) and *C. neoformans* var. *gattii*. [1,2]

Most commonly *Cryptococcus* initiates as a primary pulmonary infection, approximately 5-10% of HIV infected patients develop cryptococcal meningitis as an AIDS defining illness and in about 40%, it may be the initial manifestation. [3]

In the following pages the authors describe a patient presenting with Cryptococcal meningitis, severe thrombocytopenia and moderate anemia. She fully recovered after antifungal therapy (amphotericin B and fluconazole). Written consent was obtained from the patient before this article was conceived.

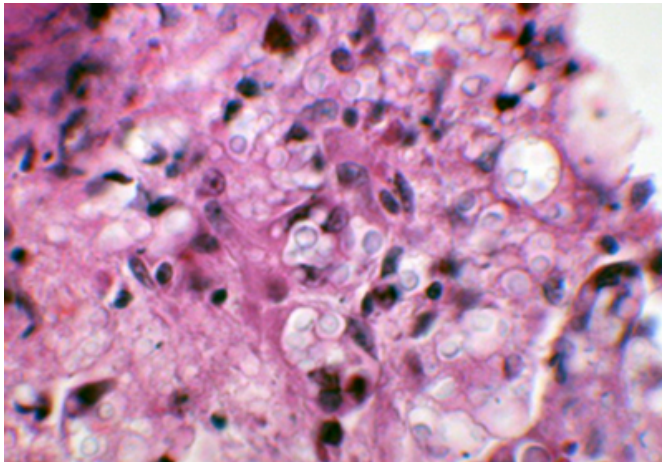
## CASE PRESENTATION

A 20-years-old african woman with previous history of pulmonary tuberculosis also HIV- positive, on HAART (3TC, D4T, efavirenz and bactrim), four days ago was seen presenting severe headache, fever and photophobia was admitted from 25 April to 10 May 2008. On physical examination: chronically ill looking, grossly underweight, weight 43.5 kg, height 165 cm, BMI 16, mucous pallor,

sores on the lower lip, temperature 37.8, blood pressure: 111/87 mm hg, pulse 118 beats / minute, Central Nervous System GCS 15/15, neck rigidity, Kernig's and Brudzinski's signs were positive. Laboratory findings: Na 134 mmol/l, K 3.5 mmol/l, Cl 96 mmol/l, urea 3.0 mmol/l creatinine 59 umol/l, full blood count Hb 9.4g/l, white blood cells 12.0 x 10<sup>9</sup>/l, platelet 8 x 10<sup>9</sup>/l, mean corpuscular volume 88.7 fl, CRP 70.7 mg/l, LDH 262 u/l, CD4 absolute count 36, CD4 of lymphocytes 4.54%, CSF protein 0.31 mmol/l, glucose 2.0 mmol/l, cells count Polymorphonuclear 0, Lymphocytes 2, ADA 1, indian ink positive, cryptococcal Ag positive, CSF culture: *Cryptococcus neoformans*, blood culture no growth after 48 hours incubation, further incubation positive (yeast) *Cryptococcus neoformans*, liver function test: bilirubin total 6 mmol/l, total protein 83 g/l, albumin 26 g/l, ALP 270 u/l, GGT 165 u/l, ALT 24 u/l, and AST 42u/l, tests for nutritional anemia: vitamin B12 level 573 pmol/l, folate level 20.2 nmo/l, serum iron 7.1umo/l, transferrin 0.8 g/l, transferrin saturation 35%, ferritin: 925 umol/l, bleeding screen: PTT control 31.3, PTT patient 59.1 secs, PT control 13.3, PT patient 17.1 secs, INR 1.38, TT control 16.7 secs, TT patient 16.3 secs and D-dimer: slightly positive (0.26 mg/l, parvovirus B19 serology: IgM negative, IgG negative, Bone Marrow Aspiration: multiple granulomas were seen; they contain several fungal bodies, keeping with disseminated fungal infection.

**Figure 1**

Figure 1: Hematoxylin and Eosin stain of a Bone marrow showing multiple granulomas and fungal bodies in a patient with disseminated Cryptococcosis. Port Elizabeth May 2008



She received treatment with amphotericin B 35 mgs daily intravenously for two weeks, then continued with fluconazole 400 mgs daily for eight weeks, also received prophylactic treatment with bactrim, and ARVs (3TC, D4T and efavirenz). Latest FBC was taken on 16-07-2008 showed a remarkable improvement WCC  $5 \times 10^9/l$ , Hb 10.6 g/l and platelet  $225 \times 10^9/l$  and MCV 93 fl.

**DISCUSSION**

Although the overall incidence of cryptococcosis is unknown, it is higher among patients with AIDS in Africa and Southeast Asia than in the United States, whereas it appears less frequently in Europe. [3] Prior to the discovery of amphotericin B in 1955, 80% of patients with CNS involvement died within 2 years of diagnosis.

In the developed world, the introduction of potent antiretroviral therapies resulted in a decrease in the incidence of opportunistic infections associated with AIDS. In those with HIV infection, cryptococcal infection occurs in the advanced stages of the disease when the CD4+ count is usually less than 50-200 cells/ $\mu L$ . [1] Unfortunately in our setting not all HIV patients are receiving ARV's or when they came there disease is very advanced often with very low CD4 cell count, making them very susceptible to develop this type of infection.

Bone marrow cryptococcosis is a classical, albeit relatively infrequent, presentation in patients with acquired immunodeficiency syndrome (AIDS) [4,5]

The laboratory diagnosis of cryptococcosis is established by the isolation of organism in culture, histopathology, or

detection of its polysaccharide capsular antigen. [3]

The organism grows in blood and chocolate agar within 3-5 days. Analysis of cerebrospinal fluid (CSF) usually reveals a poor white blood cell (WBC) count, inflammatory response, with a normal or low-CSF glucose levels, and a positive cryptococcal antigen test. The India ink test is more specific and helps in demonstrating the fungus. The level of antigen titer corresponds to the severity of disease.

In tissue specimens, *C. neoformans* is difficult to observe with routine hematoxylin and eosin stains. Methenamine silver or periodic acid-Schiff stains clearly demarcate *C. neoformans* and to permit recognition of its characteristic shape and size.

{image:2}

{image:3}

Imaging techniques like computed tomography (CT) or magnetic resonance imaging (MRI) of the head are used for detecting complications such as, hydrocephalus or mass lesions, where surgery may be indicated. [6]

The acute mortality rate for patients with HIV WHO Stage IV is 10-25%. Most deaths are attributable to cryptococcal meningitis and occur within two weeks after diagnosis, and many may be related to increased intracranial pressure.[7] In cohorts of HIV-infected patients from sub-Saharan Africa, cryptococcosis has accounted for 13–44% of all deaths.

Flucytosine (5FC) in combination with amphotericin B (AMB) is standard therapy for cryptococcal meningitis. [7,8,9,10]

Severe attacks of cryptococcal meningitis are treated with liposomal amphotericin (Abelcet, AmBisome, Amphocil) induction therapy (0.6 - 1.0 mg/kg per day). Liposomal amphotericin causes far fewer adverse effects than the standard form of the drug and is more effective than standard amphotericin in AIDS patients. [1,6,7,8]

Fluconazole has been found to be particularly effective due to its high bioavailability, excellent CSF penetration and long half-life. Therefore, it is regarded as the drug of choice for prophylactic therapy. The mortality of disseminated cryptococcosis is 70-80% in untreated patients compared with those treated with systemic antifungal agents. [11]

Raised intracranial pressure: daily serial lumbar punctures with withdrawal of large volumes of CSF to achieve a

closing pressure of <25 cm H<sub>2</sub>O or 50% of initial opening pressure. [1,7]

## **ACKNOWLEDGEMENT.**

To Dr Nel and Dr. Littleton from the Department of hematology Provincial Hospital Port Elizabeth for their continuous support and valuable help and to Dr. Diana Oelofse from the National Health Laboratory Services Port Elizabeth for her kindness and continuous support.

## **References**

1. Satishchandra P, Mathew T, Gadre G, Nagarathna S, Chandramukhi A, Mahadevan A, Shankar SK. Cryptococcal meningitis: Clinical, diagnostic and therapeutic overviews. *Neurol India* [serial online] 2007 [cited 2008 Aug 21]; 55:226-232. Available from: <http://www.neurologyindia.com/text.asp?2007/55/3/226/35683>
2. Diaz Perez JA, Garcia Vera JA, Mantilla Hernandez JC, Pradilla Ardila G. Criptococoma del sistema nervioso central en un paciente no inmunoafectado. [Serial online] *Rev Neurol* 2008; 46 (2): 97-101. Available from: <http://www.neurologia.com/pdf/Web/4602/z020097.pdf> [Consulted 11 Julio 2008]
3. Shankar SK, Mahadevan A, Sundaram C, Sarkar C, Chacko G, Lanjewar DN, Santosh V, Yasha TC, Radhakrishnan VV. Pathobiology of fungal infections of the central nervous system with special reference to the Indian scenario. *Neurol India* [serial online] 2007 [cited 2008 Aug 21]; 55:198-215. Available from: <http://www.neurologyindia.com/text.asp?2007/55/3/198/35680>
4. Kagialis-Girard S; Gerland LM; Dumontet C; Treille-Ritouet D.. Unusual Organisms in the Bone Marrow of a Patient With Systemic Sarcoidosis. *Lab Med.* [serial online] 2005 [cited 2008 Aug 20]; 6(12): 762-763. Available from: <http://www.medscape.com/viewarticle/517737>
5. Srinivas U, Kar R, Saxena R, Prasad PH. Cryptococcal neoformans profiles in peripheral blood neutrophils: An unusual presentation. *Indian J Pathol Microbiol* [serial online] 2008 [cited 2008 Aug 31]; 51:296-7. Available from: <http://www.ijpmonline.org/text.asp?2008/51/2/296/41707>
6. Subramanian S, Mathai D. Clinical manifestations and management of cryptococcal infection. *J Postgrad Med* [serial online] 2005 [cited 2008 Aug 21]; 51:21-6. Available from: <http://www.jpgmonline.com/text.asp?2005/51/5/21/19810>
7. Saag MS, Graybill RJ, Larsen RA, Pappas PG, Perfect JR, Powderly WG et al. Practice guidelines for the management of Cryptococcal disease. *Clin Infect Dis* 2000; 30: 710-718 [Serial online] available from: <http://www.mycology.adelaide.edu.au/downloads/cryptococcosis.pdf>
8. Brouwer AE, Johnson E, Rajanu Wong A, Harrison T, Day N, van Kan HJ, et al. Oral versus Intravenous Flucytosine in Patients with Human Immunodeficiency Virus-Associated Cryptococcal Meningitis. *Anticarb. Agent Chemother* [Serial online] >2007[cited Aug 20 2008]; 51(3): 1038-1042 available from: <http://aac.asm.org/cgi/content/full/51/3/1038>
9. Beers MH, Porter RS, Jones TV, Kaplan JL, Berkwits M. *Fungi. The Merck Manual of Diagnosis and Therapy.* 18 ed NJ: Merck Research Laboratories, 2006: 1523-1533
10. Qadir F, Manzoor K, Ahmed E. Disseminated cryptococcosis in a patient with Nephrotic syndrome. *Indian J Med Microbiol* [serial online] 2006 [cited 2008 Aug 31]; 24:141-3. Available from: <http://www.ijmm.org/text.asp?2006/24/2/141/25209>
11. Dharmshale SN, Patil SA, Gohil A, Chowdhary A, Oberoi C. Disseminated cryptococcosis with extensive cutaneous involvement in AIDS. *Indian J Med Microbiol* [serial online] 2006 [cited 2008 Aug 31]; 24:228-30. Available from: <http://www.ijmm.org/text.asp?2006/24/3/228/27002>

**Author Information**

**G. Serrano Ocaña**

Department of Internal Medicine, “Dora Nginza” Hospital

**JC Ortiz Sablon**

Department of Internal Medicine, “Dora Nginza” Hospital

**I Ochoa Tamayo**

Department of Internal Medicine, “Dora Nginza” Hospital