

Deformed Spinal Needle

R Verma, R Dutta, S Dube

Citation

R Verma, R Dutta, S Dube. *Deformed Spinal Needle*. The Internet Journal of Anesthesiology. 2007 Volume 16 Number 2.

Abstract

Spinal anesthesia is a simple technique if properly performed and managed well it is one of the safe techniques as well. Due to its smaller caliber the spinal needle is always prone to be deformed if not used carefully. The fine spinal needle tip can undergo deformation during subarachnoid block due to various reasons^{2, 3, 4}. We have reported a unique cause of the deformation of the spinal needle tip during subarachnoid block.

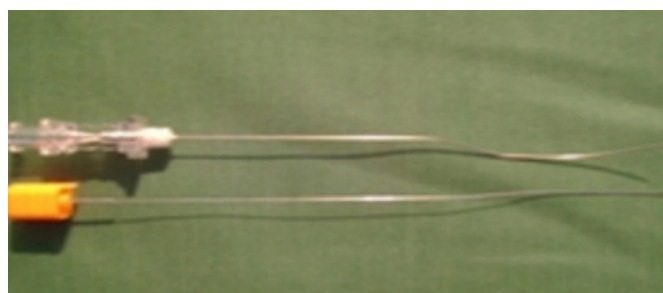
Spinal anesthesia is a simple technique with little sophistication and, has proved to be extremely safe when managed well. Most common complication in literature following sub-arachnoid blockade is postdural puncture headache though there has been a continuous decline in the incidence with the increased use of small gauge needles¹. These needles have been found to undergo deformation and fracture in the past^{2, 3, 4}. Here we have reported a case where such a small gauge needle underwent deformation but, because of a slightly different reason.

An ASA grade I, 76kg, 152cm, 40year old woman was scheduled for transabdominal hysterectomy. After written and informed consent patient was placed in lateral decubitus position. Under all aseptic precaution and after local infiltration of L2-3 space with 2% lignocaine hydrochloride a 25 gauge Quinke's needle was used to carry out sub-arachnoid block through midline approach. As the needle punctured the interspinous ligament the assistant (who helped the patient to maintain a "knee to forehead position") with an intention to provide facilitation to apply the block provided an extra force. That extra force leads to a sudden marked deformation in the shape of needle (fig.1). Immediately, the needle was withdrawn and any broken segment was ruled out.

While carrying out a subarachnoid block, positioning frequently remains a poorly managed part of the procedure as the assistant often does not understand the rationale of

positioning the patient⁵. Bone impact and needle redirection are the other well known causes of gross deformations of needle tip. Therefore, we should always explain the procedure not only to the patient but also to the assistant who play an important role in helping the patient to maintain position and should avoid applying force once the spinal needle is in place.

Figure 1



References

1. Cruvinel MCG, Andrade AVC. Needle fracture during spinal puncture. *Revista Brasileira de Anestesiologia* 2004; 54: 6: 794-798.
2. Chesney MA, Brey SJ. Severe deformation of a small gauge spinal needle. *Anesth. Analg.* 1993; 77: 401-402.
3. Thomsen AF, Nilsson CG. Broken Small-Gauge Spinal Needle. *Anesth. Analg.* 1997; 85: 230-31.
4. Gentili ME, Nicol JB, Enel D, Marret E. Recovery of a Broken Spinal Needle. *Regional Anesthesia and Pain Medicine.* 2006; 31(2):186.
5. Brown LD. Spinal, Epidural, and Caudal Anesthesia. In Miller RD (Ed.) *Anesthesia*, 6th ed. New York: Churchill livingstone Inc.; 2005: 1662.

Author Information

Ravi Kumar Verma, MD

Reader, Department of Anaesthesiology, Institute of Medical Sciences, Banaras Hindu University

Rahul Dutta, MBBS

Junior Resident, Department of Anaesthesiology, Institute of Medical Sciences, Banaras Hindu University

Surya Kumar Dube, MBBS

Junior Resident, Department of Anaesthesiology, Institute of Medical Sciences, Banaras Hindu University