

# Iatrogenic Oesophageal Perforation In A Newborn

S Bhojani, P Desai, H Mactier

## Citation

S Bhojani, P Desai, H Mactier. *Iatrogenic Oesophageal Perforation In A Newborn*. The Internet Journal of Pediatrics and Neonatology. 2007 Volume 8 Number 2.

## Abstract

Endotracheal intubations and nasogastric tube (NG) insertions are common procedures in any neonatal intensive care unit. But complications secondary to these procedures are not commonly seen. Iatrogenic oesophageal perforation is a rare but known complication of these procedures.

We would like to present two cases of preterm babies with iatrogenic oesophageal perforation. Both the babies had NG tube insertion and endotracheal intubation. Baby A had semi-elective and Baby B had an emergency intubation. Both babies were asymptomatic and were diagnosed incidentally on subsequent X rays.

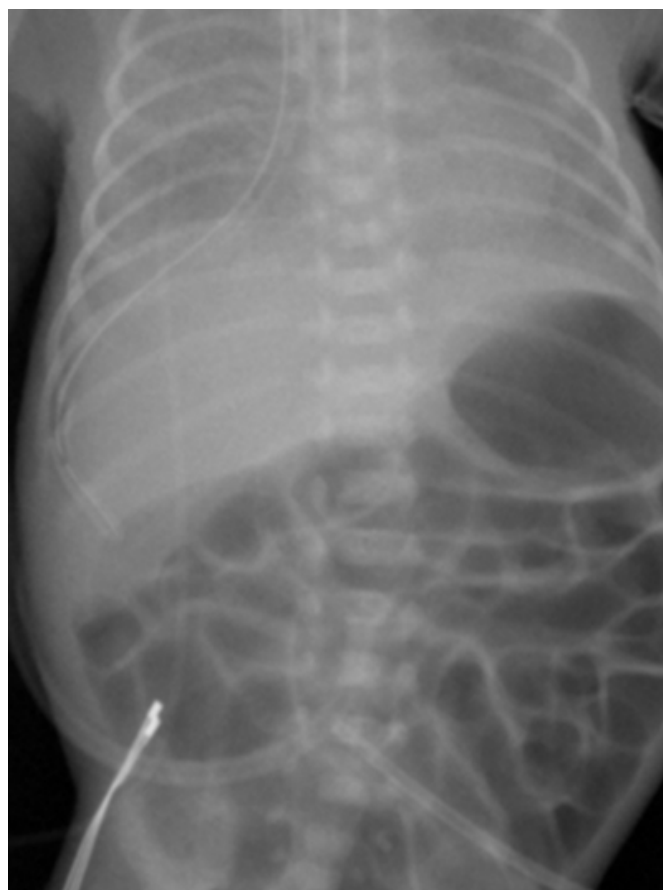
Baby A, born at 27 weeks gestation, was intubated at birth in view of prematurity and poor respiratory effort. The initial chest X-ray showed endotracheal tube in good position at T2 level and the NG tube in the stomach. Baby had two doses of surfactant and was extubated to CPAP at 24 hours of age. On day 5 of life due to clinical deterioration and increased oxygen requirement a decision was made to re-ventilate the baby. Semi-elective reintubation, done using intubation drugs, proved difficult and required multiple attempts. No evidence of any trauma or blood was noticed during the procedure. The subsequent X-ray showed the NG on the right side of the chest and a diagnosis of oesophageal perforation was made. There were no symptoms related to the perforation. Baby was managed conservatively. He was already on antibiotics before this episode in view of presumed sepsis which were continued.. Feeds were built up slowly and full feeds were established by day 18.

The baby further went on to have chronic lung disease, but no complications secondary to oesophageal perforation.

Figure 1

## Figure 1

Figure 1: X ray chest and abdomen showing the nasogastric tube on the right side

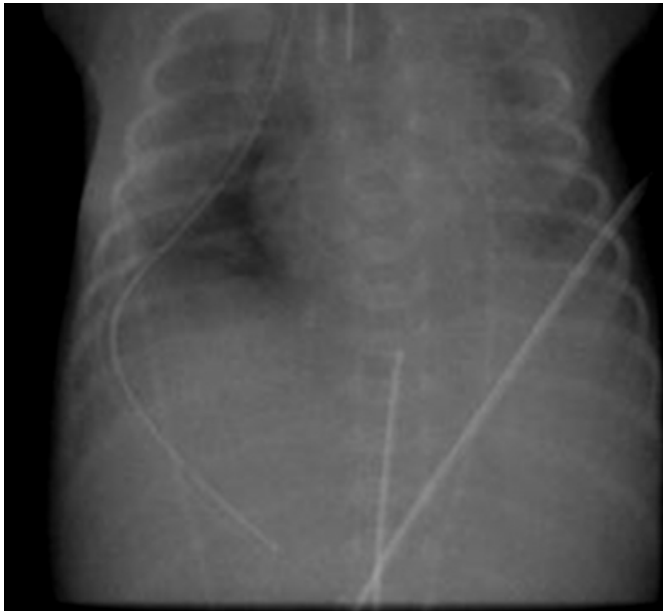

Baby B, born at 26 weeks gestation, had a difficult intubation at birth. A dose of surfactant was given soon after intubation. NG tube was inserted without any difficulty.

Subsequent chest X-ray showed the NG tube deviating to the right side of chest with a small associated pneumothorax. Figure 2 . A second NG tube passed followed the same route. At this stage a diagnosis of situs inversus was considered as the NG tube was on the right side and there was no stomach bubble seen. Since the antenatal scans were normal, a differential diagnosis of oesophageal perforation was kept in mind. So after leaving the previous ectopic NG tube in situ, we successfully passed a second NG tube to the stomach. Figure 3. This confirmed the diagnosis of oesophageal perforation. There were no obvious signs or symptoms of perforation noticed.

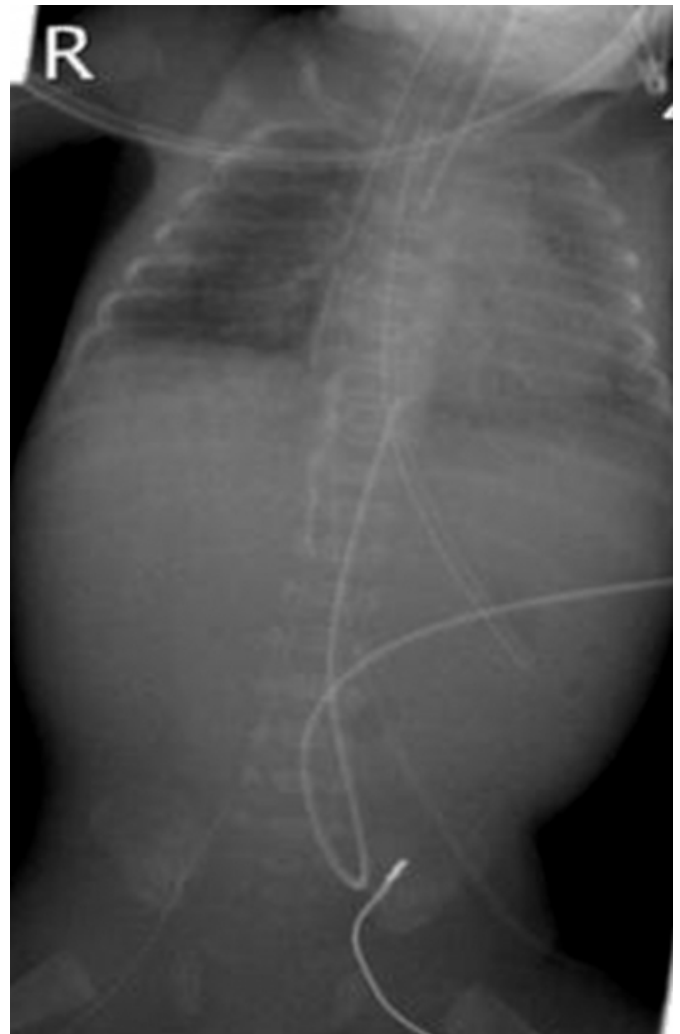**Figure 2**

Figure 2: X ray chest showing the nasogastric tube on the right side with a small associated pneumothorax.



**Figure 3**

Figure 3: X ray chest and abdomen with 2 nasogastric tubes, first in the right side of the chest and the second in the stomach



No trauma was immediately evident during any of the procedures in either of the babies. Both of these cases of oesophageal perforation were asymptomatic, diagnosed incidentally, treated conservatively and made complete recoveries.

### **DISCUSSION**

Iatrogenic oesophageal perforation occurs mainly in preterm and low birth weight babies<sup>1</sup>, secondary to difficult intubation and forceful attempts to pass NG tubes and suction catheters<sup>2</sup>. It is usually seen in the cervical region of the oesophagus, most commonly involving the pyriform sinus<sup>3</sup>. Babies may present with respiratory distress, blood stained secretions, cyanosis, feeding difficulties or vomiting which may result in delay in establishing full feeds. Most babies can be treated conservatively although surgical

intervention may be required in severe cases <sup>4, 5</sup>. There is no difference in the reported rate of survival when treated medically versus surgically <sup>6</sup>. There is no apparent advantage to routine surgical exploration though complications such as mediastinitis and mediastinal mass formation may require surgical intervention.

Preventive measures such as adequate training in intubation, use of more experienced staff for intubating extremely preterm infants, extra care during suctioning, placement of naso/orogastric tubes and high index of suspicion are required. There have been many mechanisms for the esophageal perforation proposed in the literature. The two most common causes are related to placement of endotracheal and nasogastric tubes. Other causes include laryngoscope blades, suction catheter and sometimes spontaneous rupture.

In conclusion, oesophageal perforation is a rare complication of the modern neonatal intensive care setting which can occur even in most experienced hands. A high index of suspicion in infants with sudden deterioration of respiratory status following procedures involving pharyngeal region is

essential for a timely diagnosis, which can be confirmed by radiological investigations. Conservative management in an otherwise uncomplicated case can result in complete recovery in most affected neonates. These cases highlight the fact that oesophageal perforation can occur secondary to procedures like tracheal intubation and NG tube insertion in an otherwise asymptomatic baby.

### **References**

1. Al-Khawahur HA and Al-Salem AH. Iatrogenic perforation of the esophagus. *Saudi Med J*. 2002;23(6):732-4.
2. Stapp J, Stewart DL, Eberly S. Atypical iatrogenic perforation of the distal esophagus in an ELBW neonate. *Clin Pediatr (Phila)*. 2001 Nov;40(11):637-8
3. Nagaraj HS, Mullen P, Groff DB, et al. Iatrogenic perforation of the esophagus in premature infants. *Surgery*. 1979; 86:583-589.
4. Krasna IH, Rosenfeld D, Benjamin BG, Klein G, Hiatt M, Hegyi T. Esophageal perforation in the neonate: an emerging problem in the newborn nursery. *J Pediatr Surg*. 1981 Dec;16(6):989-93.
5. Mollitt DL, Schullinger JN, Santulli TV. Selective management of iatrogenic esophageal perforation in the newborn. *J Pediatr Surg*. 1981 Dec;16(6):989-93.
6. Johnson DE, Foker J, Munson DP, Nelson A, Athinarayanan P, Thompson TR. Management of esophageal and pharyngeal perforation in the newborn infant. *Pediatrics* 1982; 70: 592-6

**Author Information**

**Sheetal Bhojani, MRCPCH**

Neonatal Unit, Princess Royal Maternity Hospital

**Prakash Desai, MRCPCH**

Neonatal Unit, Princess Royal Maternity Hospital

**Helen Mactier**

MD, MRCPCH, Neonatal Unit, Princess Royal Maternity Hospital