

Splenic Pseudocyst With Hypersplenism-Therapeutic Implications Of A Rare Association

S Chandra, N Maroju, V Bhuvaneshwari, K Dharanipragada

Citation

S Chandra, N Maroju, V Bhuvaneshwari, K Dharanipragada. *Splenic Pseudocyst With Hypersplenism-Therapeutic Implications Of A Rare Association*. The Internet Journal of Surgery. 2006 Volume 9 Number 2.

Abstract

Splenic conservation is the standard option in the management of pseudocyst of the spleen to prevent post splenectomy complications. They are usually treated by splenic decapsulation or partial splenectomy. Hypersplenism associated with pseudocyst is very rare and only three cases have been reported in world literature. Presence of hypersplenism necessitates splenectomy. Massive enlargement of spleen predisposes them to trauma and development of pseudocyst. In Countries with a high incidence of malaria and tropical splenomegaly, hypersplenism needs to be excluded, while considering surgical options in the management of pseudocyst of spleen. We report a rare case of a splenic pseudocyst associated with hypersplenism successfully managed by splenectomy.

INTRODUCTION

The management of splenic cysts has evolved over time. Splenic conservation techniques have replaced splenectomy which was practiced for a long time. Percutaneous sclerotherapy of a symptomatic post-traumatic splenic pseudocyst may be an alternative to surgical treatment. Common splenic conservation techniques used in the management of splenic cysts are deroofting of the cyst and partial splenectomy. Laparoscopic procedures for management of splenic disorders are a significant development. Large cysts involving the splenic hilum and ruptured pseudocyst require splenectomy. [1]

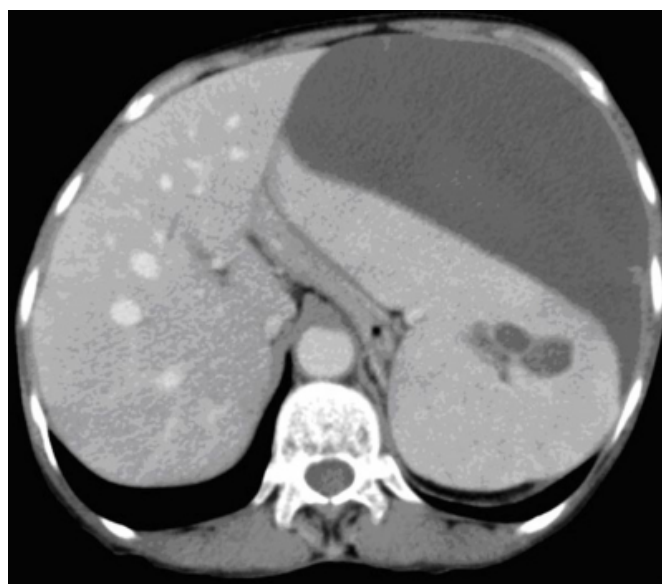
Hypersplenism associated with pseudocyst is very rare and there are only three cases reported in literature.[2]. Splenic conservation is not possible in the presence of hypersplenism and this represents another indication for splenectomy in the management of pseudocysts. We present a case of pseudocyst with hypersplenism managed successfully by splenectomy

CASE HISTORY

A 55 year old lady presented with pain and awareness of a lump in left hypochondrium. There was no history of trauma. Examination revealed anemia and a soft tender lump in left upper abdomen. Ultrasound and CT scan revealed a 12cm by 5 cm cyst on the superiolateral surface of spleen (fig.1).

Figure 1

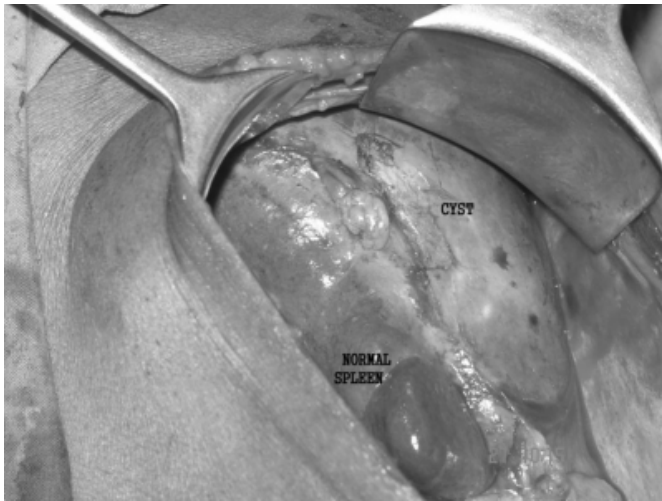
Figure 1: CT scan image of the splenic cyst



Blood examination revealed anemia, a white cell count of 2,500/mm³ and a platelet count of 108,000/mm³. Peripheral smear showed pancytopenia and a reticulocyte count of 2.5%. Bone marrow was hypercellular with erythroid hyperplasia. Malarial serology was negative and upper G.I.endoscopy did not show any evidence of portal hypertension. Patient underwent splenectomy and recovered well from surgery (fig.2). Pathologic diagnosis was pseudocyst of spleen with no epithelial lining and containing organized haematoma.

Figure 2

Figure 2: operative photograph



DISCUSSION

Pseudocyst or false cyst lacks any epithelial lining in contrast to a true cyst. Many cases of splenic cysts are diagnosed now due to increased use of imaging modalities, USG and CT scan.

Pseudocyst is usually post traumatic and results from splenic haematoma managed conservatively. According to Black, in a haemodynamically stable patient, subcapsular haematoma is neither a predictor for delayed splenic rupture nor by itself an indication for operative management'. [3] A capsule of fibrous tissue develops around the resolved subcapsular or intraparenchymal haematoma, which ultimately liquefies to form a pseudocyst. [4]. If splenic haematomas are treated conservatively, follow-up scans are recommended until the haematoma has fully resolved [5, 6] Ruptured pseudocyst, necessitating emergency splenectomy 34 years after the original injury has been reported [7]. In the present case the cyst is probably the result of unrecognized trauma.

Post traumatic pseudocysts present with abdominal lump and pain. Infection and rupture are the potential complications. There are no definite guidelines for the management of pseudocyst due to the rarity of this clinical condition.

The first successful splenectomy recorded for a splenic cyst was by Pean in 1867. Edwin Beer (1928), reviewing progress in splenic surgery, voiced his opinion that nothing less than total removal of the spleen was acceptable in cases warranting splenectomy, whatever the underlying cause.

Conservative treatment of splenic cyst in an asymptomatic individual with spontaneous resolution has been reported [8].

Percutaneous sclerotherapy of a symptomatic post-traumatic splenic pseudocyst may be an alternative to surgical treatment [9]

According to Sierra et al, laparoscopic marsupialization is safe and effective for giant nonparasitic splenic cysts and should be considered the treatment of choice [10]. laparoscopic spleen-saving procedures are recommended by Hansen et al for the management of splenic pseudocysts [11]. Spleen preserving techniques should be attempted in every case of splenic nonparasitic cyst and both laparoscopic unroofing of cyst wall and open partial splenectomy are effective tools in the management of splenic non-parasitic cysts including post traumatic cysts [12] .

Percutaneous drainage and laparoscopic fenestration have an unacceptably high rate of failure. Partial or complete splenectomy should be considered for young and otherwise healthy patients who have large symptomatic splenic pseudocysts [13].

The work of Campos Christo in 1962 about the segmental anatomy of the spleen helped surgeons perform a partial splenectomy, thereby avoiding complications of postsplenectomy infection. Balzan et al reported a case of a 13 year old girl with a splenic cyst managed by partial splenectomy and emphasized the need to preserve splenic tissue [14].

Some cases of splenic cysts are still treated by splenectomy [15]. A case of a large infected pseudocyst involving the splenic hilum necessitating splenectomy in an 11 year old boy has been reported. [1]. Infected and ruptured pseudocysts also require splenectomy.

Alteration of normal splenic function in a pseudocyst has not been recognized till 1971 [16]. Only two patients with splenic pseudocyst and hypersplenism were reported in the world literature over the next decade. In 1981 Janin et al reported another case of splenic cyst associated with hypersplenism. Increased destruction of red blood cells and pooling of blood in the enlarged spleen are considered responsible for hypersplenism associated with pseudocyst of spleen [2]. Though serological tests for malaria were negative in our patient, trauma to an enlarged spleen due to malaria with hypersplenism can also explain this association in endemic areas like India. To our knowledge ours is only the fourth such case of hypersplenism associated with pseudocyst of spleen in literature.

Pseudocyst of spleen associated with hypersplenism was last reported two and a half decades earlier when splenectomy was the standard treatment for majority of splenic disorders. Due to current practice of conservative treatment splenic injuries and with increased use of imaging modalities, more cases of splenic pseudocyst are likely to be detected. Spleen preserving techniques are commonly practiced now in the management of pseudocyst. We recommend assessment of splenic function in patients with pseudocysts before such techniques are undertaken, as presence of hypersplenism warrants splenectomy.

CORRESPONDENCE TO

Dr.S.Sarath Chandra.M.S. Professor, Dept. of Surgery,
Jawaharlal Institute of Postgraduate Medical Education and
Research, Pondicherry, India E-mail:
sarathsishta@hotmail.com

References

1. Kalinova K Giant pseudocyst of the spleen: A case report and review of the literature. *J Indian Assoc Pediatr Surg* 2005;10(3):176-178
2. Janin Y, Strauss R, Katz S, Platt N, Katzka I, Wise L. Splenic pseudocyst associated with hypersplenism. *Am J Gastroenterol*. 1981 Apr; 75(4):289-93]
3. Black JJ, Sinow RM, Wilson SE, William RA. Subcapsular haematomas -a predictor of delayed splenic rupture. *Am Surg* 1992; 58:732-5
4. Zinner MJ, Schwartz SI, Harold E. Maingot's Abdominal Operations, 10th edn. New York: Appleton & Lange, 1997:2040
5. Sbih W. Radionuclide scintigraphy: A diagnostic aid in delayed traumatic splenic rupture: case report. *J Nucl Med* 1975; 16:912-14
6. Sziklas JJ, Spencer RP, Rosenberg RJ. Delayed splenic rupture: a suggestion for "predictive monitoring". *J Nucl Med* 1985; 26: 609-11
7. P S Sinha, T A M Stoker, N O Aston. Traumatic pseudocyst of the spleen. *J R Soc Med* 1999; 92:450-452
8. G. L. Lamont D. C. S. Gough .Conservative management of a splenic cyst. *Pediatr Surg Int*. 1993; 8(6):511-512
9. Markus Völk, Gerhard Rogler, Michael Strotzer, Guntram Lock, Christoph Manke, Stefan Feuerbach Post-Traumatic Pseudocyst of the Spleen: Sclerotherapy with Ethanol. *Cardiovasc Intervent Radiol*. 1999; 22(3):246-8.
10. Sierra R, Brunner WC, Murphy JT, Dunne JB, Scott DJ. Laparoscopic marsupialization of a giant posttraumatic splenic cyst. *JSLs*. 2004 Oct-Dec; 8(4):384-8
11. Hansen MB, Moller AC. Splenic cysts. *Surg Laparosc Endosc Percutan Tech*. 2004 Dec; 14(6):316-22
12. Duri Gianom, Alessandro Wildisen, Thomas Hotz, Federico Goti, Marco Decurtins. Open and Laparoscopic Treatment of Nonparasitic Splenic Cysts. *Dig Surg* 2003; 20:74-78
13. Wu HM, Kortbeek JB Management of splenic pseudocysts following trauma: a retrospective case series *Am J Surg*. 2006; 191(5):631-4.
14. Balzan SM, Riedner CE, Santos LM, Pazzinatto MC, Fontes PR Posttraumatic splenic cysts and partial splenectomy: report of a case. *Surg Today*. 2001; 31(3):262-5
15. Labruzzo C, Haritopoulos KN, El Tayar AR, Hakim NS. Posttraumatic cyst of the spleen: A case report and review of the literature. *Int Surg*. 2002; 87(3):152-6.
16. Charles E. Davis, jr., Juan M. Montero, Charles N. Vanhorn. Large splenic cysts. *Ann. Surg*. 1971; 173(5): 686-692

Author Information

S. Sarath Chandra, M.S.

Professor, Department of Surgery, Jawaharlal Institute of Postgraduate Medical Education and Research

NandaKishore Maroju, M.S.

Assistant Professor, Department of Surgery, Jawaharlal Institute of Postgraduate Medical Education and Research

V. Bhuvaneswari, M.D.

Professor, Department of Radiodiagnosis, Jawaharlal Institute of Postgraduate Medical Education and Research

Kadambari Dharanipragada, M.D.

Associate Professor, Department of Surgery, Jawaharlal Institute of Postgraduate Medical Education and Research