

Primitive Neuroectodermal Tumour of the kidney in a young female: a case report

G Gupta, R Singh, P Kumar, D Kotasthane

Citation

G Gupta, R Singh, P Kumar, D Kotasthane. *Primitive Neuroectodermal Tumour of the kidney in a young female: a case report*. The Internet Journal of Pathology. 2009 Volume 10 Number 2.

Abstract

We present a case of a PNET of the kidney in a 20-year-old female. This is an extremely rare presentation. Primitive Neuroectodermal Tumours (PNET) occurs preferentially in the soft-tissues of the paravertebral region and chest wall, less frequently in extremities, with a male predominance. Few cases have been reported in literature with a variable, non-specific presentation and an aggressive behaviour. In our case, a radical nephrectomy with lymphadenectomy was performed. Haematoxylin and eosin staining showed the tumour composed of cohesive sheets of small, uniform, primitive cells separated by fibrous bands. Homer-Wright pseudorosettes were present and perivascular rosetting was noted. The cytoplasm showed PAS positivity. The immunohistochemical evaluation revealed a diffuse CD99 positivity in the cytoplasm of the neoplastic cells. Neuron-Specific Enolase (NSE), synaptophysin and vimentin were positive. The clinical presentation and the macroscopic aspect, together with the histological pattern, the cytological characteristics and cellular immunophenotype addressed the diagnosis towards primary PNET of the kidney. Since the differentiation of small round cell tumours may be challenging, we reviewed the difficulties in differential diagnosis. As illustrated in this case, it is important to consider the possibility of renal PNET in young female patients presenting with a renal mass.

INTRODUCTION

Primitive Neuroectodermal tumour (PNET) of the kidney is an extremely rare malignancy. Renal PNET is highly aggressive presenting at an advanced stage, with distant metastasis and subsequent poor prognosis. It affects young adults with significant mortality owing to the late diagnosis, advanced stage and aggressive course of the disease^[1]. We report a case of primary Renal PNET in a young female.

CASE PRESENTATION

A 20-year old woman was referred because of mild left flank pain, persistent microscopic haematuria and lower urinary tract symptoms of three months duration. Clinical examination revealed only a weak radial pulse, palpable left renal mass with no ascites or peripheral oedema. Ultrasound scan revealed a 11cm left renal mass homogeneously hyperechogenic in comparison with normal renal parenchyma. Chest X-ray was negative. Radical nephrectomy with lymphadenectomy was performed. Eight cycles of chemotherapy with Vincristine, Ifosfamide and Adriamycin, four cycles of Ifosfamide and VP16 and eight sittings of local radiotherapy were sequentially performed. Follow-up examinations failed to show residual or recurrent tumour after 24 months.

MATERIALS AND METHODS

The surgical specimens were formalin-fixed and paraffin embedded. The sections were stained with routine H & E. Immunohistochemistry was performed using avidin biotin complex technique and diaminobenzidine as chromogen. The antibodies used included CD99, Vimentin, cytokeratin, Epithelial Membrane Antigen (EMA), Neuron-Specific enolase (NSE), synaptophysin and Leucocyte Common Antigen (LCA), at suggested dilution. We also performed appropriate routinely positive and negative controls.

RESULTS

Macroscopically nephrectomy specimen measured 11 x 9 x 6 cm and weighed 415gm. The cut-surface showed an encapsulated, grey tan multilobular tumour, with multiple foci of haemorrhage and necrosis. Grossly no normal kidney tissue was identified. Haematoxylin and eosin staining showed the tumour composed of cohesive sheets of small, uniform, primitive cells separated by fibrous bands. Homer-Wright pseudorosettes were present and perivascular rosetting was noted. The cytoplasm showed PAS positivity. Immunohistochemical evaluation revealed a diffuse CD99 positivity in the cytoplasm of neoplastic cells. The tumour cells were also positive for NSE and synaptophysin and

vimentin. In contrast LCA an cytokeratin were negative.

The clinical presentation and the macroscopic aspect, together with the histological pattern, the cytological characteristics and the cellular immunophenotype addressed the diagnosis towards primary PNET of the kidney.

Figure 1

Figure 1: H&E (10x), Cohesive sheets of small uniform, primitive malignant cells separated by fibrous bands. Perivascular resetting is seen.

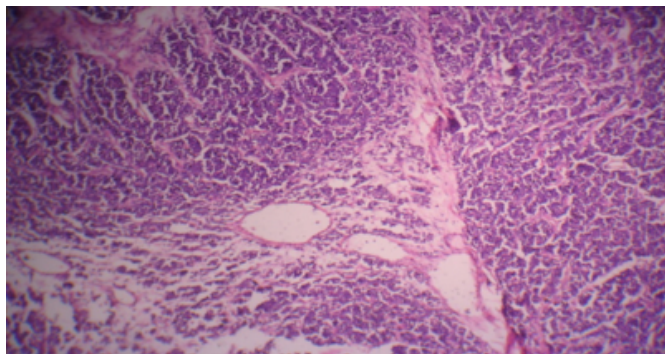
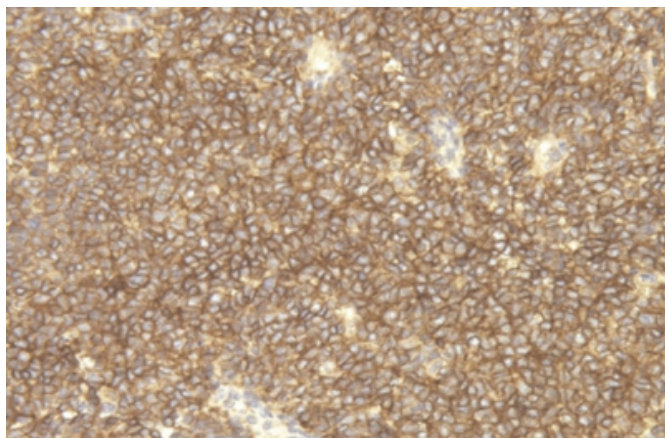


Figure 2

Figure 2: Immunohistochemical staining showing a diffuse expression of CD99 (100x)



DISCUSSION

The peripheral Primitive Neuroectodermal Tumour (PNET), firstly recognized by Arthur Purdy Stout in 1918, is a member of the family of “small round-cell tumours”^[2]. PNET’s arising in the kidney was first reported by Mor in 1994^[3]. A total of approximately 65 primary renal cases have been reported to date. This tumour is most frequently observed in soft tissues of the paravertebral region and chest wall, less frequently in extremities. Patients show a male predominance (58%) with 85% cases being diagnosed during the second to fourth decades primarily among white children.^[4,5] Patients present most frequently with sudden

onset of abdominal or flank pain and gross hematuria, as seen in our case^[1]. Renal PNET is more aggressive than in other sites and distant metastasis involving lung, liver or bone are reported in approximately 20% of the patients at the time of presentation^[2,4]. To date, there is no absolute protocol or treatment for PNET owing to its rarity. The prognosis is poor with a 5-year disease free survival rate of about 50% despite multimodal therapy.

Grossly, PNET’s of the kidney are typically large with 65% measuring greater than 10cm in diameter with replacement of the kidney and weighing 1kg or more in some cases^[4,1]. They tend to be greyish in colour, encapsulated and contain focal areas of haemorrhage or necrosis^[6]. Microscopically, the cells are relatively monotonous polygonal cells whose appearance is dominated by a hyperchromatic rounded nucleus, a finely dispersed chromatin and micronucleus in some cases^[1]. The cytoplasm is intensely PAS positive and mitosis are frequent. Perivascular pseudorosettes and Homer-Wright rosettes are common^[4].

The basic immunophenotype of PNET is the expression of vimentin and the surface antigen of the MIC2 gene, CD99 or HBA-71. Approximately 20% of the cases also express cytokeratin^[1]. In our case the presence of CD99 and vimentin, suggested a PNET diagnosis. PNET’s have a specific chromosomal translocation t(11;12)(q24;q12) which results in a chimeric EWS-FLI1 that is a highly specific molecular marker for PNET^[1].

Morphological and immunophenotypical markers were needed to exclude extra-osseous Ewing’s sarcoma (which are poorly differentiated, do not form pseudorosettes and do not stain positively for neural markers), blastema predominant Wilm’s tumour (which may show areas of stromal or epithelial differentiation, is rarely CD99 positive but frequently shows WT1 expression), metastatic neuroblastoma and clear cell sarcoma (which usually arises in younger patients), synovial sarcoma (which commonly expresses cytokeratin or EMA and shows characteristic t(X;18)), and small cell carcinoma and lymphoma (which completely show different immunophenotypes). These tumours have a common precursor but the stage of differentiation in which it is blocked is probably different. Non-uniform nomenclature of the entity “renal ES/PNET” may have led to underreporting of this entity^[7].

CONCLUSIONS

Primitive neuroectodermal tumour of the kidney is a rare entity. The few cases reported revealed a variable

presentation and an aggressive behaviour. Since the differentiation of small round cell tumours may be challenging, we reviewed the difficulties in differential diagnosis. This could also explain their different biological behaviour and prognosis. As illustrated in this case, it is important to consider the possibility of renal PNET in young female patients presenting with a renal mass.

ACKNOWLEDGEMENTS

We acknowledge Dr. Apurva Shah & Dr. Sanjeev Shah, Consultant Pathologists, Unipath Specialty Lab. Pvt. Ltd., Ahmedabad for the immunohistochemical characterization of the tumour.

References

1. Eble JN, Sauter G, Epstein JI, Sesterhenn IA, World Health Organisation Classification of tumours, Pathology and Genetics of Tumours of the Urinary System and Male Genital Organs, IARC Press, Lyon, 2004.
2. Pomara G, Capello F, Cutanno MG, Rappa F, Morelli G, Mancini P, Selli C. Primitive neuroectodermal tumor (PNET) of the kidney: a case report. BMC Cancer. 2004;4:3. doi: 10.1186/1471-2407-4-3. [PubMed]
3. Mor Y, Nass D, Raviv G, Neumann Y, Nativ O, Goldwasser B. Malignant peripheral primitive neuroectodermal tumor (PNET) of the kidney. Med Pediatr Oncol. 1994;23:437–440. doi: 10.1002/mpo.2950230508. [PubMed]
4. Petersen RO, Sesterhenn IA, Davis CJ, Urologic pathology. 3rd edition. Philadelphia (PA): Lippincott Williams and Wilkins, 2009
5. Devita VT, Hellman S, Rosenberg SA, Cancer-Principles and practice of Oncology. Diseases of the Childhood. 7th edition. Philadelphia (PA) Lippincott Williams and Wilkins, 2005
6. Ong PH, Manikandan R, Philip J, Hope K, Williamson M. Primitive neuroectodermal tumour of the kidney with vena caval and atrial tumour thrombus: a case report. J Med Case Reports. 2008; 2: 265. doi:10.1186/1752-1947-2-265. [PubMed]
7. Businger A, Zettl A, Sonnet S, Ruszat R, Flue M. Primitive neuroectodermal tumour of the kidney in an adult: a case report. Cases J. 2009; 2: 6791. doi: 10.4076/1757-1626-2-6791. [PubMed]

Author Information

Geetanjali Gupta

Department of Pathology, Mahatma Gandhi Medical College and Research Institute

Reecha Singh

Department of Pathology, Mahatma Gandhi Medical College and Research Institute

Pradeep Kumar

Department of Pathology, Mahatma Gandhi Medical College and Research Institute

Dhananjay S. Kotasthane

Department of Pathology, Mahatma Gandhi Medical College and Research Institute