

# Juvenile Spring Eruption

E Dursun, B Battal

## Citation

E Dursun, B Battal. *Juvenile Spring Eruption*. The Internet Journal of Otorhinolaryngology. 2008 Volume 9 Number 1.

## Abstract

Juvenile spring eruption is a photodermatosis characterized by papules and vesicles on the light-exposed helix of the ears after sun exposure. The clinicopathologic features are usually occur in the spring time. We report three cases in which a pruritic, papular and vesicular eruption developed on the ears following sun exposure. We report here the clinical features and investigations of three cases of JSE.

## INTRODUCTION

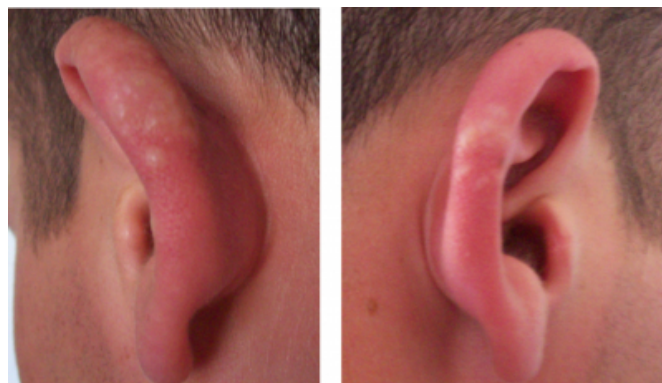
Spring eruption of the ears is a rare photodermatosis originally described by Anderson et al in 1954 (<sub>1</sub>). It has also been called juvenile spring eruption (JSE). Spring eruption of the ears is a distinctive photo-dermatosis characterized by the onset of papules and vesicles on the light-exposed helix of the ears that usually develop in the early spring months and mainly affect juvenile males (<sub>2</sub>). The exact pathogenesis of the disease is not known. The eruption was usually attributed to a combination of sunlight exposure and cold weather. A few case reports of JSE has been reported in the otolaryngology literature (<sub>3</sub>). We report here the clinical features and investigations of three cases of JSE.

## CASE REPORTS

Three 21 year-old soldiers presented in may 2007 with a pruritic erythematous, papular and vesicular eruption over the helices of both ears. Their military unit was at altitude of 2200 m, which frequently has sunny but cold weather during springtime. The soldiers had been doing military exercise under similar weather conditions. Examination revealed a maculopapular or erythematous eruption with several vesicles over the helices of both ears (Fig.1). Physical examination revealed no other abnormalities. There was no history of allergic diseases. They did not report any family history of similar disease or the use of any topical or systemic photosensitizers.

## Figure 1

Figure 1: Erythema and several vesicles over the helices of both ears.



The soldiers were hospitalized for further clinical and histologic investigation. The vital signs, the complete blood counts, serum biochemistry panels and sedimentation rates were within normal limits. Serology testing of various infectious agents was also negative. Ultrasonographic evaluation of cervical lymph nodes was performed on three patients. In two case, ultrasonographic examination revealed reactive lymph nodes in the postauricular region. A skin test (Prick test) was performed to exclude the presence of allergic factors.

The patients were treated with topical steroids and oral antihistamine. In two cases some vesicles ruptured over time and turned to dead epidermis. These lesions became crusted gradually and resolved within 2 weeks, leaving minimal scarring. In one case vesicles was persisted for four weeks. The vesicles were removed with surgical procedure. To prevent recurrences of juvenile spring eruption, the patients were recommended to wear hat, use a high protection sun-cream and avoid noon-day sun.

### DISCUSSION

The eruption consists of pruritic erythematous papules affecting the ears, which may progress to vesicles and then crust and heal with little or no scarring and typically begins in the spring. The eruption also may give rise to cervical adenopathy (3). There are two striking clinical features of spring eruption of the ears. First, the isolated location to the ears without other sun-exposed skin areas involved and second, its presentation as small outbreaks. Both features are due to unknown mechanisms (4).

JSE usually affects young men with short hair. The lesions heal within 2 weeks with minimal or no scarring. Recurrences can be seen. Although some environmental and genetic factors have been linked to the pathogenesis of the disease, the only well-established contributing factor has been exposure to ultraviolet radiation (3).

Although the exact pathogenesis of the disease is not known, JSE is considered to be a localized variant of polymorphous light eruption (PLE). This is mainly on the basis of its distinct epidemiologic and clinical features such as the occurrence in spring and summer, the delayed appearance of lesions several hours after exposure to sunlight, and the transient and often recurrent course of the eruption (5). The histology and immunohistology of JSE lesions are also compatible with PLE, although some authors have observed a histologic similarity of JSE lesions to erythema multiforme (5,6).

In our cases the eruption was attributed to a combination of sunlight exposure and cold weather. High altitude environment very different to that at sea level. At higher altitudes, the sun rays are not filtered as well by the atmosphere. The result is cooler temperatures, combined with increased light intensity. The combination is deceptive,

and potentially dangerous. Ultraviolet (UV) light penetration increases 4 percent per 300 m (985 ft) gain in altitude, increasing the danger of snow blindness, sunburn and, in the long-term, skin cancer (7).

### CONCLUSION

Due to unfiltered sun light, people at high altitude are under risk of JSE. The ears should be protected from sun exposure. Patient should wear hat, use a high protection sun-cream and avoid noon-day sun to prevent recurrences of juvenile spring eruption.

### CORRESPONDENCE TO

Engin Dursun, MD Sarikamis Military Hospital, Department of Otorhinolaryngology 36500, Sarikamis, Kars, Turkey E-mail: drengindursun@yahoo.com Phone: 090 505 8667248 Fax: 090 474 4136264

### References

1. Anderson D, Wallace HJ, Howes HB. Juvenile spring eruption. *Lancet*. 1954; i: 755-6
2. Requena L, Alegre V, Hasson A. Spring eruption of the ears. *Int J Dermatol* 1990;29:284-286.
3. Dogru S, Gungor A, Cekin E, Cincik H, Alga OH. Juvenile spring eruption: a report of two cases. *Laryngoscope*. 2006 Jul;116(7):1279-80.
4. Berth-Jones J, Norris PG, Graham-Brown RAC, et al. Juvenile spring eruption of the ears: a probable variant of polymorphic light eruption. *Br J Dermatol* 1991;124:375-378.
5. Ramsay CA. Juvenile spring eruption. In: Rook A, Wilkinson DS, Ebling FJG, et al., eds. *Textbook of dermatology*. 4th ed. Oxford: Blackwell Scientific Publications, 1986;644-646.
6. Stratigos AJ, Antoniou C, Papadakis P, et al. Juvenile spring eruption: clinicopathologic features and phototesting results in 4 cases. *J Am Acad Dermatol* 2004;50:57-60.
7. Baran R, Civatte J. La photodermatose printaniere juvenile. *Ann Dermatol Venereol* 1980;107:537-541.
8. High-Altitude Medicine. Harris M.D, Terrio J, Miser W.S, Yetter J.F. *American Family Physician*. Vol. 57/No. 8 (April 15, 1998)

**Author Information**

**Engin Dursun, MD**

Department of Otorhinolaryngology, Sarikamis Military Hospital

**Bilal Battal, MD**

Department of Radiology, Sarikamis Military Hospital