

Intestinal Obstruction Due To Ascaris

J Galiano Gil, C Leyva Esturo, R Peña Ayala

Citation

J Galiano Gil, C Leyva Esturo, R Peña Ayala. *Intestinal Obstruction Due To Ascaris*. The Internet Journal of Surgery. 2005 Volume 8 Number 2.

Abstract

More than a billion people worldwide are infected with one or more species of intestinal nematodes. The ascariasis is one of the roundworm parasites more common seen of human being and it is calculated that the world population's fourth part is infected. Although that the clinical pictures of this illness courses mostly with silent form or chronic symptomatology, the massive infestation in children can give place to serious complications that require surgical urgency attention for experts.

The report of a patient of pediatric age is presented with an operative diagnosis of intestinal obstruction for massive ascariasis that required emergency surgical treatment with a favorable evolution. By means of enterotomy overwhelming quantity of ascaris were extracted.

INTRODUCTION

The intestinal parasitism is an endemic clinical condition that prevails in nations with the population's severe imbalances social and economic, where vast sectors they lack the basic services of education, health, housing, and recreation.

Among these parasites, the ascaris lumbricoides is a nematode which is one of the parasitosis of wide diffusion in the world: the ascariasis. A lumbricoides is the most prevalent and the largest of the intestinal nematodes that infect humans This illness is characterized by variable symptomatology ; it is generally asymptomatic in the adult, and it is in children where we see the most florid clinical presentation and the complications of this illness. As most of the intestinal parasite infections, the ascariasis prevails and is endemic in areas lacking of sanitary infrastructure, with precarious housings, poverty and ignorance.

The ascariasis is one of the most cosmopolitan intestinal parasite infections and it can be in inhospitable regions inhabited by human being, but its biggest prevalence is observed in the tropical and subtropical areas.

The world frequency of the infestation varies depending on the region, climate, latitude and economic and cultural conditions of the country in question; and it is considered in 3 billion people in the world, with prevalence of up to 45% in some regions of Asia and Latin America. Estimations

reveal near 1 000 000 of new annual cases and 60 000 fatalities in a year. (1,2)

Although this illness courses with silent form or chronic symptomatology, the massive infestation in children can give place to serious complications that require urgency surgical attention for experts. Intestinal obstruction has been estimated to occur in 2 per 1000 ascaris-infected children per year

For the surgeons of the third world that exercise in hospitals dedicated to the attention of patient of low economic capacity that are generally familiarized with the diagnosis and handling of this pathology; it constitutes a challenge of magnitude and it puts on approval their know-how when facing this type of patient.

Motivated by the non worthless morbimortality of this entity, it becomes feasible the purpose of this report when presenting a patient of pediatric age with diagnosis of intestinal obstruction for massive ascariasis that required of emergency surgery as treatment with a favorable evolution.

Clinical Case

A 3 years old male patient who was taken to the hospital with abdominal colic pain of more than 3 days of evolution, becoming continuous pain later. Not passing stools neither fecal gases and scanty urine output were associated clinical elements.

Antecedents of health of having expelled parasites by mouth 6 months previously were recorded.

Clinically he was showing a toxic aspect, dehydrated with abdominal distension, as well as tachycardia and the increase of the breathing frequency.

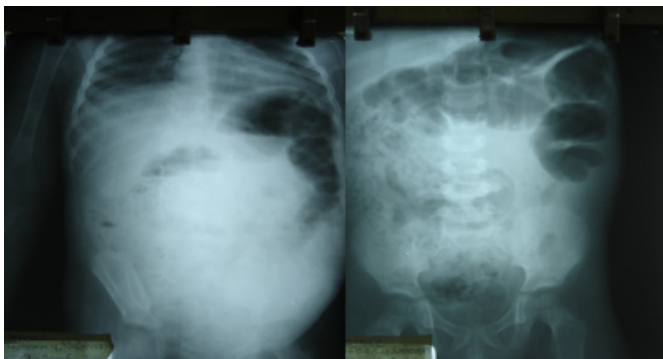
The physical exam of abdomen showed distension with guarding and peritoneal irritation in right abdomen. Intestinal sounds diminished. Rectal examination with empty ampulla was found.

High level of leucocytes with neutrophils prevalence characterized the white cell count, with an inferior limit hematocrite.

On Abdominal x ray, we have seen distension of small and large bowel with air fluid levels, with great quantity of accumulated feces. (Figure 1)

Figure 1

Figure 1: Small and large distension of bowel with air fluid levels. Accumulated feces in right colon and rectal sigma area.



With the diagnosis of acute abdomen for possible complicated acute appendicitis the child was taken to the operating theater, ascaris package obstructing the end of small bowel, 30 centimeters to the ileocecal valve and other similar package were found in proximal jejunum. Vascular compromise of the intestine did not exist. (Figures 2 and 3)

Figure 2

Figure 2: Distension of small bowel for ascaris package in its lumen.

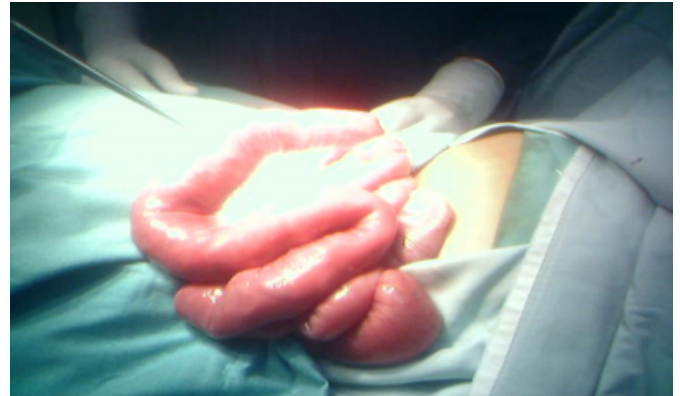

Figure 3

Figure 3: Pool of extracted ascaris of the intestine by means of enterotomy.

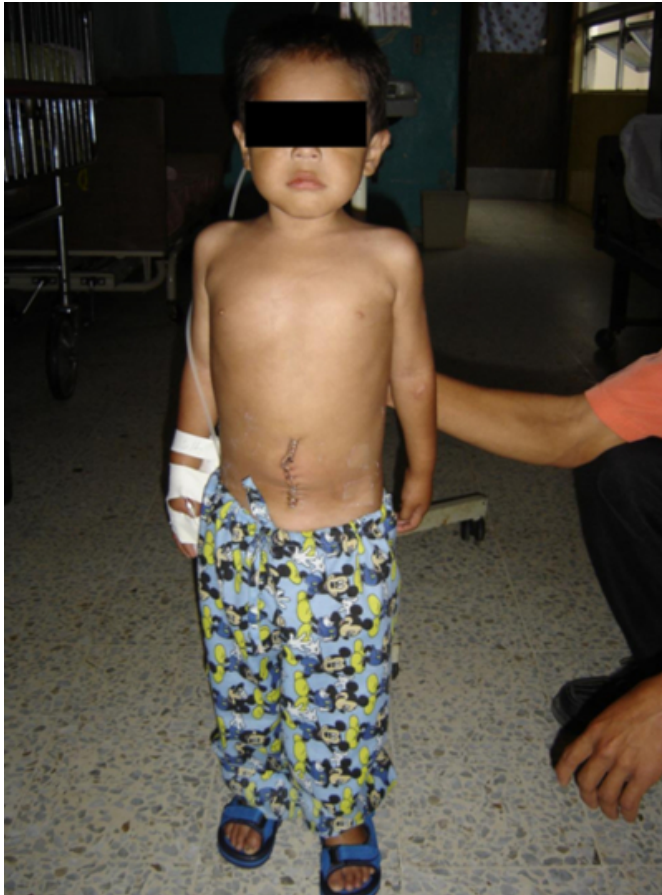

The maneuvers of milking and displacement of the ascaris toward the caecum is failed by the compact package of the parasites. Enterotomy was decided to carry out from where hundreds of ascaris were removed.

Favorable postoperative evolution with medical treatment. Firstly, piperazine was given and later, albendazol was prescribed. (Figures 4)

Figure 4

Figure 4: Postoperative period of paediatric patient after ascaris extraction by enterotomy.



DISCUSSION

The ascariasis is one of the intestinal parasites infections more common of the human being and it is calculated that the world population's fourth part is infected. It is intimately related with the malnutrition and the geographical distribution with prevalence in tropical countries.

The form of more frequent presentation is the chronic infection, which mostly contributes to the process that takes to the malnutrition. It can happen to any age, being more frequent in children of school age and persisting in the adulthood.

Every year, 60.000 deaths are attributed directly to this infection.

This helminthic infection is acquired by the ingestion of eggs; the larvae during their migration go by the lung to complete their maturation, they ascend for the respiratory tree and then continuing go up for later to be swallowed and arrive to the small intestine where they become adults.

The clinical illness is restricted to subject with important load of parasites. This minority represents from 1,2 to 2 million cases with clinical manifestations in the world, being considered around 50.000 deaths a year for severe illness caused by *ascaris lumbricoides*. (2,3)

The infested patients could not have any symptom, or to manifest low of weight, chronic abdominal colic pain, nausea, vomiting and the elimination of parasites by stools. Children could have retardation related growth and weight, and inclusive get the nutritional deficit.

Most of children have the antecedents of ascaris expulsion by rectum, and patients with intestinal obstruction is common to records parasites expulsion by mouth, which help as an element to keep in mind for making a right diagnosis. (4,5,6)

The diagnosis is carried out by means of the visualization of the eggs in the direct exam of fecal matter. The mature females can also be visualized in feces. In few cases that the infection is only for males, there are not eggs in the stools, and an abdomen x-ray allows visualizing the parasites in the intestine.

One of the peculiarities that characterize the massive infestation conditioned by these worms is the enormous capacity that they possess to invade spaces, organs, conduits and cavities of the human body where it is not normal to find them, for what this extensive chapter has been denominated in the international literature as "erratic or ectopic ascariasis". (3,4)

As consequence of the erratic localizations, the presence of parasites has been described in biliar ducts, nasal graves, hearings, fallopian tubes, gallbladder, among others. All these presentations are strange, but they can cause difficulties at the time of making the diagnosis. Cases of gastric bezoar have been reported by ascaris.

The extraintestinal migrations of the *ascaris lumbricoides* is clearly described, and they can end up being solved medical and surgically.

In cases of massive infestation it can have intestinal obstruction due to a bolus of parasites and volvulus of the obstructed segment of the small intestine that requires surgery sometimes. (7,8)

The obstruction is usually partially, but when it is lasting, it could become complete.

There are some factors that make possible the mechanical intestinal obstruction, like a great quantity of parasites which is the most frequent cause of surgical emergency, related with the form of “U” that the ascaris assumes exercising pressure on the intestinal wall. Additionally, this obstruction could happen where ascaris excretes neurotoxins that cause contractions of the small bowel. In recent studies it was found that anthelmintic medications can be present previous to the presentation of the clinical picture of intestinal obstruction. This fact is related with a poorer outcome. ^(9,10)

The abdominal x-ray shows air fluid levels and multiple lineal images of ascaris lumbricoides in the dilated intestinal loops. Abdominal ultrasound could demonstrate an

dilated intestinal loop, with thicker wall and a mass of worms that cause the obstruction. The group of parasites images is described like an echogenic complex mass of intestinal air, parasites and fecal matter, with morphology of jellyfish head in the longitudinal axis and of rouselike in the transaxial cut. The Ultrasound plays an important paper to make a diagnosis of the biliar presentation of parasites.

An important dose of anthelmintic medications conditions that a great hank of paralyzed parasites could obstruct the intestinal lumen displacing worms by peristalsis toward the end of small bowel. Some researches highlight that anthelmintic drugs may produce spastic paralysis of roundworm parasite, and it is related with complete obstruction and impossibility to carry out the milky maneuver like part of the surgical handling. A lingering obstruction it can get complicated with intussusception, volvulus, hemorrhagic or necrotic bowel; or even perforation. ^(11,12,13)

The prognosis is good in the event of partial obstruction. Partial intestinal obstruction should be managed with intravenous fluid administration, nasogastric suction, and instillation of piperazine through the nasogastric tube, but complete obstruction and its severe complications require immediate surgical intervention.

It is believed that administration of anthelmintic drugs in children with abdominal pain with a subacute obstruction makes worse the clinical picture and leads to serious complications. The medication during this period can guide to complete paralysis of an important number of parasites and accumulate them at level of distal small bowel blocking the lumen.

The treatment, firstly, is conservative with handling

appropriate hidroelectrolitic, nasogastric suction, antibiotics and anthelmintic therapy. It has been ended up using the gastrografin that is a hiperosmolar substance that produces an excess of fluid around the obstructing mass of worms conditioning their separation, to reason of 15 to 30 ml introduced in the stomach, through a nasogastric tube to treat the partial intestinal obstruction. ^(3,6,14,15)

The laparotomy is indicated only in following situations: persistence of the abdominal mass in the same place for more than 24 hours, persistent abdominal pain with a painful mass, toxemia and heart frequency increased with disappearance of the mass. The commonly used procedure is the milky maneuver and to displace the hank of parasites in manual form (to milk). If this maneuver does not give result, the parasites can be extracted by enterotomy. If the intestine shows any evidences or signs of gangrene, it is mandatory and necessary the intestinal resection.

The intestinal parasitism is an illness of a non insignificant morbimortality, fundamentally in pediatric ages. The corner stone of its treatment is its prevention.

In principle, ascariasis can be prevented by sanitary disposal of human feces and good personal hygiene. In practice, this is difficult to achieve. Ascaris eggs are relatively stable in the environment and can persist for years. Community-based mass treatment programs are effective for the short term, but treatment must be repeated periodically.

For ended, it becomes imperative the proposal of an action plan guided to the preventive treatment of the parasitic infestation.

Inside the elements to highlight in having mentioned plan, we can mention:

- “The population's sanitary hygienic education.”
- “Talking and teaching audiences to risk groups.”
- “To empower the authorities and popular leaders about the necessity of the sanitary prevention to counteract the intestinal parasitism.”
- “Design of projects supported in Non Government Organizations with the objective to avoid and abolish the outdoors fatalism; and a better and more appropriate control of the fresh water for consumption.”
- “The implementation of anthelmintic medication

campaigns periodically.”

References

1. Drake L, Bundy D. Multiple helminth infections in children; impact and control. *Parasitological* 2001; 122:73-81.
2. Philip J, Chico M, et al. Human infection with *Ascaris*. *J Infect Dis* 2000; 182:1207-13.
3. Comoro MA, Kantar J. Non-operative management of intestinal obstruction due to *ascaris lumbricoides*. *J Cull Physicians Surge Pak*. 2003 Feb; 13(2):86-9.
4. Prada Silvy, CD. *Avances Pediátricos*. Gac Méd Caracas, jul. 2004, vol.112, no.3, p.218-223.
5. Dávila GC, Trujillo HB, Vásquez C. Prevalencia de parasitosis intestinales en niños de zonas urbanas del estado de Colima, México. Vol. *Med Hosp. Infanta Mes* 2001; 58: 234-9.
6. Vásquez Tsuji, O et al. Antihelmínticos como factor de riesgo en la obstrucción intestinal por *Ascaris lumbricoides* en niños. Vol.. *chil. parasitol., ENE*. 2000, vol.55, no.1-2, p.3-7. ISSN 0365-9402.
7. Correa Antúnez, M.I.; Serrano Calleja. ; Pimentel Leo, J.J.; Sanjuán Rodríguez, S. " Bezoar Gastrico" *Cir pediatr* 2001, 14: 82-4
8. Montiel-Jarquín, A; Carrillo-Ríos, C; Flores-Flores, J. *Ascaridiasis vesicular asociada a hepatitis aguda*. Manejo conservador. *Cir Ciruj* 2003; 71: 314-318
9. Kamiya T, Justiano M, Durán A, Uechi C. Biliopancreatic ascariasis: endoscopic approach. *J Gastroenterol* 2002;37(Suppl 13):97-9
10. Chiarpenello, J. Actualización: Infecciones por helmintos. *Evid. actual. práct. ambul*. 2004;7: 178-181
11. Rodríguez-García AJ, Belmares-Taboada J, Hernández-Sierra JF. *Ascaris lumbricoides*-caused risk factors for intestinal occlusion and subocclusion. *Cir Cir*. 2004 Jan-Feb;72(1):37-40.
12. Vásquez Tsuji O, et al. Anthelmintics as a risk factor in intestinal obstruction by *Ascaris lumbricoides* in children. *Bol Chil Parasitol*. 2000 Jan-Jun;55(1-2):3-7.
13. Mahmood T, Mansoor N, Quraishy S, Ilyas M, Hussain S. Ultrasonographic appearance of *Ascaris lumbricoides* in the small bowel. *J Ultrasound Med*. 2001 Mar;20(3):269-74.
14. Boujaoude J, Abboud B, Chemaly M, Hachem K, Zoughbi A. An unusual case of biliary pain. *Gut*. 2005 Aug;54(8):1106, 1145.
15. Mukhopadhyay B et al. Clinical appraisal of *Ascaris lumbricoides*, with special reference to surgical complications. *Pediatr Surge Int*. 2001 Jul;17(5-6):403-5.

Author Information

Jesús Miguel Galiano Gil

2do Degree Specialist in General Surgery, Auxiliary Professor of Surgery, "Dr. Salvador Allende" Faculty of Medicine, "Dr. Salvador Allende" Teaching Hospital

Celia María Leyva Esturo

1er Degree Specialist in Comprehensive Medicine

Ricardo Peña Ayala

Specialist in General Surgery, "San Marcos de Ocotepeque" Hospital