

Tenosynovitis Secondary To Candida Magnoliae In An Immunocompetent Host: Candida Magnoliae Tenosynovitis

J Lane, M Lee, J Stephens

Citation

J Lane, M Lee, J Stephens. *Tenosynovitis Secondary To Candida Magnoliae In An Immunocompetent Host: Candida Magnoliae Tenosynovitis*. The Internet Journal of Internal Medicine. 2000 Volume 3 Number 1.

Abstract

Candida magnoliae has been rarely reported in clinical specimens. Furthermore, fungal tenosynovitis requiring surgical intervention is uncommon. The differential diagnosis for this type of nonpyogenic inflammation is diverse and should include fungal and acid fast bacilli as causes. We report a case of fungal tenosynovitis in an immunocompetent host secondary to *C. magnoliae*.

INTRODUCTION

Candida magnoliae is rarely reported in clinical specimens and has never been reported as a human pathogen. Additionally, fungal tenosynovitis requiring surgical intervention is uncommon. The differential diagnosis for such a nonpyogenic inflammation is diverse and should include fungal and acid fast bacilli as causes. We report a case of fungal tenosynovitis in an immunocompetent host secondary to *C. magnoliae*.

CASE REPORT

A previously healthy 9-year-old boy presented with swelling, pain, and decreased mobility of his left ring finger. The swelling was present for 3 to 4 weeks with no history of trauma or fever. The child was reported to often climb a magnolia tree at his home. He had no pain except with light contact. The child had no significant medical or surgical history.

Physical examination revealed a well-developed, well-nourished child who was alert but in mild distress. Vital signs were normal. Neurological, cardiovascular, pulmonary, and abdominal examinations yielded normal findings. Examination of the left fourth finger revealed swelling primarily over the distal end of the middle phalanx. There was no erythema, tenderness, or warmth of the finger. There was limited isolated movement in his finger at the middle and distal phalanx. Radial pulses were present and there were no signs of trauma.

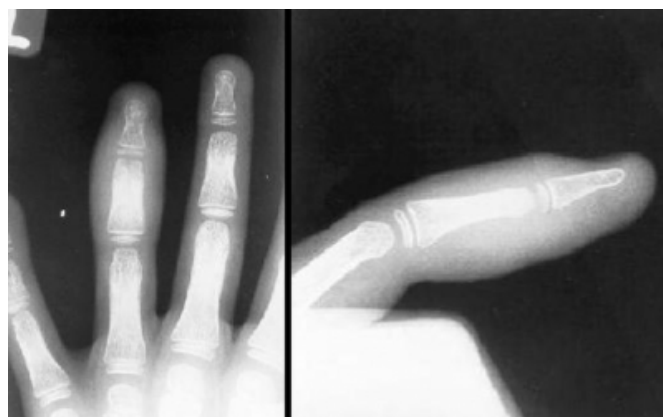
Laboratory studies revealed a leukocyte count of 8,300/ μ l,

with 57 % neutrophils, 31 % lymphocytes, 9 % monocytes, 2 % eosinophils, and 1 % basophils. His hemoglobin and hematocrit were 12.7 mg/dl and 35.7 %, respectively. Platelet count was 252,000 / μ l. The erythrocyte sedimentation rate was 12 mm/hr and C-reactive protein less than 0.4 mg/dl. Rheumatoid factor, antistreptolysin, and antinuclear antibody screens were also normal.

Plain radiographs of the finger showed soft tissue swelling at the distal interphalangeal joint and middle phalanx of the fourth ray (Figure 1).

Figure 1

Figure 1: Plain film of left hand demonstrates soft tissue swelling of the fourth digit with subtle resorption of epiphysis of terminal phalanx at presentation.



Magnetic resonance imaging of the involved finger revealed abnormal signal on T1 and T2 weighted images within the epiphysis of the distal phalanx of the fourth ray extending completely into the middle phalanx (Figures 2-4).

Figure 2

Figure 2: Coronal T1 magnetic resonance imaging of fourth digit shows severe loss of normal marrow signal in mid phalanx of fourth digit.

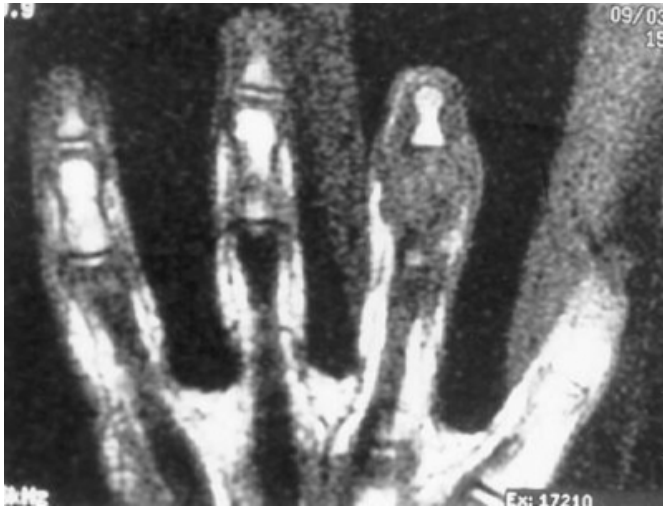

Figure 3

Figure 3: Axial fast spin echo T2 imaging with fat repression demonstrates severe increased signal in middle phalanx of fourth digit with surrounding increased signal intensity consistent with marrow and soft tissue edema.

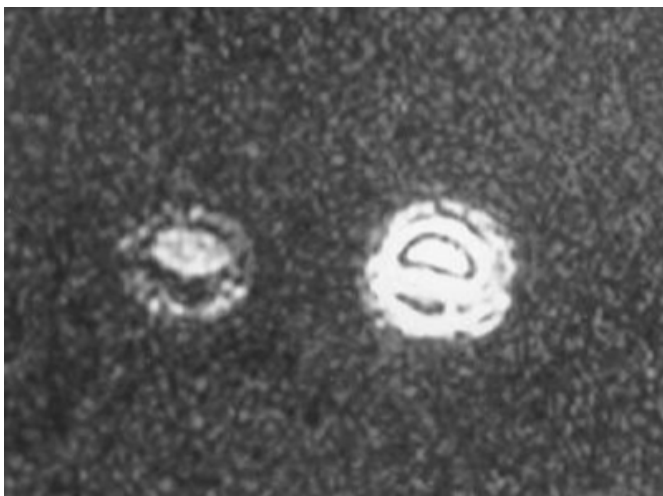
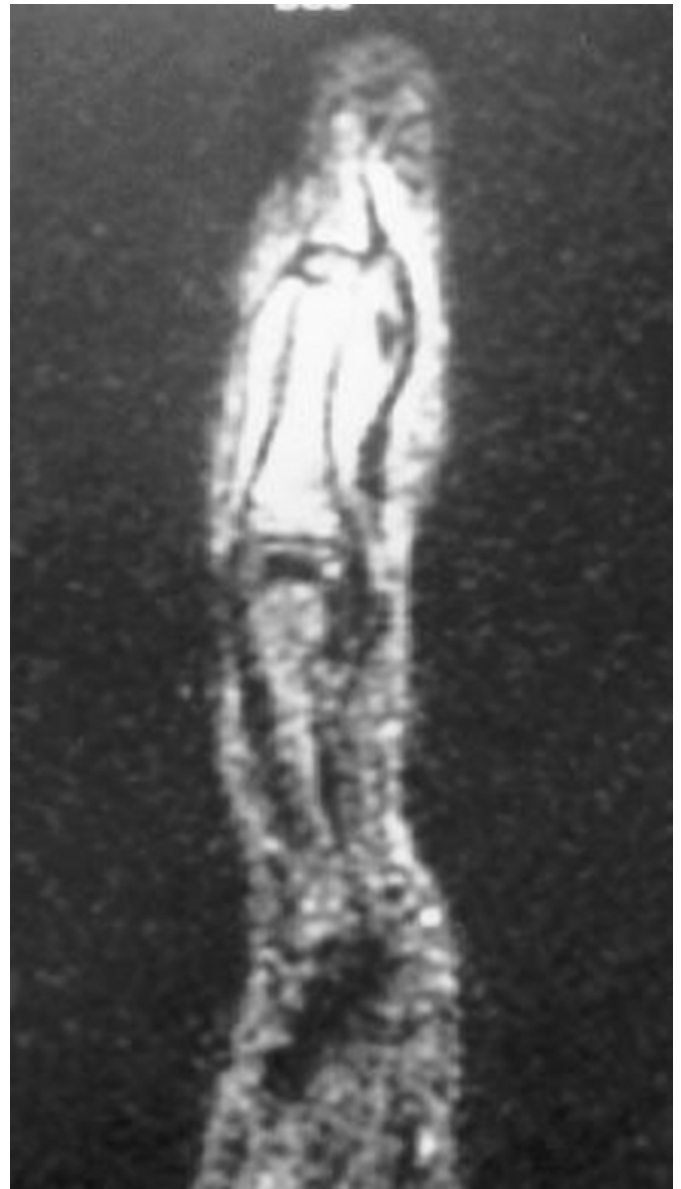

Figure 4

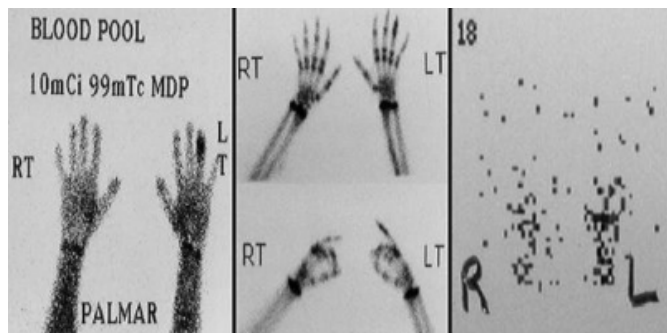
Figure 4: Sagittal magnetic resonance imaging with inversion recovery of fourth digit demonstrates severe increased signal in middle phalanx of fourth digit with surrounding increased signal intensity consistent with marrow and soft tissue edema.



The abnormal signal intensity was within surrounding soft tissue that displaced the flexor digitorum profundus tendon and extensor retinacular ligament. A 3 mm focal area of low signal intensity dorsal to the flexor digitorum profundus tendon at the level of the distal aspect of the middle phalanx was also seen. Three phase bone scan also demonstrated increased activity in the distal aspect of the fourth digit (Figure 5). These radiographic findings were suggestive of osteomyelitis or septic arthritis.

Figure 5

Figure 5: Three phase bone scan shows increased activity in distal aspect of fourth digit on blood pool and delayed images and minimal increase on radionuclide angiogram of left hand consistent with osteomyelitis.



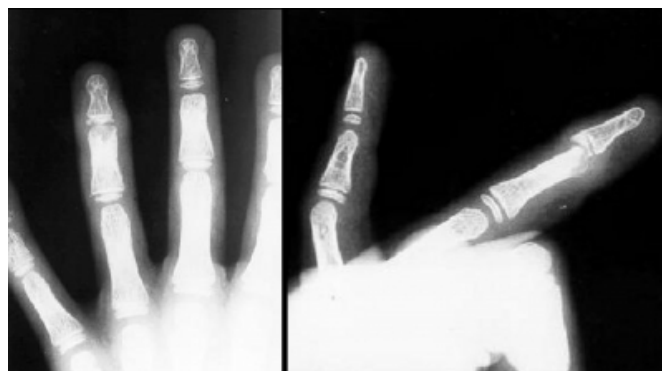The child underwent surgical irrigation and debridement of the left fourth finger. He was taken to the operating room where a standard Kocher incision and arthrotomy was performed. Frank pus was aspirated; however, exploration of the middle and distal interphalangeal joints revealed no signs of chondral or osseous damage. Intraoperative tissue biopsy, bone biopsy, and synovial sampling were obtained and submitted for gram stain, culture, and sensitivity. Gram stain of both the tissue and synovial sample revealed few leukocytes and no organisms. Both tissue and synovial samples were negative for acid fast bacilli and on routine cultures. Bone biopsy was normal. Both the solid tissue biopsy and synovial sample demonstrated chronic synovitis with periarticular edematous fibrovascular connective tissue. The synovium had a chronic inflammatory process characterized by synovial cell hyperplasia, vascular proliferation, and infiltration by lymphocytes and plasma cells. There was no histopathologic evidence of pyogenic abscess formation, granulomatous formation, hemosiderin deposition, or foreign body. Periodic acid schiff and acid fast bacilli stains were negative. Fungal cultures of both the tissue and synovium revealed growth of *Candida magnoliae*. Fungal sensitivity revealed a minimum inhibitory concentration 0.5 µg/ml for fluconazole, and 0.125 µg/ml for both itraconazole and ketoconazole. Confirmation of *C. magnoliae* was repeated by two additional independent laboratories.

The patient underwent an uneventful postoperative course. He remained afebrile and had decreased swelling of his finger. He was able to flex and extend approximately 30° at the distal interphalangeal joint without any pain. Subsequent plain films of the left hand showed residual soft tissue swelling with destruction of epiphysis of terminal phalanx

and distal metaphysis of middle phalanx and dorsal dislocation of the terminal phalanx (Figure 6).

Figure 6

Figure 6: Plain film of left hand after resolution reveals soft tissue swelling of the fourth digit with destruction of epiphysis of terminal phalanx and distal metaphysis of middle phalanx. Film also shows dorsal dislocation of terminal phalanx and severe distal interphalangeal joint space narrowing.



A regimen of fluconazole was considered if the patient did not continue to improve; however, complete resolution was achieved without any clinical or radiographic evidence of recurrence.

DISCUSSION

This is the first reported case of *Candida magnoliae* infection in a human. Dermatomycosis and onychomycosis are commonly seen in the general population; however, invasive fungal tenosynovitis is extremely rare and typically seen only in immunocompromised hosts [1,2]. The patient in this case was immunocompetent and had no medical problems.

Candida magnoliae has been reported in association with flowers, bees, fruit juice, and birds; however, it is rarely isolated in clinical specimens and has never been reported in the literature as a human pathogen. While the possibility of contamination must be entertained in all such reports, the specimen was obtained from a sterile surgical site without any apparent contamination. Additionally, the clinical history of exposure combined with three independent laboratory cultures supported the confirmation.

CORRESPONDANCE

Joshua E. Lane, M.D. The Medical College of Georgia 1004 Chafee Ave. Augusta, GA 30912 Phone: (706) 721-6231 Fax: (706) 721-6220 E-mail: joshua.lane@lycos.com

References

1. Townsend DJ, Singer DI, Doyle JR. Candida tenosynovitis in an AIDS patient: a case report. J Hand Surg 1994; 19 (2): 293-294.
2. Yuan RT, Cohen MJ. Candida albicans tenosynovitis of the hand. J Hand Surg 1985; 10 (5): 719-722.

Author Information

Joshua E Lane, MD

Resident, Department of Internal Medicine, Division of Infectious Disease, Mercer University School of Medicine

M Allen Lee, BS

Medical Student, Department of Internal Medicine, Division of Infectious Disease, Mercer University School of Medicine

Jeffrey L Stephens, MD

Associate Professor, Department of Internal Medicine, Division of Infectious Disease, Mercer University School of Medicine