

A Rare Case of Fistula in Ano Presenting as a Painful Gluteal Lump

I Shaikh, S Yalamarathi, K Joga, A Sharma, T Daniel

Citation

I Shaikh, S Yalamarathi, K Joga, A Sharma, T Daniel. *A Rare Case of Fistula in Ano Presenting as a Painful Gluteal Lump*. The Internet Journal of Surgery. 2008 Volume 18 Number 1.

Abstract

Fistula in ano can have varied presentation. Management of these patients can sometimes be too demanding even for experienced colorectal surgeons. We report an atypical presentation of fistula in ano as a gluteal swelling and progressively increasing pain without any perianal symptoms. MRI investigation clarified the diagnosis and directed the management of this patient.

INTRODUCTION

Fistula in ano is a benign anal condition, incidence is reported to be around 1 in 10000 [1]. By definition this is an abnormal connection between anorectal epithelium and perianal skin. This condition presents as a chronic discharging wound in the perianal area or as an acute exacerbation including perianal/ischiorectal abscess. Various classifications [2] have been described to simplify the management. The main aims of the treatment are eradication of sepsis, management of fistulous tract and preservation of the anal sphincter integrity. The surgical options include laying opening of a low anal fistula, Seton insertions and various plastic surgical flap reconstructions especially in complex fistulae due to Crohn's disease [3,4].

However, this condition still can pose a management problem even for experienced colorectal surgeons. Fortunately, advancement in radiological investigations such as MRI and endoanal ultrasound examination has helped in the diagnosis and guided in the management of complex and recurrent fistulae in ano [1].

We report an unusual presentation of fistula in ano identified after MRI scan of the gluteal region.

CASE REPORT

A 23-year-old female patient presented with complaints of progressively increasing pain and swelling in the right gluteal region of 18 months duration. She was unable to sit on her right side due to pain. Her past history included a colonoscopy for constipation, which was unremarkable. The

clinical impression was that of a soft-tissue tumour involving the gluteal region. An MRI scan of gluteal region was performed to further characterise and define the extent of this swelling. Surprisingly the MRI scan showed an extensive inflammatory change in the deep subcutaneous tissues superficial to the right gluteus maximus muscle as well as involving the muscle fibers. A large caliber fistulous track was running medially from the gluteal area up to anal canal. The features were suggestive of suprasphincteric fistula with an opening at around 7 o'clock position above the dentate line (Figure 1a and 1b). There was another short blind track at 5 o'clock position.

Based on the above finding she was admitted in for an examination under anaesthesia (EUA) of her anal canal. Immediately prior to the EUA, her symptoms were worsened. She had developed a tender, erythematous and immobile swelling in the gluteal region with features suggestive of acute inflammation. There were no symptoms related to her perianal area even at that stage.

At EUA there was an internal opening identified with some difficulty at 7 o'clock (lithotomy position) position which was aided by MRI images. On probing, this track was heading towards the gluteal region as noted in the scan. However, this appeared to be a blind tract with no external opening. It was decided to disconnect the long tract and convert it into a fistula with opening in the perineal area. An incision was made at 7 o'clock position over the perineum. A loose draining seton was inserted through this incision and the internal opening. At follow-up after 6 weeks, she was pain-free at the gluteal area and the gluteal signs had

resolved. This resulted in satisfactory improvement in the social life of this patient. The further management plan is to repeat MRI scan and to treat accordingly.

Figure 1

Figure 1a: Transverse axial fat suppressed T2-weighted images of the pelvis demonstrating the abscess and inflammatory response in the right gluteus maximus, with thick fistulous track heading along the right side of the perineum towards the rectum a

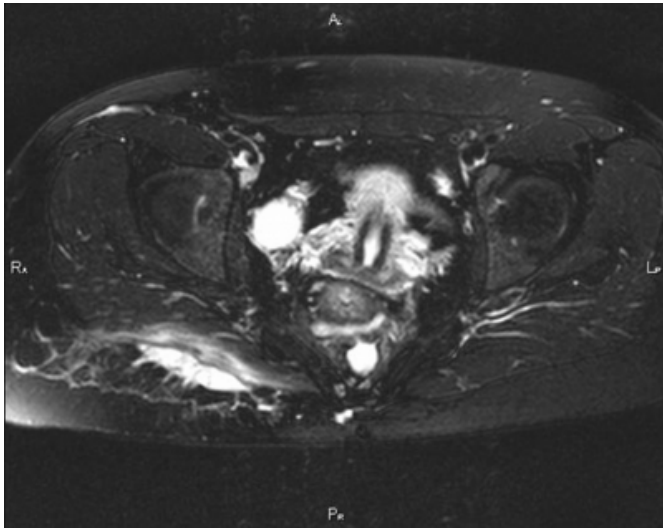
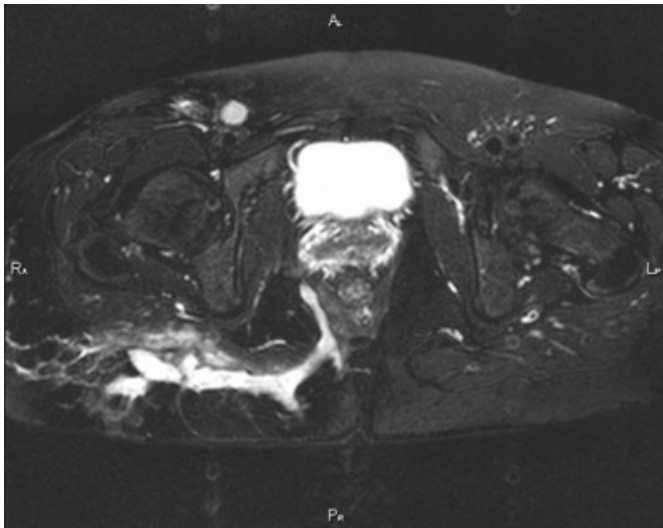


Figure 2

Figure 1b: ...encircling the posterior rectum, with a smaller track heading posteriorly to a pre-coccygeal abscess.



DISCUSSION

The various presentations of perianal fistula are due to local anatomical planes. A clear understanding of the relationship between anorectal and pelvic anatomy is vital to the management of fistula in ano. The recurrence can be up to

25%. This could be due to inadequate clearance of all tracts, failure to recognise occult sepsis and inadequate preoperative planning.

Review of literature shows that gluteal abscess has not been described as a presentation of fistula in ano. However, Crohn's disease, psoas abscess and pyonephrosis can present as a gluteal abscess [5,6,7]. Although there was no distinct external opening, we feel it was reasonable to classify this case as a suprasphincteric fistula. It had traversed above the sphincters with an internal opening in the anal canal and externally it involved the gluteal skin which was about to discharge pus.

MRI seems to be the preferred diagnostic and preoperative imaging modality to evaluate complex fistula in ano as well as soft-tissue tumors [1]. We feel that this form of clinical presentation of fistula in ano has not been reported and it highlights the importance of the MRI scanning in the evaluation of problems in the gluteal region, as our initial suspicion was that of a soft tissue-tumour. Although in our case there was no evidence to suspect anal fistula, certainly MRI scan helped in making the diagnosis in this young female and also helped in the management by delineating the complex fistula tract.

In conclusion anal fistula has a varied presentation which could be without perianal symptoms. MRI scanning is the investigation of choice in evaluating complex fistulae in ano.

CORRESPONDENCE TO

Mr. Irshad Shaikh Specialist Registrar Department of Surgery Queen Margaret Hospital Fife KY12 0SU United Kingdom Email: i.shaikh@nhs.net Phone 01383623623

References

1. Halligan S, Buchanan G MR imaging of fistula-in-ano. *European Journal of Radiology* 2003; 47:98-107
2. Rosa G, Lolli P, Piccinelli D, Mazzola F, Bonomo S: Fistula in ano Anatomoclinical aspects, surgical therapy and results in 844 patients. *Tech Coloproctol* 2006; 10:215-221
3. Davies M, Harris D, Lohana P, Chandra Sekaran TV, Morgan AR, Beynon J, Carr ND The surgical management of fistula-in-ano in a specialist colorectal unit. *Int J Colorectal Dis* 2008; 23:833-8
4. McCourtney JS, Finlay IG Setons in the surgical management of fistula in ano. *Br J Surg* 1995; 82:448-452
5. Kobayashi H, Sakurai Y, Shoji M, et al. Psoas abscess and cellulitis of the right gluteal region resulting from carcinoma of the cecum. *J Gastroenterol* 2001; 36:623-628
6. Hussien M, Mudd DG. Crohn's disease presenting as left gluteal abscess. *Int J Clin Pract* 2001; 55:217-218
7. Kottasz S, Galos L, Kantor M, Schalkovszky E. Gluteal fistula that developed spontaneously from pyonephrosis. *Acta Chir Acad Sci Hung* 1978; 19:281-288

Author Information

I. Shaikh, MD, MRCS
Queen Margaret Hospital

S. Yalamarthy, FRCS
Queen Margaret Hospital

K. Joga, MRCS
Queen Margaret Hospital

A. Sharma, FRCR
Queen Margaret Hospital

T. Daniel, FRCS
Queen Margaret Hospital