

# Giant Asymptomatic Mucocele Of The Appendix: A Case Report And Review Of Literature

M Yasar, A Aslaner, A Zengin

## Citation

M Yasar, A Aslaner, A Zengin. *Giant Asymptomatic Mucocele Of The Appendix: A Case Report And Review Of Literature*. The Internet Journal of Surgery. 2005 Volume 7 Number 2.

## Abstract

We report a case of a 55-year-old male patient. Laboratory data were normal. He was asymptomatic until the routine check-up. Ultrasonography and Computerized Tomography examination demonstrated a pericecal cystic mass (15cm &times; 10cm). Fine needle aspiration was performed. Cytology confirmed the diagnosis of mucocele. The patient underwent partial cecum resection and extirpation of the mucocele. He recovered well and the final histology revealed a cystadenoma of the appendix. At the end of one year follow up the patient is free of symptoms. Although primary adenocarcinoma of the appendix is uncommon, the authors emphasize that preoperative diagnosis of an underlying malignancy in a mucocele is important for patient management; however, it is difficult on imaging studies.

## INTRODUCTION

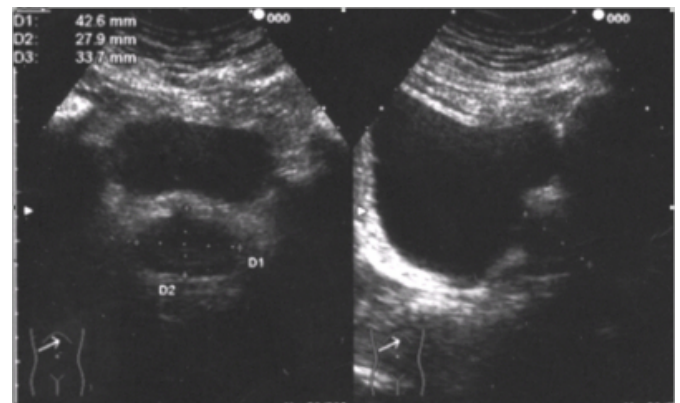
Appendiceal mucocele (AM) is a rare entity that can present in a variety of clinical syndromes or can occur as an incidental surgical finding. The prevalence of AM is 0.2-0.4% among appendectomies (<sub>1,2</sub>). The anatomic location of AM in the right lower quadrant of the abdomen includes it in the differential diagnosis of masses in this region. Although it was a giant tumor, it persist asymptotically.

## CASE REPORT

A 55-year-old male patient admitted to our clinic for a routine check-up. He presented without symptoms. Laboratory data were normal (sedimentation (ESR): 23 mm/h, CRP: 2 mg/L, leucocytes: 9.750 g/L, haemoglobin: 15,3 g/L, platelets: 345 g/L). Abdominal US and CT examination demonstrated a pericecal cystic mass (15cm x 10cm, Figure 1). Fine needle aspiration was performed. Cytology confirmed the diagnosis of mucocele.

## Figure 1

Figure 1: Ultrasonographic appearance of the mass at USG.



The patient underwent partial cecum resection and extirpation of the mucocele. He recovered well and the final histology revealed cystadenoma of the appendix. At the end of one year follow up the patient is free of symptoms.

## DISCUSSION

AM is a descriptive term for mucinous distension of the appendiceal lumen regardless of the underlying pathology. Four causal pathologic conditions have been reported: retention cyst, mucosal hyperplasia, cystadenoma and cystadenocarcinoma (<sub>3</sub>). The external appearance is gross enlargement of the appendix, the lumen is distended by mucin. Recent reports, however showed a distinct male predominance (4:1) (<sub>3</sub>), and in a retrospective study of 135 surgically resected patients 55% of the patients were females

(<sub>4</sub>).

Clinical manifestations include palpable abdominal mass, gastrointestinal bleeding and lower right abdominal pain (<sub>3,5</sub>). But it was asymptomatic in our case. Thus, although it is nonspecific, when a mass is palpable or detected incidentally by imaging studies in the lower right abdomen in a patient without a history of appendectomy, we must consider the possibility of AM. Other signs reported in some cases include weight loss, nausea/vomiting, acute appendicitis, changes in bowel habits, and unexplained anaemia (<sub>4</sub>). Symptomatic patients were reported, more likely, to have a malignant disease. There have been reports of other tumors associated with AM, including gastrointestinal tract, ovary, breast and kidney tumors, which might occur in up to one-third of the patients (<sub>4,5</sub>). US and CT were the major diagnostic imaging studies.

Surgical resection is the current method of choice in the management of AM (<sub>4</sub>). Open surgery was performed in most of the cases: appendectomy alone or combined with right hemicolectomy and in some female patients also bilateral salpingo-oophorectomy or total abdominal hysterectomy were performed. Laparoscopic resection of AM was also reported (<sub>1,2</sub>). Peritoneal dissemination from AM was not regarded as a problem with open appendectomy, along with long survival in these patients. The overall 5-year survival was reported to be 55% in 94

unselected AM patients (<sub>6</sub>).

In conclusion, presence of a giant tumor can be asymptomatic until a routine check-up.

### CORRESPONDENCE TO

Mehmet YASAR, MD Abant Izzet Baysal University  
Department of General Surgery, Konuralp-81100, DÜZCE.  
TURKEY. Tel: +90 380 5414107 Fax : +90 380 5414105 e-mail: myasar59@yahoo.com

### References

1. Caspi B, Cassif E, Auslender R, Herman A, Hagay Z, Appelman Z. The onion skin sign: A specific sonographic marker of appendiceal mucocele. *J Ultrasound Med* 2004; 23:117-21
2. Gonzalez Moreno S, Shmookler BM, Sugarbaker PH. Appendiceal mucocele. Contraindication to laparoscopic appendectomy. *Surg Endosc* 1998; 12:1177-9.
3. Sasaki K, Ishida H, Komatsuda T, Suzuki T, Konno K, Ohtaka M, Sato M, Ishida J, Sakai T, Watanabe S. Appendiceal mucocele: Sonographic findings. *Abdom Imaging* 2003; 28:15-8
4. Stocchi L, Wolff BG, Larson DR, Harrington JR. Surgical treatment of appendiceal mucocele. *Arch Surg* 2003; 138: 585-9
5. Pitiakoudis M, Argyropoulou PI, Tsaroucha AK, Prassopoulos P, Simopoulos C. Cystadenocarcinoma of the appendix: an incidental imaging finding in a patient with adenocarcinomas of the ascending and the sigmoid colon. *BMC Gastroenterol* 2003;3:30.
6. Nitecki SS, Wolff BG, Schlinkert R, Sarr MG. The natural history of surgically treated primary adenocarcinoma of the appendix. *Ann Surg* 1994; 219:51-7.

**Author Information**

**Mehmet Yasar**

Assistant MD of General surgery, Duzce Medical Faculty, Abant Izzet Baysal University

**Arif Aslaner**

Assistant MD of General surgery, Duzce Medical Faculty, Abant Izzet Baysal University

**Ahmet Zengin**

Assistant MD of General surgery, Duzce Medical Faculty, Abant Izzet Baysal University