

# Parkinsonism after Shunting for Hydrocephalus Secondary to Aqueductal Stenosis with Chiari Malformation

M Turgut

## Citation

M Turgut. *Parkinsonism after Shunting for Hydrocephalus Secondary to Aqueductal Stenosis with Chiari Malformation*. The Internet Journal of Neurosurgery. 2008 Volume 6 Number 2.

## Abstract

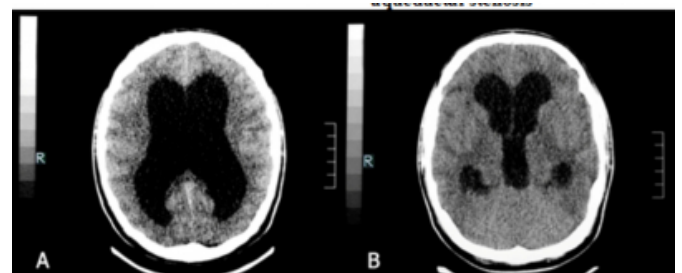
Parkinsonism has been well-documented in patients with communicating hydrocephalus, but it is an uncommon complication of shunting for obstructive hydrocephalus secondary to aqueductal stenosis. Although a number of hypotheses regarding anatomical and pathophysiological clues to this are proposed, its exact mechanism remains unclear. The author presents a unique case of parkinsonism after shunting for hydrocephalus due to aqueductal stenosis with Chiari malformation. Suboccipital craniectomy and duraplasty followed by ventriculoperitoneal shunting was performed, parkinsonian symptoms developed after the shunt revision, and short-term levodopa therapy resulted in complete recovery.

## CASE REPORT

This 25-year-old man had a history of progressive headache during eight years before admission. He was admitted with increment in his headaches, drowsiness and vomiting with visual troubles; in the emergency room he was intubated because of development of loss of consciousness and bradycardia. Computerized tomography (CT) demonstrated obstructive hydrocephalus with a marked enlargement of lateral and 3rd ventricles (Figure 1). An external ventricular drainage (EVD) catheter was inserted to decrease the intracranial pressure. Magnetic resonance imaging (MRI) showed hydrocephalus associated with aqueductal stenosis, in addition to a hydromyelia extending from C2 to C5 level and tonsillar herniation confirming diagnosis of Chiari malformation type 1 (CM-1) (Figure 2). Following the removal of the EVD catheter, a suboccipital craniectomy and C1 laminectomy was performed. Intraoperative ultrasonography (US) revealed "pistoning" movement of the tonsils during systole-diastole pulsations. The dura mater was incised, the herniated tonsils were separated, and coagulated with achieving a free cerebrospinal fluid. Following duraplasty, valsalva maneuver was performed to ensure that foramen magnum obstruction by further tonsillar descent did not occur.

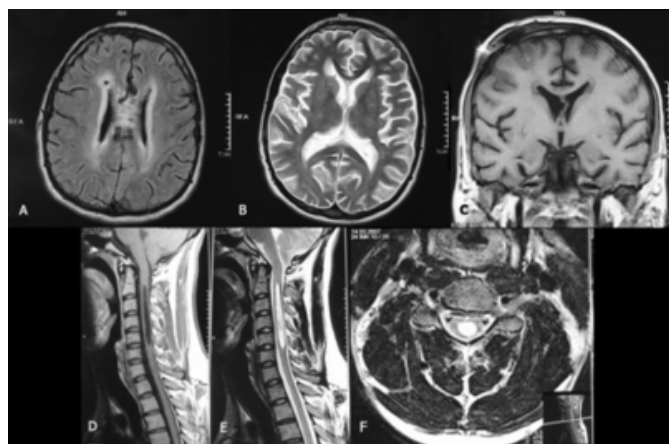
## Figure 1

Figure 1: (A, B) Preoperative CT scan showing triventricular hydrocephalus secondary to aqueductal stenosis



**Figure 2**

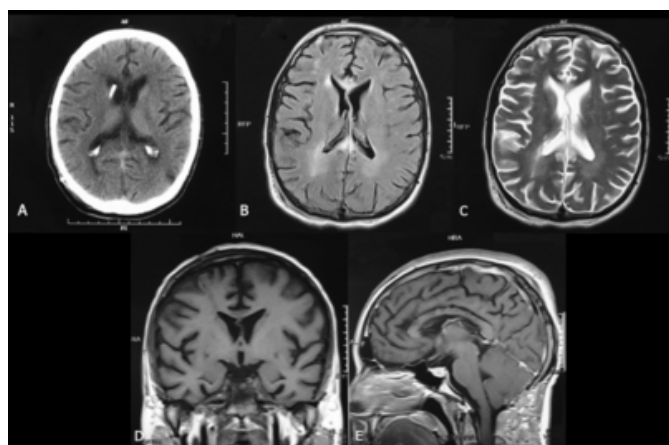
Figure 2: Axial T1- (A) and T2- (B) weighted and coronal (C) T1-weighted MRIs showing ventricular dilatation and periventricular edema. Sagittal T1- (D) and T2- (E) weighted and axial T2-weighted (F) MRIs displaying tonsillar herniation, hydromyelia and brainstem compression



Afterwards, he underwent insertion of ventriculoperitoneal (VP) shunt with medium pressure valve (Medtronic Pudenz-Schulte Medical Co., Goleta, CA) via the anterior horn of the right lateral ventricle. His symptoms disappeared immediately and a recent CT scan confirmed resolution of hydrocephalus, but the shunt was then removed because of its malfunction related with peritonitis. Antibiotic therapy was initiated and EVD was replaced by shunting via the posterior horn of the right lateral ventricle, because culture of the drained material revealed infection with *Staphylococcus aureus*.

**Figure 3**

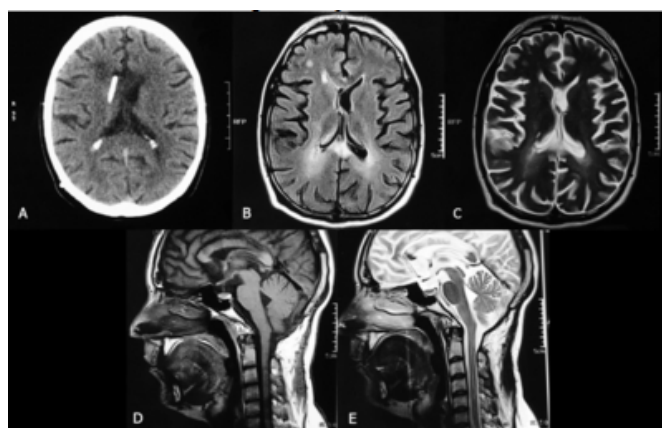
Figure 3: (A) Postoperative CT scan depicting correct position of the catheter tip. Axial T1- (B) and T2- (C) weighted as well as coronal (D) and sagittal (E) T1-weighted MRIs showing regression of hydrocephalus and brainstem compression



Following the shunt revision, he rapidly developed severe parkinsonian symptoms with cogwheel rigidity on the left lower extremity, speech difficulty, incontinence, dysphagia, reduced facial expression, bradykinesia, postural instability, and upward gaze palsy. Pyramidal signs such as hyperreflexia, babinski and clonus were also observed on the left side, but a repeat imaging did not reveal hydrocephalus (Figure 3). The diagnosis of secondary parkinsonism was made and levodopa-carbidopa-entacapone was commenced combined with tizanidine. His symptoms showed a dramatic response to the treatment. Serial radiological examinations during the next 10 months demonstrated normal ventricular size and regression of hydromyelia and the drug discontinued after last control, with no parkinsonism (Figure 4).

**Figure 4**

Figure 4: Follow-up CT (A) and axial T1- (B) and T2- (C) weighted as well as sagittal T1- (D) and T2- (E) weighted MRIs after shunt revision demonstrating regression of hydromyelia and alteration of the signal at the periventricular area



## DISCUSSION

Characteristic clinical features of parkinsonian syndrome are mask-like expression, shuffling gait, rigidity and tremor of the limbs and involuntary pill-rolling movements of the fingers (<sup>1-5</sup>). It may develop in cases with shunt failure during multiple revisions, in addition to those with communicating hydrocephalus (<sup>1</sup>). So far, only several cases of parkinsonism after shunting for obstructive hydrocephalus have been reported (Table 1) (<sup>1-15</sup>). The presented unique patient differs from other reported patients in that he also had a hydromyelia extending from C2 to C5 level and tonsillar herniation, consistent with the diagnosis of CM-1. To the best of my knowledge, this is the first case of parkinsonism after shunting for obstructive hydrocephalus, associated with

CM-1, in the literature.

**Figure 5**

Table 1: Literature review with relevant clinical data ()

Author / year	Age/sex (yrs)	Paranasal sinusitis at onset of parkinsonism	No. of previous shunts & drainages	Associated abnormality	Adjunctive drug prescribed or surgery	Outcome
Lang / 1982 (*)	75M	No	Yes	4	von Willebrand's disease	LD CD and LHM iv
Berge / 1985 (*)	21F	Yes	Yes	3	No	BD 2mg tid plus LD and BS 100/25 bd
Braun & Epstein / 1985 (*)	16F	NA	Yes	1	No	LD
Jankovic / 1986 (*)	14F	Yes	Yes	Nil	No	LD CD 125 tid
Cantini / 1988 (*)	39M	Yes	Yes	1	No	LD CD 125 tid and no PM
Shahar / 1998 (**)	17M	Yes	No	Many	No	LD CD 100/25
Gato / 1990 (**)	28NA	No	Yes	1	No drugs	No antiparkinsonian
Curran & Lang / 1994 (**)	163M	Yes	No	2	No	LD CD 25/100 % tid
	75M	No	Yes	4	von Willebrand's disease	LD CD and LHM iv
	9F	Yes	No	1	No	LD CD and LHM iv resolution of PM
Asamoto / 1998 (*)	18F	Yes	Yes	1	No	LD
Zeidler / 1998 (**)	37M	Yes	No	3	No	BC 3 mg bd plus LD CD 250 qid
	22F	Yes	No	2	No	LD BS 125 tid increased to 250 tid
Ochiai / 2000 (**)	39M	NA	No	3	No	BC and then LD
	32F	NA	No	4	No	BC and then LD
Tokunaga / 2003 (**)	26M	Yes	No	1	No	3rd ventriculostomy with removal of the previous shunt system
Racette / 2004 (*)	44M	Yes	No	3	No	LD CD 1500/375 mg/d
Yomo / 2006 (*)	84M	Yes	No	1	No	LD CD 300-30 mg/d increased to 600/60 mg/d
Kim / 2006 (*)	46F	Yes	No	3	No	LD CD 100/25 tid increased to 1,050 mg/d
Present report	25M	Yes	No	4	CM-1	LD CD-E 50 12.5/200 tid

\*yrs, years; M, male; LD, levodopa; CD, carbidopa; LHM, levamisole hydrochloride; iv, intravenous; F, female; BM, benztropine mesylate; tid, three times daily; d, day; BS, benserazide; bd, twice daily; NA, not available; tid, tablet; PM, parkinsonism; BC, bencloprazine; bd, twice daily; qid, four times daily; CM-1, Chiari malformation type 1; E, entacapone; nas, nasella.

\*\* Out of the cases reported by the authors, one had already been described by same authors previously.<sup>12</sup>

Pathophysiologically, enlargement of the ventricles due to shunt malfunction or rapid subsequent change of ventricle size during revision may cause disruption and ischemia of the periventricular nigrostriatal dopaminergic pathways, resulting with parkinsonism (<sup>1,4,6,9,10,14</sup>). As seen in Table 1, there is a history with multiple shunting revisions for obstructive hydrocephalus in the most cases with parkinsonism (<sup>1,4,6-8,10,11,15</sup>). Pyramidal symptoms probably result from the involvement of corticospinal tract due to ventriculomegaly or overdrainage of the ventricles, but the possibility of surgical injury of the basal ganglia because of the placement of the catheter should also be considered since the findings of parkinsonism are contralateral to the site of catheter.

The availability of MRI has resulted in an increasing number of patients being diagnosed with CM-1 and hydrocephalus secondary to aqueductal stenosis. As did in the case, there are areas of high signal intensity at the levels of the corpus callosum and periventricular white matter on MRI, reflecting the compressive damage inflicted by the hydrocephalus and ischemia; and thus providing an evidence for degeneration of projection fibers in the basal ganglia and thalamus (<sup>2,13</sup>). In cases with CM-1, surgical technique to restore normal cerebrospinal fluid dynamics is a craniovertebral decompression and duraplasty. Intraoperative US may be used to evaluate the need for duraplasty and the adequacy of decompression, as did in the presented case.

Patients with parkinsonism complicating shunt placement for obstructive hydrocephalus frequently demonstrate a marked response to short-term levodopa treatment (<sup>6,8</sup>), but the remaining ones remain levodopa dependent, suggesting transient dopamine deficiency in the nigrostriatal tract due to improvement in blood flow of basal ganglia and midbrain (<sup>1-4,6-10,12-14</sup>). Owing to the rarity of the disease, however, the experience on surgical treatment and adjunctive drugs seems to be very limited.

**ACKNOWLEDGEMENTS**

The author wish to express my sincere thanks to Dr. Ali Akyol for his help in the assessment of the patient.

**References**

- Berger L., Gauthier S., Leblanc R. Akinetic mutism and parkinsonism associated with obstructive hydrocephalus. *Can J Neurol Sci* 1985;12:255–258.
- Cantini R., Ferrito G., Lutzemberger L., et al. Parkinsonian syndrome in the course of aqueductal stenosis hydrocephalus. *Ital J Neurol Sci* 1988;9:603–606.
- Curran T., Lang A.E. Parkinsonian syndrome associated with hydrocephalus: case reports, a review of the literature, and pathophysiological hypotheses. *Mov Disord* 1994;9:508–520.
- Racette B.A., Esper G.J., Antenor J., et al. Pathophysiology of parkinsonism due to hydrocephalus. *J Neurol Neurosurg Psychiatry* 2004;75:1617-1619.
- Lang A.E., Meadows J.C., Parkes J.D., et al. Early onset of the “on-off” phenomenon in children with symptomatic parkinsonism. *J Neurol Neurosurg Psychiatry* 1982;45:823-825.
- Asamoto S., Sugiyama H., Doi H., et al. Levodopa effective parkinsonism associated with aqueductal stenosis: a case report and review of the literature. *No Shinkei Geka* 1998;26:1089–1092.
- Brazin M.E., Epstein L.G. Reversible parkinsonism from shunt failure. *Pediatr Neurol* 1985;1:306–307.
- Jankovic J., Newmark M., Peter P. Parkinsonism and acquired hydrocephalus. *Mov Disord* 1986;1:59–64.
- Kim M.J., Chung S.J., Sung Y.H., et al. Levodopa-responsive parkinsonism associated with hydrocephalus. *Mov Disord* 2006;21:1279-1281.
- Ochiai H., Yamakawa Y., Miyata S., et al. L-dopa effective parkinsonism appeared after shunt revision of the aqueductal stenosis: report of two cases (Jpn). *No To Shinkei* 2000;52:425-429.
- Shahar E., Lambert R., Hwang P.A., et al. Obstructive hydrocephalus-induced parkinsonism. I: Decreased basal ganglia regional blood flow. *Pediatr Neurol* 1998;4:117–119.
- Tokunaga H., Shigeto H., Inamura T., et al. A case of severe parkinsonism induced by failure of ventriculo-peritoneal shunt for aqueductal stenosis (Jpn). *Rinsho Shinkeigaku* 2003;43:427-430.
- Yomo S., Hongo K., Kuroyanagi T., et al. Parkinsonism and midbrain dysfunction after shunt placement for obstructive hydrocephalus. *J Clin Neurosci* 2006;13:373-378.
- Zeidler M., Dorman P.J., Ferguson I.T., et al. Parkinsonism associated with obstructive hydrocephalus due

***Parkinsonism after Shunting for Hydrocephalus Secondary to Aqueductal Stenosis with Chiari Malformation***

---

to idiopathic aqueductal stenosis. J Neurol Neurosurg Psychiatry 1998;64:657-659.

15. Gatto M., Micheli F., Pardo M.F. Blepharoclonus and parkinsonism associated with aqueductal stenosis. Mov Disord 1990;5:310-313.

**Author Information**

**Mehmet Turgut, MD, PhD**

Assistant Professor of Neurosurgery, Department of Neurosurgery, Adnan Menderes University Medical Faculty