

Pulmonary And Central Nervous System Involvement In Juvenile Dermatomyositis: Vasculopathy And/Or Steroids As Causative Agents - A Case Report

A Taranath, C Kah Fook Wong

Citation

A Taranath, C Kah Fook Wong. *Pulmonary And Central Nervous System Involvement In Juvenile Dermatomyositis: Vasculopathy And/Or Steroids As Causative Agents - A Case Report*. The Internet Journal of Radiology. 2004 Volume 4 Number 1.

Abstract

Juvenile dermatomyositis is a rare disorder with very few reports of multi-system involvement. We report a 10-year-old child known to have dermatomyositis who developed a combination of pneumothorax, pneumomediastinum, subcutaneous emphysema and intracerebral haemorrhage. Vasculopathy as a part of the Juvenile dermatomyositis spectrum has been implicated as a cause of many of these complications but reports have also suggested long term cortico-steroid treatment as a possible causative agent.

ABBREVIATIONS

Juvenile dermatomyositis-JDMS,
Creatine Phosphokinase-CK

INTRODUCTION

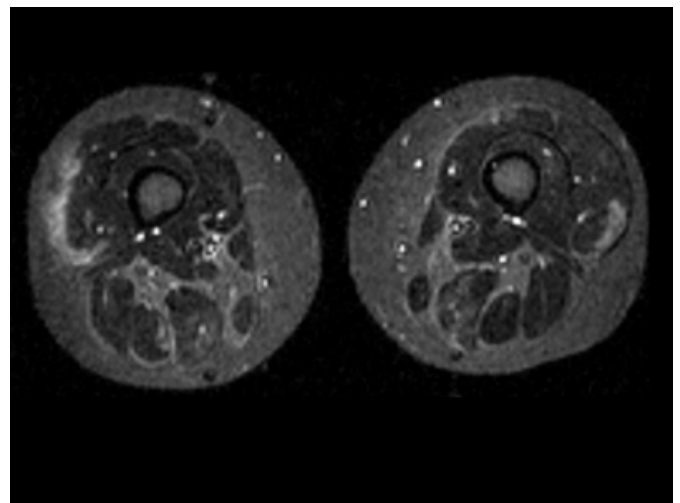
JDMS has an incidence of 1.9/1000000 children under the age of 16 years¹. JDMS is a rare rheumatoid disorder, which typically involves inflammation of the skin and striated muscles. The pathophysiology of JDMS includes muscle lesions with a mix of degeneration and regeneration of muscle fibres and perivascular lymphocytic infiltrates. There is also vasculitis of small arteries, venules, and capillaries of the skin, muscle and GI tract.

CASE REPORT

A 10-year-old girl presented to our hospital with low-grade fever and shortness of breath and dysphagia. She had a history of treatment at a rural hospital for pneumonia of the right lower lobe following cough and fever for three weeks. She was diagnosed in another hospital as suffering from isolated dermatomyositis (Fig 1a&1b) without any overlap with other rheumatological syndromes and was started on long term oral methyl prednisolone. There was no past history of dysphagia or aspiration pneumonitis. It was not possible to obtain the autoantibody profiles.

Figure 1

Figure 1ab: Axial STIR MRI sequence demonstrating inflammatory changes in the thigh muscles.

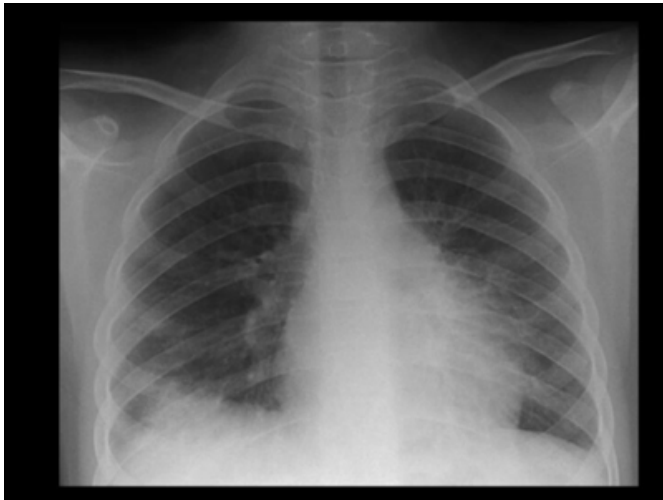


On examination she was found to be dyspnoeic, tachypnoeic, tachycardic and also had rashes that were characteristic of dermatomyositis. Fungal lesions were present in the oral cavity. She was already administered appropriate oral and intravenous antibiotics which were continued, in addition to oxygen to alleviate her dyspnoea.

Chest x ray showed a subpleural triangular focus of consolidation as well as prominent interstitial markings (Fig 2).

Figure 2

Figure 2: Chest X-Ray AP supine showing a right basal subpleural triangular focus of consolidation as well as prominent interstitial markings.

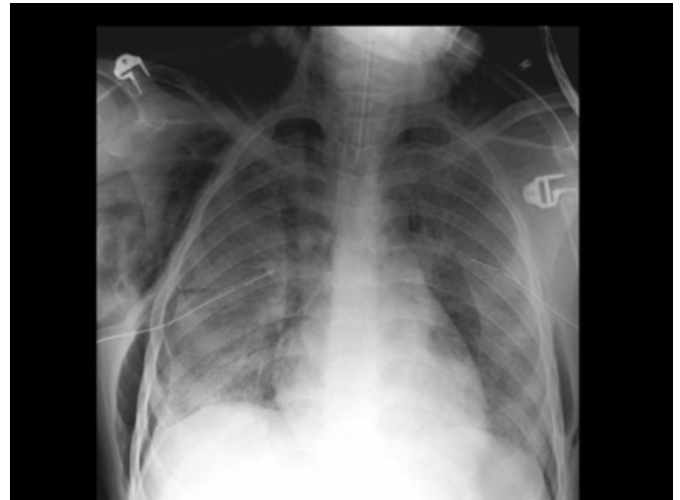


High-resolution ultrasound of the chest ruled out the presence of a pleural effusion. A doppler ultrasound of the renal arteries did not reveal any evidence of renal artery stenosis nor was there any abnormality of the kidneys. Repeated cultures could not identify infectious agents. Clotting disorders were excluded. CK levels were within normal limits. Electrolyte analysis revealed persistent elevation of sodium, bicarbonate and chloride levels, elevated urea and creatinine levels and reduced levels of potassium.

It was not possible to perform a CT scan in view of her clinical situation. Progress chest x-rays over the next few days showed the presence of right sided pneumothorax, pneumomediastinum and subcutaneous emphysema in the chest wall extending towards the face (Fig 3).

Figure 3

Figure 3: Progress chest X-Ray AP supine showing frank right sided pneumothorax, pneumomediastinum and subcutaneous emphysema.



She was then transferred to the intensive care unit where a steady rise in her blood pressure was noted. A few days later she was referred for an urgent CT scan for a sudden increase in blood pressure, dilated non-reactive pupils and an absence of response to external stimuli. The CT scan showed multiple foci of haemorrhage in the supra and infratentorial neuroparenchyma, with the largest focus located in the right internal capsule and basal ganglia. There was associated effacement of the right lateral ventricle, midline shift to the left, uncal and descending transtentorial herniations. There was generalised cerebral oedema (Figs 4a&4b). She succumbed to the disease a few days later. A formal autopsy was not done.

Figure 4

Figure 4: CT head showing multiple foci of haemorrhage in the supratentorial neuroparenchyma, with the largest focus located in the right internal capsule and basal ganglia. Note effaced right lateral ventricle and midline shift to left.

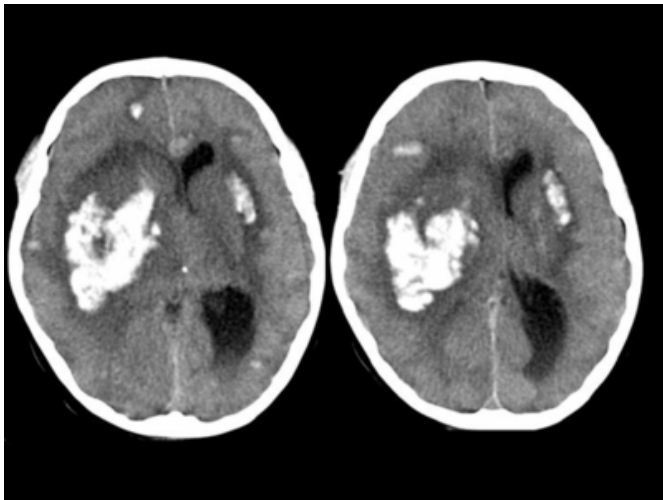
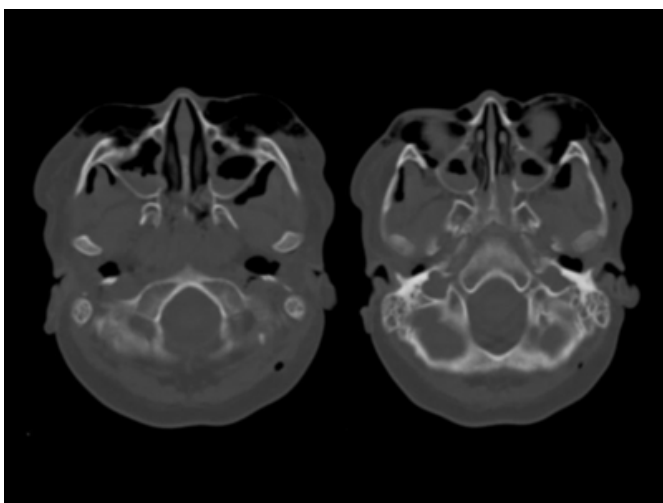


Figure 5

Figure 5: CT head with windows appropriate for bony structures revealing the extent of the subcutaneous emphysema.



DISCUSSION

JDMS is an inflammatory myopathy of unknown origin in which the immune system targets the microvasculature of the skeletal muscles and the skin leading to proximal muscle weakness, and a typical rash involving the face and hands. The vasculopathy/vasculitis can also involve the gastro-intestinal tract, lungs, subcutaneous tissues, eyes and the heart². Severe vasculopathy and high initial CK levels are associated with a unfavourable prognosis².

JDMS is a rare disorder affecting children under 15 years of age. It has varied manifestations involving multiple organ systems. Pulmonary, cardiovascular and gastro-intestinal complications are well known, but the neurological complications are less frequent¹. Pulmonary and neurological complications of juvenile dermatomyositis have not been previously illustrated in a single case.

Pulmonary involvement in juvenile dermatomyositis is predominantly interstitial and has been described in literature to precede the muscular or skin manifestations³. Subpleural consolidation was found to be the most common form of interstitial involvement in JDMS³. Interstitial fibrosis is believed to cause degeneration of the alveolar walls leading to cyst formation, rupture of the cyst and pneumothorax¹. Besides interstitial fibrosis, vasculitis and infarction are other possible mechanisms of pneumothorax in DM⁴. Yamanishi et al suggest that the steroids can weaken the interstitial tissues of the lungs and this might result in pneumomediastinum⁵. Other risk factors for pneumomediastinum include interstitial lung disease, cutaneous vasculopathy, mild or absent CK elevation, young age and steroid treatment⁶.

Neurological involvement in JDM has been reported to present with peripheral or central manifestations. Peripheral neurological involvement in JDMS has been reported more as a neuropathy although the existence of a true neuromyositis is controversial.

Central nervous system complications in JDMS can be due to a vasculopathy as a part of the JDMS spectrum or due to true cerebral vasculitis of small to medium sized vessels, hypoxic-ischaemic encephalopathy secondary to cerebral hypoperfusion or hypertensive encephalopathy due to drug treatment. Corticosteroids have been implicated as a likely cause of hypertensive encephalopathy because of intracerebral fluid shifts, associated hypertension or electrolyte abnormalities¹.

Our patient with JDMS had a few erythematous rashes that were typical of dermatomyositis. There were no other cutaneous or systemic indicators of vasculopathy. There was a subpleural focus of consolidation and prominence of interstitial markings at admission, developed pneumothorax, pneumomediastinum and subcutaneous emphysema a few days later. Hypertension and electrolyte abnormalities were identified which might have been due to the long term methyl prednisolone therapy.

We have reported an uncommon case of a child with JDMS with pulmonary and central nervous system involvement. We would like to conclude that although the complications seen in this child could be the result of vasculopathy, long term cortico-steroids as a part of the treatment spectrum might have played a complementary role.

References

1. Ramanan A.V, Sawhney S, Murray K.J (2001) Central nervous system complications in juvenile onset dermatomyositis. *Rheumatology*.40:1293-1298.
2. Elst E.F, Kamphuis S.S.M, Prakken B.J (2003 Sep) Severe central nervous system involvement in Juvenile Dermatomyositis. *Journal of Rheumatology*.30 (9): 2059-2063.
3. Masanoki A, Hara H, Sakatani M (1999 Feb) Interstitial lung disease in association with polymyositis - Dermatomyositis:Long-term follow-up CT evaluation in seven patients. *Radiology*. 210(2):333-338
4. Masaaki S, Bando T, Hasegawa S et al.(2000 Nov) Recurrent spontaneous pneumothoraces associated with juvenile polymyositis. *Chest*: 118(5):1509-11.
5. Yamanishi Y, Maeda H, Konishi F et al.(1999) Dermatomyositis associated with rapidly progressive fatal interstitial pneumonitis and pneumomediastinum. *Scand J Rheumatol* 28:58-61.
6. Korkmaz C, Ozkan R, Akay M et al (2001 Apr) Pneumomediastinum and subcutaneous emphysema associated with dermatomyositis. *Rheumatology (Oxford)*. 40(4):476-8.

Author Information

Ajay Taranath, MBBS, MD

Department of Medical Imaging, The Children's hospital at Westmead

Christopher Kah Fook Wong, MBBS, FRANZCR

Director of Medical Imaging, The Children's hospital at Westmead