

## Interesting Cases In Gastroenterology

O Wenker, L Moehn, S Lahoti

### Citation

O Wenker, L Moehn, S Lahoti. *Interesting Cases In Gastroenterology*. The Internet Journal of Gastroenterology. 1999 Volume 1 Number 1.

### Abstract

#### CASE REPORT

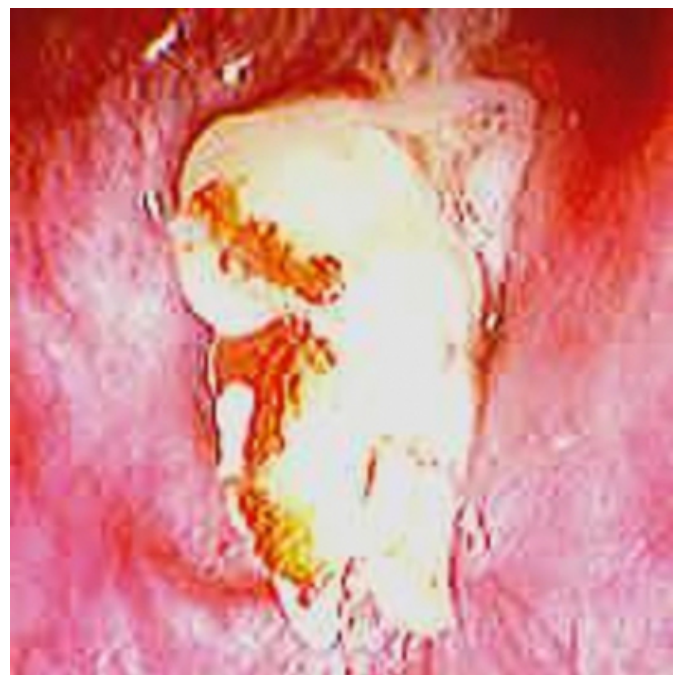
An 80-year-old patient presents in the emergency room with sore throat and difficulties to swallow. He had a history of esophageal cancer treated with surgery and radiation therapy. He spent the afternoon with friends at an open-air party "Cajun-style". He is known to have an esophageal stricture for which he underwent several dilatation procedures in the past.

At examination we found a patient with difficulties to swallow his saliva. He did not show any signs of cardiopulmonary distress or hemodynamic instability. It was decided to perform an esophagoscopy with the flexible endoscope under monitored anesthesia care MAC. Please check <http://www.ispub.com/journals/IJH/Vol1N1/mac.html> for more detailed information on MAC.

#### RESULTS

#### Figure 1

The esophagoscopy revealed this image:



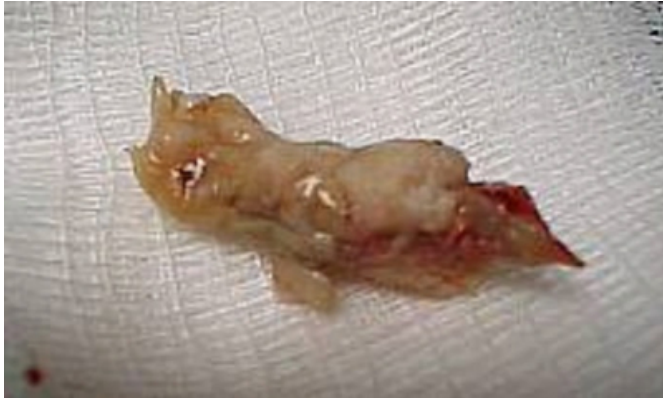Question: What does this picture show ?

#### ANSWER

A crawfish was stuck in the esophagus. The patient was known to have an esophageal stricture and had to chew the food real well before swallowing it. He was invited to a Cajun crawfish party and forgot to wear his dentures. He swallowed the crawfish and it got stuck and had to be removed under MAC the same night.

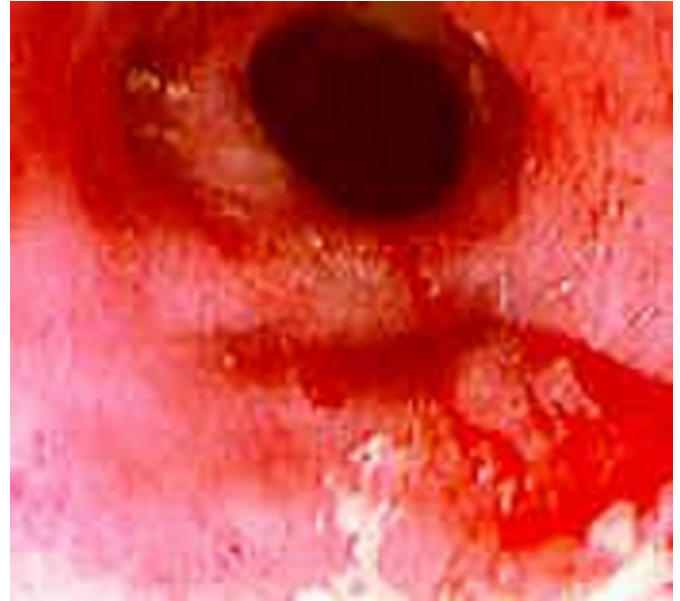
**Figure 2**

Image 2: The culprit crawfish removed from the esophagus



**Figure 3**

Image 3: Patent esophagus after removal of crawfish.



**CONCLUSION**

The patient was advised to use his dentures in the future. 😊

**References**

**Author Information**

**Olivier C. Wenker, M.D.**

Associate Professor of Anesthesiology and Critical Care, Department of Anesthesiology, Critical and Palliative Care, MD Anderson Cancer Center, The University of Texas

**Larry Moehn, CRNA**

Department of Anesthesiology, Critical and Palliative Care, MD Anderson Cancer Center, The University of Texas

**Sandeep Lahoti, M.D.**

Assistant Professor of Medicine, Director of Endoscopy, Department of Gastrointestinal Medical Oncology & Digestive Diseases, MD Anderson Cancer Center, The University of Texas