

Shortness of Breath in an Obese Young Man

C Boos, P Flies, M Dawes, G Matfin

Citation

C Boos, P Flies, M Dawes, G Matfin. *Shortness of Breath in an Obese Young Man*. The Internet Journal of Academic Physician Assistants. 2002 Volume 3 Number 2.

Abstract

Malignant Hypertension is a rare but preventable cause of death. In this article we present a short report on a case of malignant hypertension presenting with heart failure in a 37-year-old male. The swift response to therapy in this case highlights the improved outlook for this condition with currently available medical therapy. The treatment and epidemiology of this condition is further discussed.

CASE REPORT

A 37-year-old man presented with a 10-day history of chest pain, increasing breathlessness and ankle swelling. He had an 18-month history of cough and breathlessness. He had been managed on several occasions during this period with oral antibiotic therapy for presumed respiratory tract infection. He had a 20-pack year history of smoking but drank no alcohol and took no recreational drugs. He had no obvious symptoms related to sleep apnoea. On registration with his general practitioner, 9 years prior, his blood pressure was 145/90 mmHg, however no further blood pressure recordings had been undertaken.

Clinical examination revealed an obese man (body mass index, 39), who was pale, sweaty and clearly unwell. He appeared to be fully orientated, with a resting sinus tachycardia of 100/min. His blood pressure was 205/125 mmHg, seated, using a large cuff and equal in both arms. Jugular venous pressure was elevated to 6 cm with a 3rd heart sound, but there were no cardiac murmurs or peripheral bruits. He was tachypnoeic with a respiratory rate of 32 breaths/min and had bilateral basal lung crepitations with pitting peripheral oedema to his knees. Fundoscopy was performed (fig 1). Urine dipstick was normal.

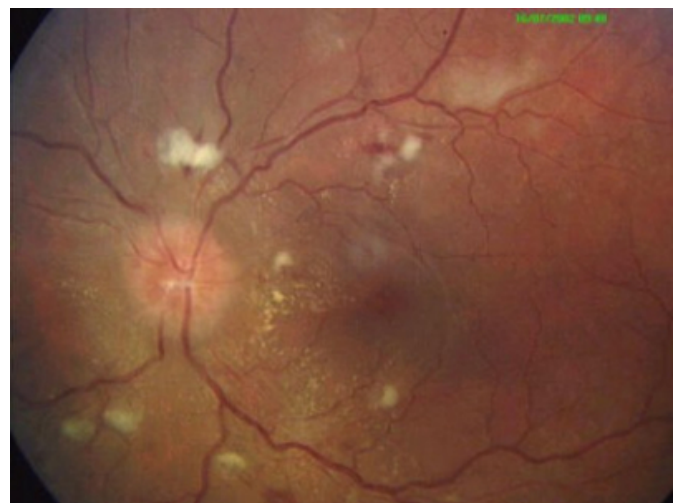A 12 lead electrocardiogram (fig 2) and chest x-ray (fig 3) were undertaken. Other baseline tests were unremarkable, except for evidence of mild renal impairment: urea 12.3mmol/L (normal 3.0-7.6 mmol/L) and creatinine 137 mol/L (normal 60-120 μ mol/L).

QUESTIONS

1. What is shown on fundoscopy (Fig 1)?

Figure 1

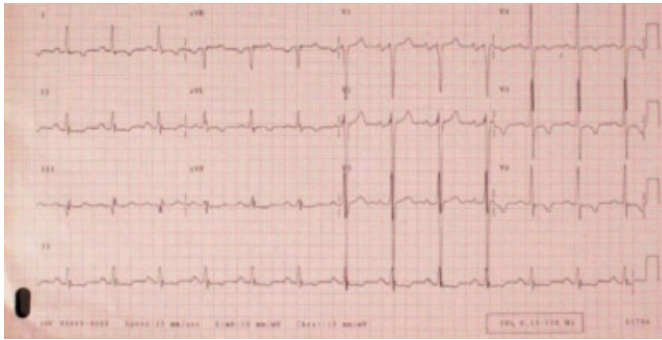
Figure 1: Fundoscopy revealing grade IV hypertensive retinopathy (Keith-Wagener-Barker Classification) as evidenced by papilloedema with grade III changes: cotton wool spots, hard exudates (macular starring), and flame haemorrhages



2. Describe the changes on the ECG (Fig 2) and what are these features consistent with?

Figure 2

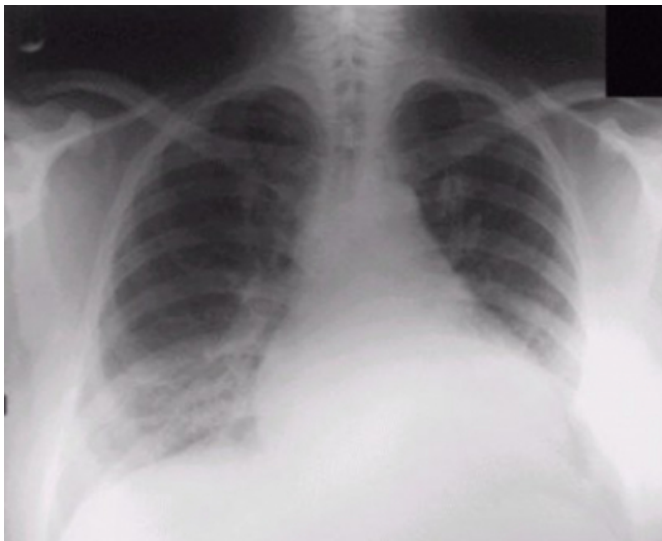
Figure 2: 12 lead electrocardiogram showing voltage criteria of left ventricular hypertrophy with the classic 'strain pattern' in the lateral leads.



3. What is seen on the CXR (Fig 3)?

Figure 3

Figure 3: Chest radiograph on admission showing acute pulmonary oedema.



4. What is the likely underlying diagnosis in this patient and which other investigations may be warranted?

SELF ASSESSMENT ANSWERS

1. What is shown on fundoscopy (Fig 1)?

Fundoscopy reveals silver wiring, AV nipping, cotton wool spots, hard exudates (macular starring), flame haemorrhages, and papilloedema. These changes are consistent with Grade IV hypertensive retinopathy (Keith-Wagener-Barker Classification) as evidenced by grade III changes and papilloedema.¹

2. Describe the changes on the ECG (Fig 2) and what are these features consistent with?

ECG showed sinus rhythm with evidence of left ventricular hypertrophy. This is supported by the following: the sum of S wave in V1 + R in V5 or V6 > 35 mm, left axis deviation, SV3 + R avL > 28 mm, a widening of the QRS width, and ST depression and T wave inversion in the lateral leads (strain pattern).^{2,3,4}

3. What is seen on the CXR (Fig 3)?

His chest x-ray showed cardiomegaly (cardiothoracic ratio 18/31 cm), upper lobe blood diversion, Kerley B lines and a small left pleural effusion, in keeping with acute pulmonary oedema.

4. What is the likely underlying diagnosis in this patient and which other investigations may be warranted?

He was diagnosed with hypertensive heart failure and was commenced on intravenous frusemide and a nitrate infusion. He had mild renal impairment as evidenced by a plasma urea of 12.3mmol/L (normal 3.0-7.6 mmol/L); creatinine 137 mol/L (normal 60-120 µmol/L). Sodium and potassium concentrations were normal. His full blood count, thyroid function, plasma glucose, cholesterol (3.85mmol/L), and cardiac enzymes (including cardiac troponin I) were normal.

Investigations for secondary causes of hypertension including renal ultrasound, serum aldosterone and renin activity, urine drug abuse screen, 24-hour urinary catecholamines and cortisol levels were all normal. Transthoracic echocardiography revealed a globally dilated heart with poor global systolic function, moderate concentric left ventricular hypertrophy.

In addition he was treated orally with nifedipine slow release and later, during his inpatient stay, he was cautiously commenced on an angiotensin converting enzyme inhibitor and a beta-blocker. His blood pressure on discharge (day 9) was 145/95mmHg, and he had a normal renal profile at 6 weeks post discharge. Blood pressure at 2 months post discharge was 125/85.

DISCUSSION

MH is a clinical syndrome of elevated blood pressure with other features including retinopathy, pulmonary oedema and left ventricular dysfunction, and renal impairment, all of which were observed in this patient. It is a rare but preventable and treatable cause of death. Anti-hypertensive therapy has markedly improved prognosis and increased the five-year survival from 0% (untreated) to 75%.⁵

Heart failure is the commonest presenting complication of MH.⁵ However, there can be difficulty with prompt diagnosis as hypertension is frequently asymptomatic and mild heart failure, at least, can present non-specifically. The mean age of presentation is 50.1³ years with a sex-ratio of male: female of 1.5-2:1.^{6,7,8} Most patients with MH have chronic poorly treated essential hypertension however the disorder can present rapidly in previously normotensive individuals.⁹

Current indicators of poor prognosis include patients with proteinuria and high serum urea (10 mmol/L), creatinine (>200µmol/L), and patients with ECG evidence of left ventricular hypertrophy.⁷ The use of the short acting form of the calcium channel blocker nifedipine is associated with significant morbidity and should be avoided.¹⁰

On admission, the patient was commenced on intravenous frusemide and a nitrate infusion. His blood pressure on discharge (day 9) was 145/95mmHg, and he had a normal renal profile at 6 weeks post discharge. Blood pressure at 2 months post discharge was 125/85.

The patient described had been symptomatic with breathlessness for 18 months prior to admission to hospital. Breathlessness is a common symptom with many causes. Heart failure, especially in the early stages, can be difficult to diagnose clinically, but effective treatments are available and should be instituted promptly. This case highlights that the early assessment of a breathless patient should include a full cardiovascular examination, ECG and chest X-ray in

order to find treatable underlying causes.

CORRESPONDENCE TO

Dr Christopher Boos, 18C Nightingale Rd, Southsea, Portsmouth, Hampshire, UK, PO5 3JL E-mail: christopherboos@hotmail.com Telephone 02392 355 919 (H) 07973 840 309 (M)

References

1. Keith NM, Wagener HP, Barker Newsome different types of essential hypertension: their course and prognosis. *Am J Med Sci* 1974;268:336-45.
2. Sokolow M, Lyon P. The ventricular complex in left ventricular hypertrophy as obtained by unipolar precordial and limb leads. *Am J Cardiol* 1949;37:161-168.
3. Molloy TJ, Okin PM, Devereux RB, Kligfield P. Electrocardiographic detection of left ventricular hypertrophy by the simple QRS voltage-duration product. *J Am Coll Cardiol* 1992;20:1180-6.
4. Casale PN, Devereux RB, Alonso DR, Campo E, Kligfield P. Improved sex-specific criteria of left ventricular hypertrophy for clinical and computer interpretation of electrocardiograms: validation with autopsy findings. *Circulation* 1987;75:565-72.
5. Hansson L. Analysis of treatment outcomes. Why is benefit not larger? *Clin Exp Hypertens* 1989;11:753-60.
6. Lip GY, Beevers M, Beevers G. The failure of malignant hypertension to decline: a survey of 24 years experience in a multiracial population in England. *J Hypertens* 1994;12:1297-310.
7. Lip GY, Beevers M, Beevers DG. Complications and survival of 315 patients with malignant-phase hypertension. *J Hypertens* 1995; 13:915-24.
8. TA, Lovell Hg. Accelerated hypertension - patterns of mortality and clinical factors affecting outcome in treated patients. *Q J Med* 1993;868:485-93.
9. Vaughan CJ, Delanty N. Hypertensive emergencies. *Lancet* 2000;356:1442-1443.
10. Varon J, Marik PE. The diagnosis and management of hypertensive crises. *Chest* 2000;119:316.

Author Information

Christopher J. Boos, MRCP (UK)

Department of Cardiology, Portsmouth Hospitals NHS Trust

Peter Flies, MD

Department of Cardiology, Portsmouth Hospitals NHS Trust

Matthew Dawes, MRCP (UK)

Department of Cardiology, Portsmouth Hospitals NHS Trust

Glenn Matfin, BSc (Hons), MB ChB, DGM, MFPM, RCP(UK), FACE, FACP

Adjunct Attending Physician, Joslin Diabetes Clinic