

# Intestinal Malrotation In A 13 Year-Old Boy With Catastrophic Consequence: Case Report

E López-Tomassetti Fernández, N Hernandez Siverio, I Arteaga González

## Citation

E López-Tomassetti Fernández, N Hernandez Siverio, I Arteaga González. *Intestinal Malrotation In A 13 Year-Old Boy With Catastrophic Consequence: Case Report*. The Internet Journal of Pediatrics and Neonatology. 2005 Volume 6 Number 1.

## Abstract

Intestinal transplantation has recently become an accepted therapy for selected patients with irreversible intestinal failure. A non-reconstructible gastrointestinal tract is also an indication for consideration of intestinal transplantation. We present the case of a 13-year-old boy who lost his entire small bowel and right colon after an acute mesenteric volvulus due to a congenital intestinal malrotation. In these cases, survival using total parenteral nutrition and early referral to an intestine transplant center is possible. However, results in terms of long-term patient and graft survival are still not comparable to those of other single abdominal-organ transplantations.

## CASE REPORT

A 13-year-old boy without previous medical history presented to the emergency room with a 24-hours history of bilious vomits and severe abdominal pain. He had been complaining of intermittent abdominal pain for the last 2 weeks and treated with benzodiazepine medications.

Physical examination showed an agitated and pale boy with severe abdominal distension. He was febrile and nauseous and evidence of shock was present.

Blood tests showed leucocytosis ( $14 \times 10^9/L$ ), increased C-reactive protein, and electrolytes disbalance with hypopotasemia.

CT-scan revealed important dilated bowel loops with air fluid levels (figure 1), free fluid and pneumomediastinum.

Suspecting appendicitis, we decided to explore the child surgically after parents were correctly informed.

During surgical intervention unexpected massive intestinal ischemic damage from the first part of jejunum to transverse colon was observed. We found that the child had a torsion of entire gut around superior mesenteric artery (figure 2) due to a short mesenteric attachment of small intestine secondary to congenital anomaly: intestinal malrotation.

We decided to resect the ischemic colon and the ischemically damaged small intestine was repositioned in the abdominal cavity for reperfusion. Incision was then closed

with a polytetrafluoroethylene mesh.

At the Pediatric intensive care unit, the boy required inotropic support to maintain perfusion of critical organs. 24-hours later a second look laparotomy was performed. To our surprise, we found massive intestinal necrosis of the entire small intestine (figure 2). At this time, parents were correctly informed that only possibility for survival consisted on near-total resection of the small intestine and early referral to a small bowel transplant center with the potential adverse consequences of new transplantation program world-wide. Once this drastic decision was accepted by the parents and specialist, the small bowel was resected just distal to the duodenum, leaving only 5-cm of jejunum and the left colon in the abdomen. After resection, a duodenostomy was made and the abdomen was closed. Some hours later, the boy slowly recover from septic shock and 48 hours later he was extubated and started total parenteral nutrition. He was placed on the transplant waiting list in August 2005.

## DISCUSSION

Malrotation of the intestine results when the normal embryologic sequence of bowel development and fixation is interrupted. Malrotation predisposes patients to two problems: midgut volvulus and small bowel obstruction.

There are some catastrophic reports in the English literature similar to our case. In most cases, a length of viable small intestine was sufficient to survive. In ours, the child lost the

entire intestine and no anastomosis could be performed. His possibilities to survive were total parenteral nutrition (with high risk for liver failure and recurrent line infections) [1,2] and referral to intestinal transplantation centre.

The intestine is more difficult to transplant than other solid organs due to its strong expression of histocompatibility antigens, large numbers of resident leukocytes, and colonization with microorganisms. Early efforts to transplant the small bowel failed due to refractory graft rejection and sepsis. Outcomes improved during the early 1990s, but survival rates are still inferior to other organ transplants.

Early referral and listing are important for successful outcomes. One year patient survival rates of more than 80% (comparable to those after liver transplantation) are being achieved using antibody-based pretreatment/induction therapy and tacrolimus-based maintenance immunosuppression [2,3,4]. Most intestine recipients (90%) who survived stop parenteral nutrition, resume oral nutrition, and return to normal daily activities improving their quality of life [1].

In Spain, morbidity and mortality for intestinal transplantation is considered high. A severe problem in our country is the scarcity of suitable donors for the very low weight children (median 6,4 kg) who are candidates for transplantation [5]. It should not be a problem to find a donor intestine for a 13-year old boy; hence early transplantation is expected in the present case.

### Figure 1

Figure 1: Whirl-like arrangement at the point of superior mesenteric artery torsion.

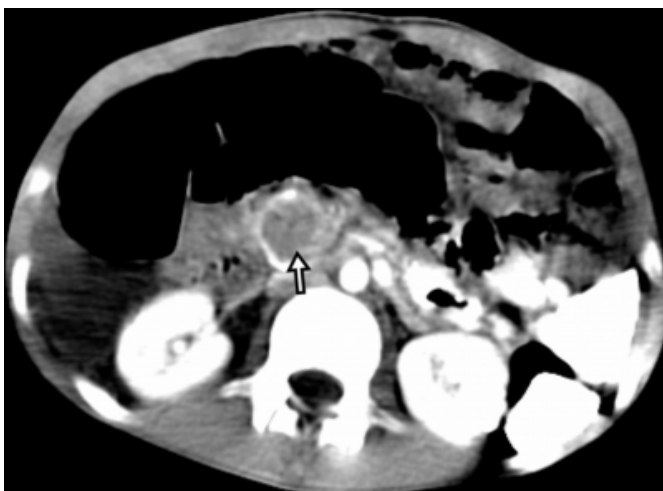
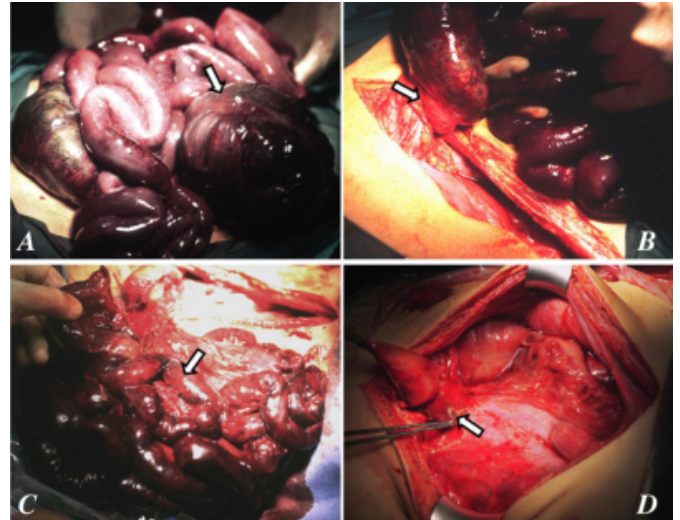


Figure 2. (a) First laparotomy findings: right colon necrosis

(arrow) and intestinal ischemia; (b) Point of torsion of the entire gut (arrow) due to loose mesenteric attachment; (c) Resection of necrotic bowel during second intervention; (d) Arrow indicates the origin of superior mesenteric artery and the duodenum is being held by a hemostat. The entire small bowel has been extracted.



### References

1. Brook G. Quality of life issues: parenteral nutrition to small bowel transplantation-a review. *Nutrition* 1998;14:813-6.
2. Grant D, Abu-Elmagd K, Reyes J, Tzakis A, Langanas A, et al; on behalf of the Intestine Transplant Registry. 2003 report of the intestine transplant registry: a new era has dawned. *Ann Surg* 2005;241:607-13.
3. Mueller AR, Pascher A, Platz KP, Braun F, Fandrich F, et al. Immunosuppression following intestinal transplantation. *Transplant Proc* 2004;36:325-8.
4. Kato T, Ruiz P, Thompson JF, Eskind LB, Wepler D, et al. Intestinal and multivisceral transplantation. *World J Surg* 2002;26:226-37.
5. Lopez-Santamaria M, Gamez M, Murcia M, Leal N, Hernandez F, et al. Pediatric intestinal transplantation. *Transplant Proc* 2003;35:1927-8.

**Author Information**

**Eudaldo M. López-Tomassetti Fernández, M.D.**

Department of Gastrointestinal Surgery, University Hospital in Tenerife

**Norberto Hernandez Siverio, M.D., Ph.D.**

Department of pediatric surgery, University Hospital in Tenerife

**Iván Arteaga González**

Department of Gastrointestinal Surgery, University Hospital in Tenerife