

Recurrent Obstructive Sleep Apnea due to Compensatory Hypertrophy of Lingual Tonsils following UPPP

M Enoz, J Lapeña

Citation

M Enoz, J Lapeña. *Recurrent Obstructive Sleep Apnea due to Compensatory Hypertrophy of Lingual Tonsils following UPPP*. The Internet Journal of Otorhinolaryngology. 2007 Volume 7 Number 2.

Abstract

The lingual tonsils comprise the lymphoid tissue located in the base of the tongue between the circumvallate papilla anteriorly and the epiglottis posteriorly. Lingual tonsil hypertrophy (LTH) may cause OSA or upper airway obstruction, but may only be associated with mild symptoms such as sore throat, globus sensation, speech change or dysphagia (1, 2). However, LTH is a potential cause of unanticipated airway obstruction following induction of general anesthesia (1, 2). We report a case of recurrent obstructive sleep apnea due to compensatory LTH following UPPP (uvulopalatopharyngoplasty).

INTRODUCTION

Differing from the other oropharyngeal lymphoid tissue by location only, the lingual tonsils are subject to the same pathology and produce many of the same symptoms when diseased or enlarged (2). Acute lingual tonsillitis usually resolves with antibiotics. However, chronic infection or symptoms attributed to LTH may require surgical intervention (3).

LTH may cause partial or complete obstruction of the retrolingual airway. Two-thirds of patients with LTH have a history of previous palatine tonsillectomy (3, 4). This may result in LTH, probably as a compensatory mechanism due to loss of palatine tonsils (4). LTH most often occurs in adults, especially in atopic individuals, but has also been reported in children (5).

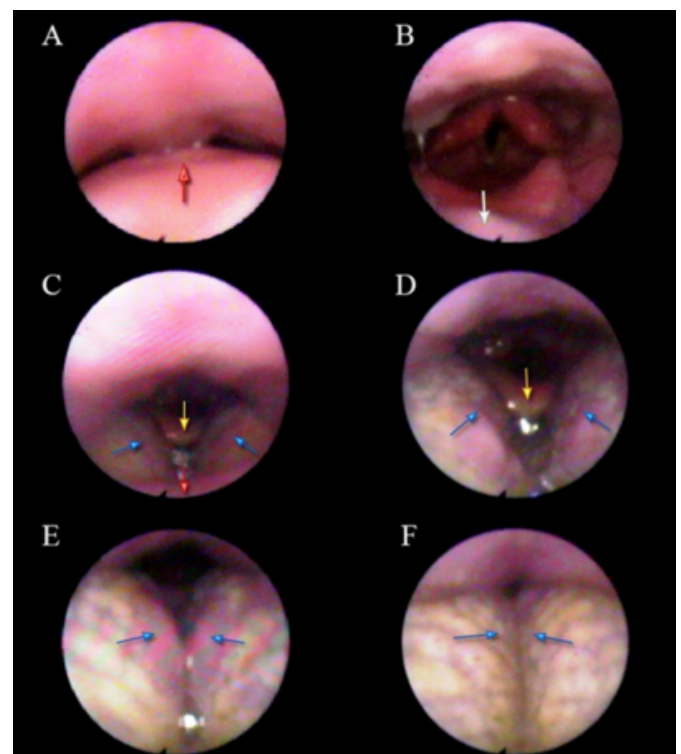
CASE REPORT

A 45-year old female was referred to our clinic for evaluation of snoring and apnea attacks. She was a non-smoker with no atopic or systemic disease and an uneventful past medical history. Preoperative fiberoptic nasopharyngoscopy showed retropalatal airway obstruction by the soft palate and uvula (Figure 1 A, B). Tonsil score was Grade II. Preoperatively apnea hypopnea index (AHI) was 19/h, BMI (body mass index) was 28. UPPP was performed with relief of her symptoms. AHI was 8/h and BMI was 28 at the postoperative sixth month. Three years later, she was readmitted to our clinic for snoring and nocturnal choking over the last four months. AHI was 14/h,

BMI was 27. Fiberoptic nasopharyngoscopy revealed a normal retropalatal area with hypertrophic and hyperflexible lingual tonsils obstructing the airway (Figure 1 C-E).

Figure 1

Figure 1: Preoperative (A, B) and postoperative (C-E) at third year flexible nasopharyngoscopy photos.



A: Soft palate (white arrow) is obstructing the retropalatal airway.

B: The rest of the airway was normal. The posterior surface of uvula (double white arrow) is showing.

C: Lingual tonsils (black arrows), epiglottis (double black arrow) and soft palate (white arrow) are seen and retropalatal area is normal.

D: Lingual tonsils (black arrows) are starting to obstruct the airway. Epiglottis (double black arrow) is seen.

E: Lingual tonsils (black arrows) are continuing the obstructing the airway.

F: Lingual tonsils (black arrows) are obstructing the airway completely. Epiglottis is not shown (capture from flexible fiberoptic nasopharyngoscopy).

Lingual tonsillectomy/ tongue base reduction with radiofrequency was recommended, but the patient has not consented.

DISCUSSION

Waldeyer's ring of lymphatic tissue includes the lingual, pharyngeal, palatine, tubal tonsils, lateral pharyngeal bands and pharyngeal granulations, and lymphoid tissue (2, 5). Unlike palatine tonsils, lingual tonsils have no definite capsule.

Tracheal intubation and face mask ventilation may be difficult in patients with lingual tonsillar hypertrophy (2,5). Jones and Cohle (6) reported a death after failed tracheal intubation and failed ventilation of a patient with unnoticed marked LTH in whom the only apparent symptom was a 'nasal' voice. Continuous intubation and/or laryngeal mask airway insertion attempts can also result in lingual tonsil swelling or bleeding (4).

Marked lingual tonsil hyperplasia has also been reported in allergic patients (7) and in a pediatric patient with Down syndrome (8). The etiology of LTH is commonly unknown, but the patient often has a past history of palatine tonsillectomy (4).

In our case, compensatory LTH occurred following a UPPP operation. This technique included tonsillectomy together with excising the anterior aspect of the uvula, posterior aspect of the soft palate and the redundant lateral pharyngeal wall mucosa (9).

Diagnosis of lingual tonsil hypertrophy in patients with OSA requires careful examination by advanced technologic methods. Flexible endoscopy allows examination of the

nose, all portions of the pharynx and larynx as well as performing of dynamic tests (9).

Treatment of LTH is mainly conservative. Avoidance of exposure to tobacco smoke, dust or chemical irritants may reduce symptoms (2). Surgery is usually not indicated unless there is symptomatic airway obstruction (2, 10). If symptoms persist or airway obstruction occurs, surgical treatment by excision, electrocautery, cryotonsillectomy or carbon-dioxide laser surgery, may be required (2, 10). The carbon-dioxide laser induces minimal thermal damage to surrounding tissue and provides good hemostasis for small vessels (11).

To our knowledge, there is no report of UPPP failure due to compensatory hypertrophy of lingual tonsils in the literature. The recurrence of OSA in our patient mandates surgical intervention, with the risk of attendant anesthetic complications associated with LTH.

CORRESPONDENCE TO

Murat Enoz Address: Deniz Abdal Mahallesi, Veled Celebi Sokak, No:42 Isik Apartmani, A Blok, Daire :9, Findikade, Fatih, Postal Code: 34093, ?stanbul, Turkey. Phone: +905554293937 Fax: +902123439040 Email: muratenoz@gmail.com

References

1. Jones DH, Cohle SD. Unanticipated difficult airway secondary to lingual tonsillar hyperplasia. *Anesth Analg*. 1993 Dec;77(6):1285-8.
2. JESBERG N. Chronic, hypertrophic, lingual tonsillitis. *AMA Arch Otolaryngol*. 1956 Jul;64(1):3-13.
3. Joseph M, Reardon E, Goodman M. Lingual tonsillectomy: a treatment for inflammatory lesions of the lingual tonsil. *Laryngoscope*. 1984 Feb;94(2 Pt 1):179-84.
4. Davies S, Ananthanarayan C, Castro C. Asymptomatic lingual tonsillar hypertrophy and difficult airway management: a report of three cases. *Can J Anaesth*. 2001 Nov;48(10):1020-4.
5. Arrica M, Crawford MW. Complete upper airway obstruction after induction of anesthesia in a child with undiagnosed lingual tonsil hypertrophy. *Paediatr Anaesth*. 2006 May;16(5):584-7.
6. Jones DH, Cohle SD. Unanticipated difficult airway secondary to lingual tonsillar hyperplasia. *Anesth Analg*. 1993 Dec;77(6):1285-8.
7. Elia JC. Lingual tonsillitis. *Ann N Y Acad Sci*. 1959 Sep 1;82:52-6.
8. Nakazawa K, Ikeda D, Ishikawa S, Makita K. A case of difficult airway due to lingual tonsillar hypertrophy in a patient with Down's syndrome *Anesth Analg*. 2003 Sep;97(3):704-5.
9. Enoz M. The Role of the Palatal Surgery in OSAS Treatment. *Firat Medical Journal* 2005;10(4): 147-150. (in Turkey)
10. Federspil P, Barth V. [Indications and methods of lingual tonsillectomy (author's transl)] *Arch Otorhinolaryngol*. 1978

Nov 22;219(2):430-1. German.

11. Wouters B, van Overbeek JJ, Buitter CT, Hoeksema PE.

Laser surgery in lingual tonsil hyperplasia. Clin Otolaryngol Allied Sci. 1989 Aug;14(4):291-6.

Author Information

Murat Enoz, MD

Resident, Department of ORL & Head and Neck Surgery, Maresal Cakmak Military Hospital

Jose Florencio Lapeña, MA, MD

Associate Professor and Attending Otolaryngologist, College of Medicine, Philippine General Hospital, University of the Philippines