
Migrated Intrauterine Device Presenting As A Bladder Stone

A Chaudhary, S Misra, L Senthil Kumar, M Misra, K Sachan, A Sachan

Citation

A Chaudhary, S Misra, L Senthil Kumar, M Misra, K Sachan, A Sachan. *Migrated Intrauterine Device Presenting As A Bladder Stone*. The Internet Journal of Gynecology and Obstetrics. 2004 Volume 4 Number 2.

Abstract

We report a 35 year old lady presenting with a bladder stone formed over a migrated intrauterine device. The lady presented to her gynecologist with amenorrhea for 3 months, irritative lower urinary tract symptoms and haematuria. The lady had a 8 week gestation pregnancy. History was suggestive of intrauterine contraceptive (IUCD) device placement 10 years back. The patient underwent dilatation and curettage as she was not keen on continuing the pregnancy. Investigations included hematocrit, plain X-ray of abdomen, ultrasound of abdomen, urinalysis, and urine culture and sensitivity. Plain X-ray and ultrasound of the abdomen confirmed a bladder stone. Open cystolithotomy was performed under general anesthesia. The stone formed over a copper-T IUCD. Post operative course was uneventful and the patient is currently asymptomatic. The importance of post-insertion follow up and the need for awareness of migration of IUCD including intravesical migration cannot be overemphasized.

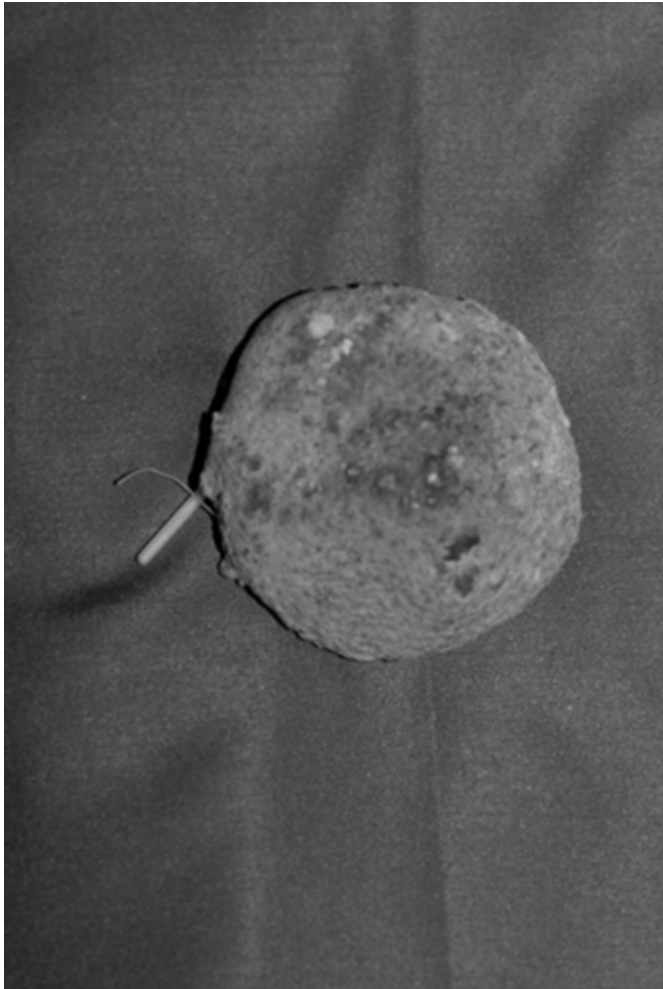
CASE REPORT

We report a 35 year old lady presenting to her gynecologist with amenorrhea for 3 months, lower abdominal pain and increased frequency of micturition. A week back she developed terminal haematuria, high grade fever and burning at micturition. History revealed an attack of frequency and burning at micturition 6 months back for which she consulted a general practitioner and after taking some medication she was relieved. The lady had intrauterine contraceptive device (copper-T) placement 10 years back

after completing her family. The lady never came for follow up after placement of copper-T until she developed the present complaints. Pregnancy test was positive and ultrasound revealed 8 week gestation pregnancy along with a large (5 cm X 5 cm X 5cm) calculus in urinary bladder. There was no evidence of any IUCD on ultrasound. Since the lady was not willing to continue the pregnancy she was planned for dilatation and curettage (D&C). After D&C the patient was referred to us for further management. A plain X-ray abdomen was performed which showed a round radio-opaque shadow in pelvis (Fig. 1).

Figure 1

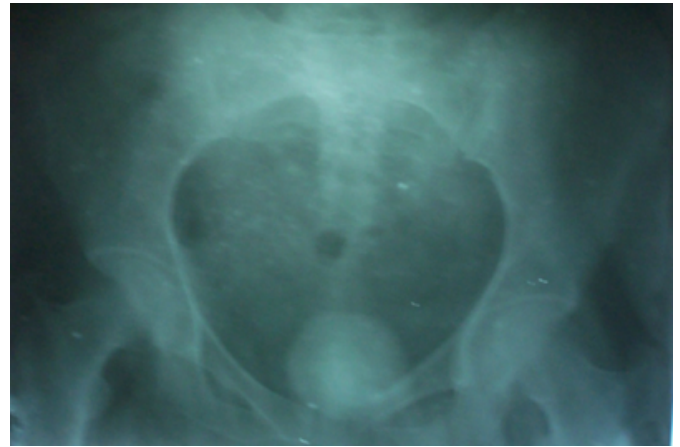Figure 1: Plain X-ray of abdomen showing stone in urinary bladder.



Microscopic examination of urine showed 20-25 leukocytes and 15-20 red blood cells per high power field. Urine was sent for culture and sensitivity and the patient was planned for surgery. Open suprapubic cystolithotomy was performed under general anesthesia. The stone was adhered to the posterior bladder wall but with little efforts it could be separated. The stone was spherical in shape with vertical limb of the copper-T was protruding out from the stone (Fig. 2).

Figure 2

Figure 2: Photograph bladder stone formed over copper-T IUCD. (Vertical limb of IUCD can be seen protruding out of stone)



The intact copper-T was extracted after breaking the stone. The postoperative course was uneventful and the patient was discharged after one week. The patient came for weekly follow up for 2 months and is currently asymptomatic.

DISCUSSION

Intrauterine contraceptive devices can be affected by many early and late complications, including uterine perforation and migration into adjacent structures. Although perforation of the uterus by an intrauterine device is not uncommon, intravesical migration with secondary stone formation is a rare complication¹. To the best of author's knowledge only 25 such cases were reported till 2001². A variety of IUCD have been reported to cause uterine perforation. In a study conducted at Stanford University Hospital Lippes Loop caused most perforations before 1977; however after 1978 most cases involved the Dalkon shield³. Factors contributing to the possibility of uterine perforation are inept insertion or positioning, fragility of the uterine wall due to recent birth, abortion, or pregnancy⁴. In general these uterine perforation and migration of IUCD usually passes unnoticed; the diagnosis is made when the absence of string is noted at routine examination and can be proved by radiological examination⁵. In our patient the diagnosis was made when she became pregnant and developed irritative lower urinary tract symptoms. Radiological or ultrasound controls should be performed in the follow up of patients with intrauterine contraceptive devices⁶. Any women in whom IUCD is placed and who presents with lower urinary tract symptoms, the possibility of intravesical migration of the device should always be considered in the differential diagnosis. The importance of post-insertion follow up and the need for

awareness of the migration of IUCD including intravesical migration cannot be overemphasized.

CORRESPONDENCE TO

Dr. Amit Chaudhary 521/37, Bada Chand Ganj, Lucknow – 226006 Uttar Pradesh, India Phone – 91 9335775099 (Mobile) Phone – 91 522-2321737 (Home) E-mail – amitwtc@yahoo.co.in

References

1. Demirci D, Ekmekcioglu O, Demiratas A, Gulmez I. Big bladder stone around an intravesical migrated intrauterine device. *Int Urol Nephrol.* 2003;35(4):495-6.
2. Gonzalvo Perez V, Lopez Garcia LM, Aznar Serra G, Mola Ariza MJ, Navarro Anton JA, Botella Almodovar, Polo Peris A. Uterine perforation and vesical migration of intrauterine device.

Actas Urol Esp. 2001 Jun;25(6):458-61.

3. Dietrick DD, Issa MM, Kabalin JN, Bassett JB. Intravesical migration of intrauterine device. *J Urol.* 1992 Jan;147(1):132-4.
4. Junceda Avello E, Gonzalez Torga L, Lasheras Villanueva J, De Quiros A GB. Uterine perforation and vesical migration of an intrauterine device. Case observation. *Acta Ginecol (Madr.).* 1977 Feb;30(2):79-86.
5. Centene J, Chelli M. Transuterine migration of intrauterine contraceptive devices. 12 cases. *Nouv Presse Med.* Jun 7;(23):1713-5.
6. Coronel Sanchez B, Sanchez Sanchis MJ, Carrascosa Lloret V, Beltran Armada JR, Rodrigo Guanter V, Tarin Planes M, San Juan De Laroden C. *Arch Esp Urol.* 2004 Jan-Feb;57(1):75-8.

Author Information

Amit Chaudhary

Senior Resident Surgery, Department of Surgery, King George Medical University

Samir Misra

Senior Resident Surgery, Department of Surgery, King George Medical University

L.G. Senthil Kumar

Senior Resident Surgery, Department of Surgery, King George Medical University

Monika Misra

Consultant Gynecologist, Department of Surgery, King George Medical University

Kripa S. Sachan

Consultant Surgeon, Department of Surgery, King George Medical University

Asha Sachan

Consultant Gynecologist, Department of Surgery, King George Medical University