

Case of the Month: Case 3

S Koch, J Nates

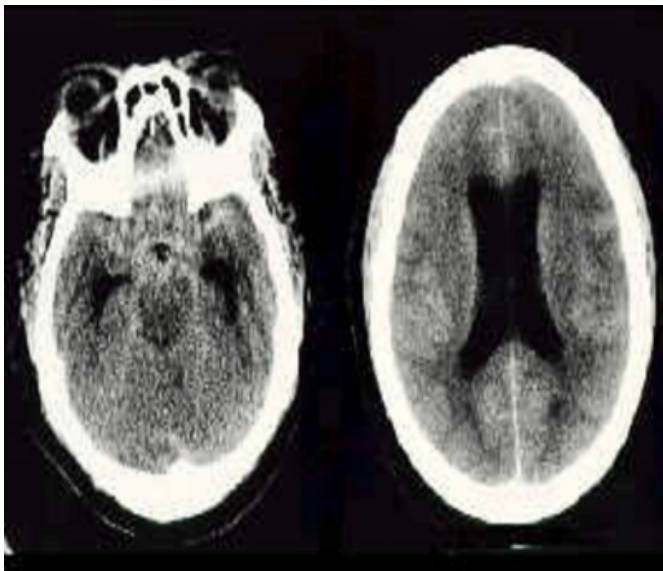
Citation

S Koch, J Nates. *Case of the Month: Case 3*. The Internet Journal of Anesthesiology. 1998 Volume 3 Number 4.

Abstract

Forty seven year old, black female, admitted with subarachnoid hemorrhage grade III. See CT brain below:

Figure 1



A four-vessel angiogram on admission to the emergency room showed multiple cerebral aneurysms and was transferred to our institution. Her past medical history included untreated arterial hypertension and chronic renal failure. On the second day, she was intubated due to respiratory distress. The same day, the patient underwent clipping of 2 of her 5 aneurysms (anterior communicating and right middle cerebral) without complications.

Figure 2

The routine post-operative CT brain on day 8...

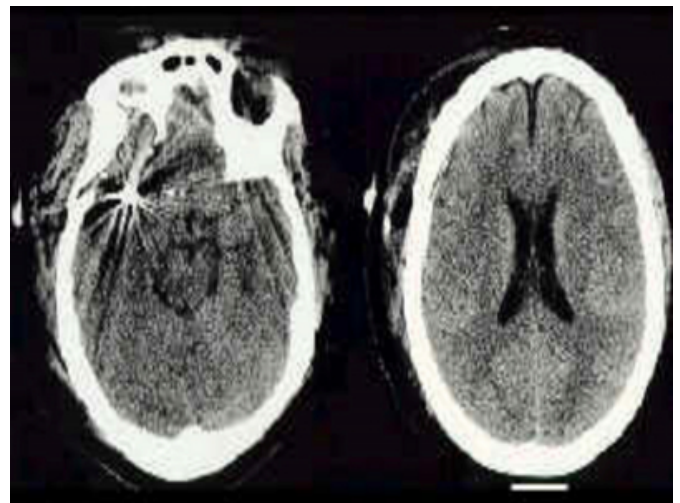
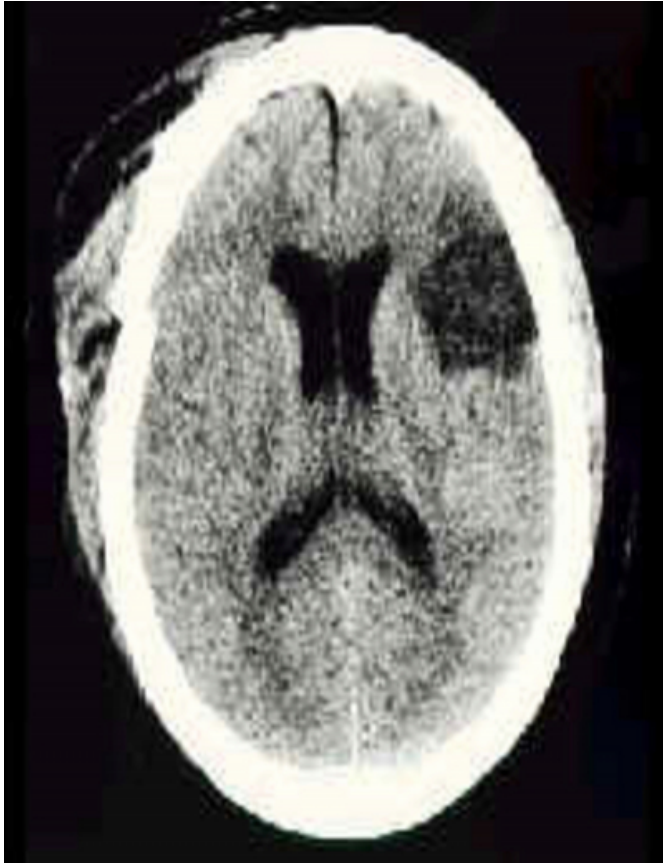

Figure 3

Was followed by this finding on day 15...



The above changes were associated with these physical changes:

{image:4}

{image:5}

{image:6}

{image:7}

1. What is your diagnosis?
2. What is the relation of this entity to syphilis?
3. How are the findings of the CT (on the 15th) associated with this entity?
4. What are the potential complications its therapy?

References

Author Information

Stephen Koch, M.D.*

Associate Professor, Departments of Anesthesiology* and Neurosurgery, Memorial-Hermann Hospital;University of Texas Medical School

Joseph L Nates, M.D.

Departments of Anesthesiology* and Neurosurgery, Memorial-Hermann Hospital;University of Texas Medical School