

# A Complicated Case Of Foreign Body In The Rectum: A Case Report And Review

D Raje

---

## Citation

D Raje. *A Complicated Case Of Foreign Body In The Rectum: A Case Report And Review*. The Internet Journal of Surgery. 2005 Volume 7 Number 2.

## Abstract

Background: Foreign bodies in the rectum are a common occurrence encountered as a surgical emergency. Most cases can be managed by retrieval of object per rectum under anaesthesia using some ingenuity. However a few can be more difficult and require a laparotomy.

Aim: To report a complicated case of rectal foreign body treated at our institution.

Method: We reviewed our case and also extensive literature on this subject.

Case: A 29 year old woman presented with a vibrator in the rectum whilst being used for anal eroticism. She had lower abdominal discomfort but no signs of peritonitis. Attempt to remove it per rectum under anaesthesia failed and a laparotomy was performed to retrieve the object.

Conclusion: Early recognition of problems in extraction per rectum is vital. Practice low threshold in proceeding to laparotomy to prevent anal or rectal injuries.

## INTRODUCTION

The insertion of foreign objects into the anus and rectum is a well-known phenomenon. [1,2,3,4,5,6,7,8,9,10,11]. Treatment involves the careful retrieval of the offending object. It is essential to exclude any colorectal injuries, which if undetected can be lethal. Manual extraction can be difficult due to size, shape and migration of the foreign body.

demonstrated the foreign body (see pictures 1 & 2).

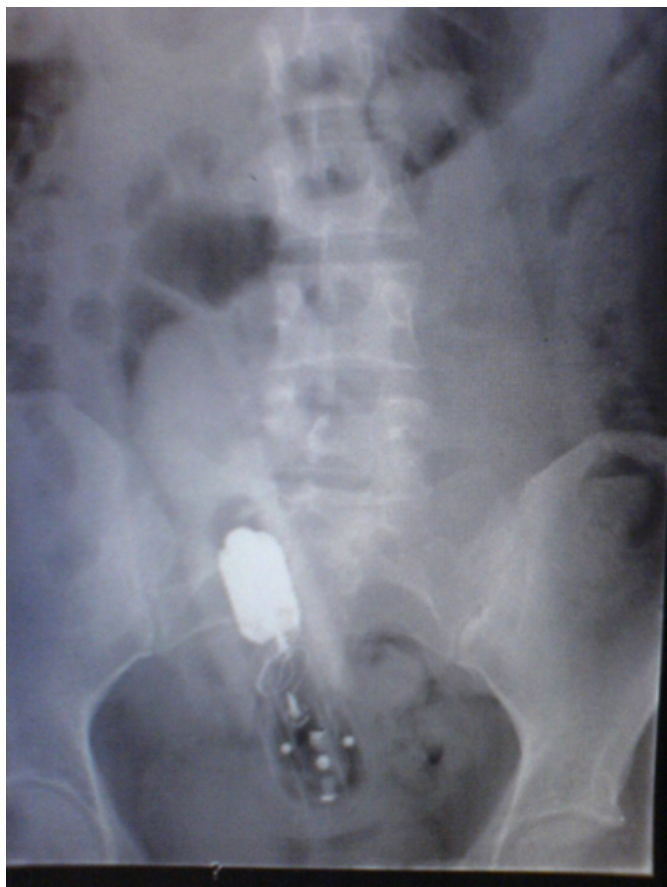## CASE REPORT

A 29 year old female presented with a 8 hour history of difficulty in removal of a battery operated vibrator introduced per anus for autoeroticism. At presentation she was only able to pass small amounts of flatus per rectum and complained of lower abdominal discomfort.

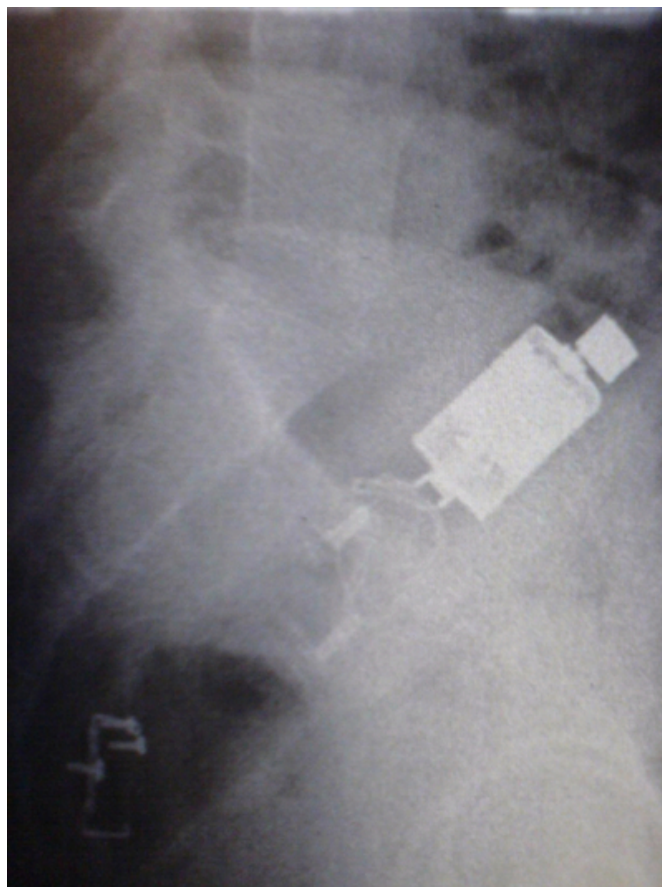On physical examination she had lower abdominal distention and increased bowel sounds on auscultation but there were no signs suggestive of peritonitis. On digital rectal examination it was not possible to palpate the object although there was no blood on the examining finger to suspect injury.

Blood tests were normal and plain X-ray of the abdomen

**Figure 1**

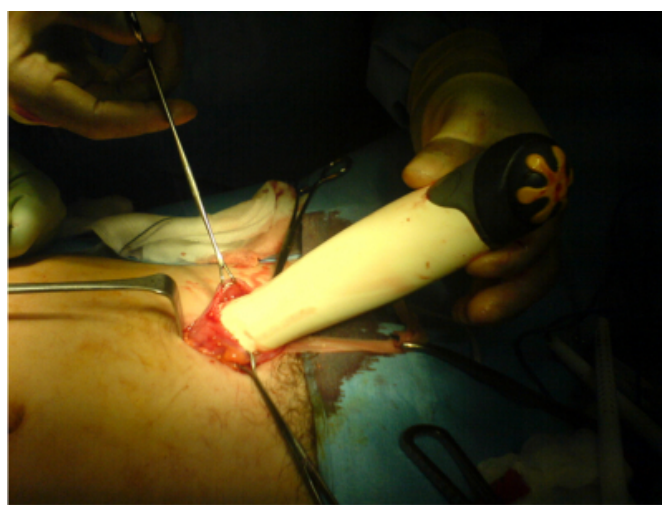


**Figure 2**

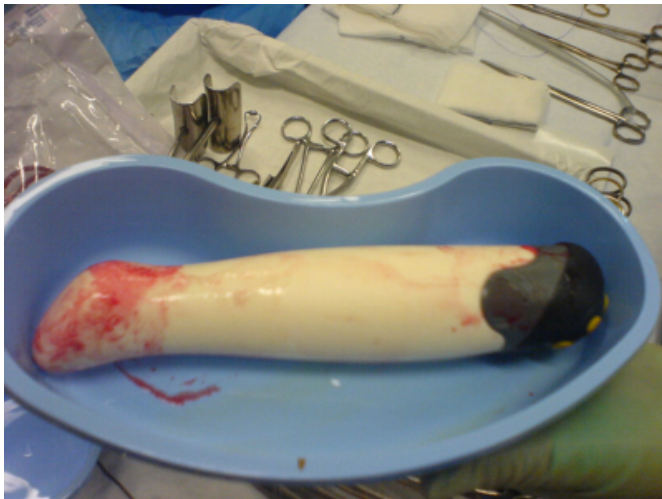

Attempts to extract the vibrator per rectum under GA failed and a laparotomy and colotomy using a small left –sided Pfannensteil incision was performed to extract the object (see pictures 3 & 4).

**Figure 3**



**Figure 4**



## DISCUSSION

Foreign bodies in the rectum and colon are a well-described phenomenon most commonly seen in association with anal eroticism. Busch and Starling [12] reviewed the literature and revealed a plethora of foreign bodies, which have been removed from the rectum. These included a whisky bottle, a light bulb and a magazine. Marks [6] reported a pair of spectacles in the rectum of a 38-year-old man.

Factors which make extraction difficult include the size and shape of the foreign body. A large foreign body, such as the aerosol can, tumbler and a large vibrator in our case, can become impacted by the pelvic floor muscles or migrate higher up in the sigmoid colon. Chronicity may aggravate this. If the object is smooth and without a handle, it may be difficult to obtain a grip on it. This makes it difficult to exert external pressure. If retrieval is unsuccessful laparotomy is necessary [13,14,15,16].

## CONCLUSION

Foreign bodies in the rectum and colon are quite common and most surgeons working in busy general hospitals will encounter such a patient at some point in his/her career. The

diagnosis is confirmed by means of plain abdominal radiographs and rectal examination. Manual extraction without anaesthesia is usually only possible for very low lying objects. Patients with high lying foreign bodies generally require general anaesthesia to achieve complete relaxation of the anal sphincters to facilitate extraction. In the operating room the surgeon needs to use a certain degree of ingenuity and know when to perform a laparotomy.

## References

1. Agnew J. Some anatomical and physiological aspects of anal sexual practices. *J Homosex* 1985; 12: 75-96.
2. McDonald MP, Rosenthal D. An unusual foreign body in the rectum - a baseball: report of a case. *Dis Colon Rectum* 1977; 20: 56-7.
3. Couch CJ, Tan EG, Watt AG. Rectal foreign bodies. *Med J Aust* 1986; 144: 512-5.
4. Eftaiha M, Hambrick E, Abcarian H. Principles of management of colorectal foreign bodies. *Arch Surg* 1977; 112: 691-5.
5. Haft JS, Benjamin HB, Wagner M. Vaginal vibrator lodged in rectum. *Br Med J* 1976; 1: 626.
6. Marks IN. Foreign bodies in the rectum. An unusual collection. *S Afr Med J*; 25: 730-1.
7. Kouraklis G, Misiakos E, Dovas N, Karatzas G, Gogas J. Management of foreign bodies of the rectum. report of 21 cases. *J R Collsurg Edinb* 1997 1963; 42: 246-7.
8. Nehme KA, Abcarian H. Colorectal foreign bodies. Management update. *Dis Colon Rectum* 1985; 28: 941-4.
9. Shah J, Majed A, Rosin D. Rectal salami. *Int J Clin Pract* 2002; 56: 558-9.
10. Thomson SR, Anderson F. Hook line and finger. *S Afr Med J* 2001; 91: 494.
11. Yaman M, Deitel M, Burul CJ, Shahi B, Hadar B. Foreign bodies in the rectum. *Can J Surg* 1993 2001; 36: 173-7.
12. Busch DB, Starling JR. Rectal foreign bodies: case reports and a comprehensive review of the world's literature. *Surgery* 1986; 100: 512-9.
13. Ruiz DC, Selles DR, Millan SM, Zumarraga NP, Asencio AF. Colorectal trauma caused by foreign bodies introduced during sexual activity: diagnosis and management. *Rev Esp Enferm Dig* 2001; 93: 631-4.
14. Cirocco WC. Anesthesia facilitates the extraction of rectal foreign bodies. *Gastrointest Endosc* 2000; 52: 452-3.
15. Hoitsma HF, Meijer S, De Jong D. The transsphincteric approach for removal of a huge foreign body from the rectum. *Neth J Surg* 1984; 36: 83-4.
16. Clarke, D. L., Buccimazza, I., Anderson, F. A. & Thomson, S. R. Colorectal foreign bodies. *Colorectal Disease* 2005; 7 (1): 98-103.

**Author Information**

**D. Raje**

The Whittington Hospital