

Aneurysm Of The Diverticulum Of The Ductus Arteriosus In The Adult Associated With Left Recurrent Laryngeal Nerve Palsy: A Case Series And Review Of The Literature

J Addams-Williams, N Collin, N Agrawal, S Armstrong, P Tierney

Citation

J Addams-Williams, N Collin, N Agrawal, S Armstrong, P Tierney. *Aneurysm Of The Diverticulum Of The Ductus Arteriosus In The Adult Associated With Left Recurrent Laryngeal Nerve Palsy: A Case Series And Review Of The Literature*. The Internet Journal of Otorhinolaryngology. 2005 Volume 4 Number 2.

Abstract

We present the cases of two patients found to have a left recurrent laryngeal nerve palsy secondary to an aneurysm of the ductus arteriosus diverticulum. Aneurysm of the ductus arteriosus diverticulum is a rare but potentially fatal condition in adults. We present two cases with a review of the literature.

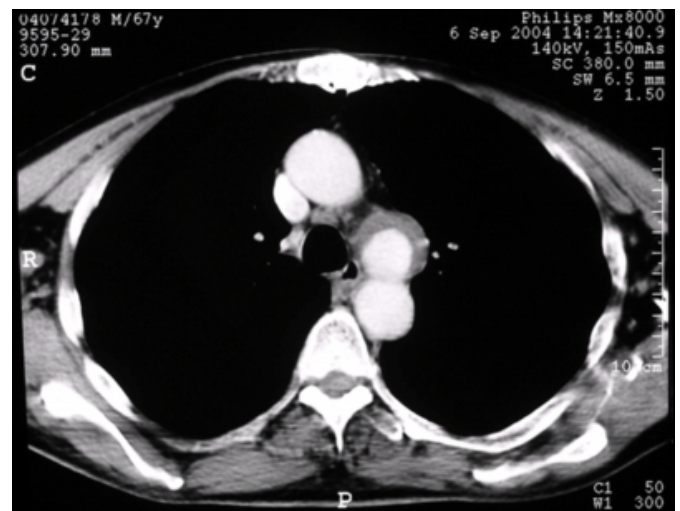
CASE REPORTS

CASE 1

A 68 year old man presented with a nine month history of increasing hoarseness of voice. He had a past history of ischaemic heart disease and had undergone coronary artery bypass grafting five years previously. Fibre optic laryngoscopy revealed a left vocal cord palsy. A computed tomography (CT) scan of the thorax demonstrated an abnormal vascular structure at the arch of the aorta consistent with an aneurysm of the ductus arteriosus diverticulum (figure 1). The patient was referred for a cardiothoracic opinion

Figure 1

Figure 1: A contrast enhanced computed tomography (CT) scan of the thorax demonstrating an abnormal vascular structure at the arch of the aorta consistent with an aneurysm of the diverticulum of the ductus arteriosus.

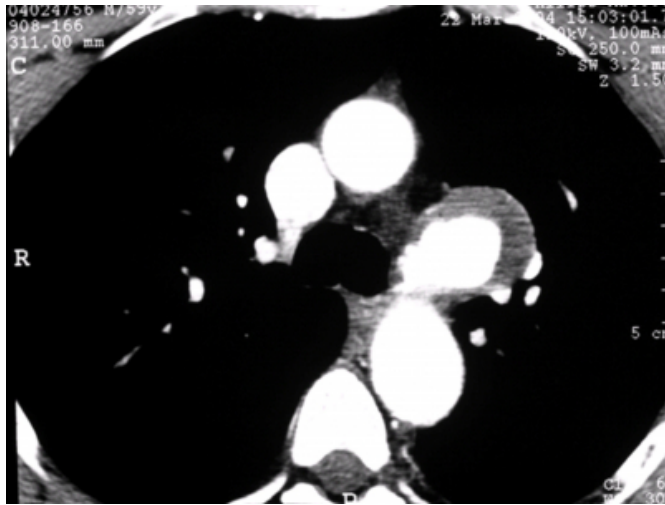


CASE 2

A 59 year old man presented with a 1 year history of a hoarse voice. He had undergone ligation of a patent ductus arteriosus aged eight. Fibre optic laryngoscopy revealed a left vocal cord palsy. A computed tomography (CT) scan of the thorax demonstrated an aneurysm of the ductus arteriosus diverticulum with a maximum diameter of 3 cm (figure 2).

Figure 2

Figure 2: A contrast enhanced computed tomography (CT) scan of the thorax demonstrating an aneurysm of the ductus arteriosus diverticulum with a maximum diameter of 3 cm.



Echocardiogram showed left ventricular hypertrophy. Coronary angiogram prior to surgery showed no evidence of coronary artery disease. The patient underwent a thoracic arch stenting procedure. Post operatively he developed a right sided homonymous hemianopia. A computed tomography (CT) of the brain confirmed that an occipital lobe infarct had occurred post stent insertion. He is otherwise doing well clinically two months following surgery.

DISCUSSION

One hundred and forty four cases of aneurysms of the ductus arteriosus have been reported in the literature of which 106 occurred spontaneously and 38 followed surgical treatment of a patent ductus arteriosus⁽¹⁾. The pulmonary arterial end of the ductus arteriosus aneurysm is usually obliterated^(1, 2). Most authors believe that a disorganised closure of the duct shortly after birth leads to an aortic diverticulum. Over time particularly if hypertension is present, this can enlarge to form an aneurysm. Connective tissue disorders such as Marfan's syndrome⁽³⁾ and Ehlers-Danlos syndrome⁽⁴⁾ have also been associated with aneurysms of the ductus arteriosus. In adults, the aneurysm may present with hoarseness, cough, anorexia and thoracic pain due to involvement of adjacent organs and nerves⁽¹⁾. Pulmonary hypertension with dyspnoea and peripheral oedema due to a large left-right shunt may dominate the picture but is rare⁽¹⁾. A typical Gibson continuous murmur, maximal in the second intercostal space may be audible in patients with a patent duct^(1, 5). Radiologically these can present as a mass lesion

in the aortopulmonary window⁽⁶⁾. Contrast enhanced CT scanning is ideal for showing the vascular nature of the mass^(, 6). Angiography will demonstrate if one or both ends of the ductus are patent⁽⁶⁾. Transoesophageal echocardiography can also be used to visualise lesions of the thoracic aorta⁽⁷⁾.

The most commonly reported complication in adults is rupture occurring in 28% of cases⁽¹⁾. Other complications include erosion into adjacent structures (pericardium, bronchi, oesophagus), endocarditis and thrombosis^(1, 2). Lund et al⁽¹⁾ recommend prompt surgical treatment of all spontaneous ductus arteriosus aneurysms in patients older than 2 months of age, and in all cases of post operative ductus arteriosus aneurysms. Mitchell et al⁽²⁾ are of the opinion that because of their critical location and the high incidence of complications in reported cases, aneurysms greater than 3cm in diameter, those producing symptoms, or those showing progressive enlargement should be surgically resected. In adults the surgery required depends on the extent of arterosclerotic changes in the aorta^(1, 2).

Aneurysmorrhaphy is frequently possible in the absence of significant arterosclerosis of the thoracic aorta^(1, 2).

Operative mortality of adults presenting with a spontaneous ductus arteriosus aneurysm is 7%⁽¹⁾.

CONCLUSION

Aneurysm of the ductus arteriosus diverticulum is a rare cause of left recurrent laryngeal nerve palsy. We would recommend that all patients presenting with hoarseness secondary to a left vocal cord palsy should undergo a contrast CT scan of the thorax with the arterial phase starting at the root of the aorta. Aneurysms of the ductus arteriosus diverticulum in patients presenting with hoarseness require prompt surgical intervention.

CORRESPONDENCE TO

Miss Julia Addams-Williams MRCS Troedrihwfergam
Cwmcou Newcastle Emlyn Ceredigion, SA38 9PQ, UK
Email: addamswilliamsjh@hotmail.com

References

1. Lund JT, Jensen MB, Hjelms E. Aneurysm of the Ductus Arteriosus. A Review of the Literature and the Surgical Implications. *European J of Cardiothoracic Surg* 1991; 5: 566-570
2. Mitchell R, F. Seifert, D Miller, S. Jamieson, E Shumway. Aneurysm of the Diverticulum of the Ductus Arteriosus in the Adult. *The Journal of Thoracic and Cardiovascular Surgery* 1983; 86: 400-408
3. Muller N, Mayo J, Culham J Nichols D. Ductus arteriosus aneurysm in Marfan's syndrome. *Can Assoc Radiol J* 1986;

Aneurysm Of The Diverticulum Of The Ductus Arteriosus In The Adult Associated With Left Recurrent Laryngeal Nerve Palsy: A Case Series And Review Of The Literature

37: 195-197

4. Chang J, Chang G, Sheil M. Aneurysmal dilation of the patent ductus arteriosus in a case of Ehlers-Danlos syndrome. *Ann thoracic Surg* 1987; 44: 656-657

5. Kelly DT. Patent Ductus Arteriosus in Adults. *Cardiovasc Clin* 1979;10: 321-323.

6. Taneja K, Gulati M, Jain M, Saxena A, Das B, Rajani M.

Ductus Arteriosus Aneurysm in the Adult: Role of Computed tomography in Diagnosis. *Clinical Radiology* 1997; 52: 231-234

7. Taams M, Gussenhoven W, Schippers L, Herwerden L, Bos E, Jong N, Bom N. The value of transoesophageal echocardiography for the diagnosis of thoracic aorta pathology. *Eur Heart J* 1988; 9: 1308-1316

Author Information

J.H. Addams-Williams, MRCS

Department of Otorhinolaryngology / Head and Neck Surgery, Southmead Hospital

N. Collin, MRCS

Department of Radiology, Southmead Hospital

N. Agrawal, MRCS

Department of Otorhinolaryngology / Head and Neck Surgery, Southmead Hospital

S. Armstrong, MRCP FRCR

Department of Radiology, Southmead Hospital

P.A. Tierney, MA FRCS (ORL-HNS)

Department of Otorhinolaryngology / Head and Neck Surgery, Southmead Hospital