

Successful Excision Of An Enormous Mesenteric Lymphangioma In An Adult: Report Of A Case

S Ammar

Citation

S Ammar. *Successful Excision Of An Enormous Mesenteric Lymphangioma In An Adult: Report Of A Case*. The Internet Journal of Surgery. 2007 Volume 17 Number 2.

Abstract

We herein describe a case of a 20-year-old male, who presented with a large abdominal cyst. Repeated therapeutic aspiration of the cyst was followed by rapid recurrence. Preoperative imaging studies demonstrated a massive cyst occupying most of the abdomen. At laparotomy, a giant cyst (39 x 29 x 15cm) of the mesentery was found. It was attached to the anterior and posterior abdominal walls and extended from the undersurface of the liver to the urinary bladder. Histopathologic examination diagnosed the cyst as a cystic lymphangioma. Although mesenteric lymphangiomas are rare, especially in adults, they may sometimes present as painless increase of the abdominal girth and grow to an enormous size. Complete surgical removal is considered to be the procedure of choice.

INTRODUCTION

Lymphangiomas are benign vascular neoplasms that most often are seen in children. Seventy-five percent of lymphangiomas occur in the neck, 20% occur in the axilla, and the remaining 5% are found in many other locations ¹. Intra-abdominal lymphangiomas are rare and the most common locations are the mesentery, omentum, mesocolon, and retroperitoneum ². Some patients present acutely with intestinal obstruction, volvulus, infarction, bleeding, or infection, whereas others present with increasing abdominal girth, vague discomfort, and pain ^{2,3,4,5,6}.

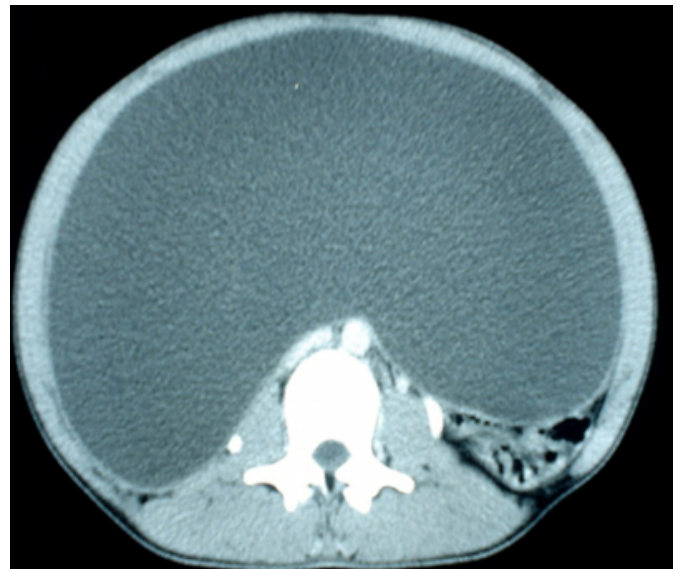
CASE HISTORY

A 20-year-old otherwise healthy male presented to our surgery clinic in April 2007 because of an increasing abdominal girth. He experienced abdominal discomfort only late in his presentation. There was a past history of repeated therapeutic aspiration of a clear fluid from the abdomen in the internal medicine department. On examination, his abdomen was significantly distended, non-tender to palpation and dull to percussion. A fluid thrill could be elicited through his abdomen. Chest x-ray demonstrated both diaphragmatic copulas elevated. Abdominal ultrasonography showed a huge cystic lesion occupying the whole abdomen and displacing all abdominal organs. A computerized tomographic (CT) scan revealed a huge intra-abdominal cystic lesion extending from the upper abdomen to the pelvic region, and displacing the intestinal loops posteriolaterally.

The cystic lesion showed a thin well-defined wall with no soft-tissue masses (Fig. 1). Preoperative body weight was 61kg.

Figure 1

Figure 1: CT scan image of the mid-abdomen showing a massive cyst occupying almost the entire abdominal cavity.



Intraoperatively, the huge cyst was found to be adherent to the posterior aspect of the anterior abdominal wall, mostly from repeated aspiration. After dissection, the cyst was found to be intimately associated with the mesentery and adherent to ascending colon and appendix (Fig. 2), posteriorly attached to the posterior abdominal wall and

dissected with difficulty from both ureters. The cyst extended from the undersurface of the liver to the pelvis to be dissected from the urinary bladder. Most of the bowel was displaced by the cyst and found near the stomach and spleen. Grossly, the cyst, measured 39 x 29 x 15cm. The cyst weighed 12kg which constituted about 20% of the patient body weight. The cut section revealed a unilocular cyst with a smooth lining with red and black areas. The fluid contents were yellow in color, and turbid. Chemical examination of the fluid revealed 48.3g/l protein content. Cytological examination of the fluid was negative for malignancy with lymphocytes (++) and polymorphs (+). The histopathological picture of the cyst (Fig. 3) was that of a cystic lymphangioma. The patient had an uneventful postoperative course.

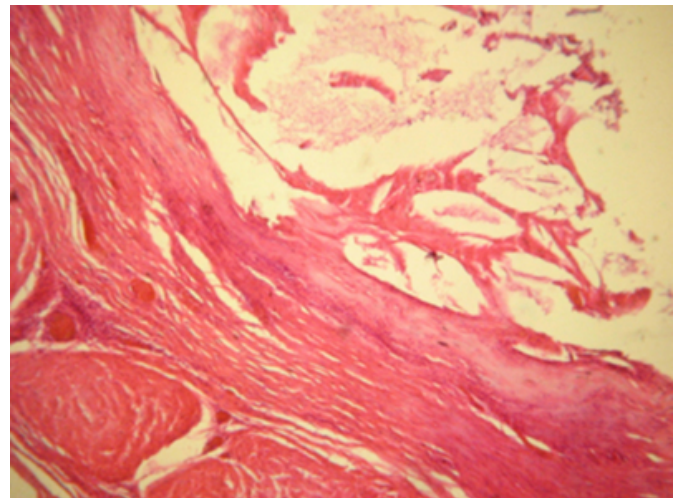
Figure 2

Figure 2: Intra-operative view of the cyst adherent to the ascending colon and the appendix.

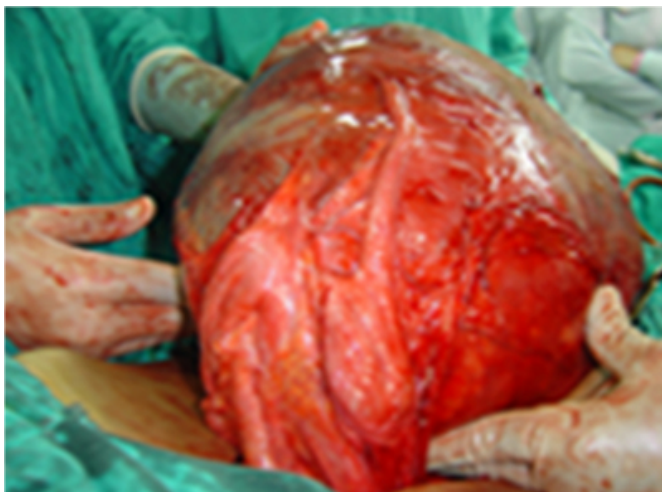

Figure 3

Figure 3: The microscopic view of the surgical specimen revealed dilated cavernous spaces filled by lymph and lined by endothelial cells, and smooth muscle in its wall



DISCUSSION

Mesenteric cysts are one of the rarest intra-abdominal tumors ⁷. The reported incidence ranges from 1/20,000 to 1/250,000 admissions to hospital. ⁸ Cystic lesions of the mesentery may arise from embryonic rests (enteroceles or dermoids), developmental defects (chylous or serous retention cyst), lymphatic tissue (lymphangioma), or after trauma (hemorrhagic cysts) ⁹. The etiology of lymphangiomas is probably a congenital abnormality of the lymphatic system ¹⁰. This theory would explain why lymphangiomas occur primarily in children. However, it is suggested that abdominal trauma, lymphatic obstruction, inflammatory process, surgery, or radiation therapy may lead to the secondary formation of such a tumor ^{11,12}.

Traditionally, lymphangiomas are classified as simple, cavernous, or cystic. The simple type is usually situated superficially in the skin and composed of small thin-walled lymphatic vessels. The cavernous type is composed of dilated lymphatic vessels and lymphoid stroma, and has a connection with various normal adjacent lymphatics. Lastly, the cystic type consists of lymphatic spaces of various sizes that contain fascicles of smooth muscle and collagen bundles, but has no connection with adjacent normal lymphatics ¹³.

Mesenteric lymphangiomas are rare but may grow to an enormous size. Surgery is the mainstay of treatment ¹⁴ and aspiration of the cyst alone should not be performed. Complete enucleation of cysts is considered to be the procedure of choice, to prevent recurrence and possible

malignant transformation. Laparoscopic excision of a mesenteric cyst is sometimes possible ¹⁵ .

CORRESPONDENCE TO

Samir Ahmad Ammar, MD Department of General Surgery
Assiut University Hospitals, El Gamma Street Assiut -
Egypt. Fax: 002-088- 2333327 Tel.: 002-088-2295696
Email: microsurg1@gmail.com

References

1. Hovanessian LJ, Larsen DW, Raval JK, Colletti PM. Retroperitoneal cystic lymphangioma: MR findings. *Magn Reson Imaging*. 1990; 8: 91-93.
2. Galifer RB, Pous JG, Juskiwenski S, Pasquie M, Gaubert J. Intra-abdominal cystic lymphangiomas in childhood. *Prog Pediatr Surg*. 1978; 11: 173-238.
3. de Perrot M, Rostan O, Morel P, Le Coultre C. Abdominal lymphangioma in adults and children. *Br J Surg*. 1998; 85: 395-397.
4. Chaturvedi KU, Singh N, Sakhuja P. Intra-abdominal lymphangioma: clinicopathological profile of a rare lesion. *Indian J Pathol Microbiol* 1997; 40: 563-566.
5. Troum S, Solis MM. Mesenteric lymphangioma causing bowel obstruction in a child. *South Med J*. 1996; 89: 808-809.
6. Yoon HK, Han BK. Chronic midgut volvulus with mesenteric lymphangioma: a case report. *Pediatr Radiol*. 1998; 28: 611.
7. Liew SCC, Glenn DC, Storey DW. Mesenteric cyst. *Aust NZ J Surg*. 1994; 64: 741-744.
8. Kurtz MD, Heimann TM, Beck AR, Holt J. Mesenteric and retroperitoneal cysts. *Ann Surg*. 1986; 203: 109-12.
9. Daly JM, Adams JT, Fantini GA, and Fischer E. Abdominal wall, omentum, mesentery, and retroperitoneum. In: Schwartz SI, Shires GT, Spencer FC, Daily JM, Fischer JE, Galloway AC, Editors, *Principles of surgery* (7th edition), McGraw-Hill, New York (1999), pp. 1551-1584.
10. Roisman I, Manny J, Fields S, Shiloni E. Intra-abdominal lymphangioma. *Br J Surg*. 1989; 76: 485-489.
11. Hardin WJ, Hardy JD. Mesenteric cysts. *Am J Surg*. 1970; 119: 640-645.
12. Daniel S, Lazarevic B, Attia A. Lymphangioma of the mesentery of the jejunum: report of a case and a brief review of the literature. *Am J Gastroenterol*. 1983; 78: 726-729.
13. Rieker RJ, Quentmeier A, Weiss C, Kretzschmar U, Amann K, Mechttersheimer G, et al. Cystic lymphangioma of the small-bowel mesentery. *Pathol Oncol Res*. 2000; 6: 146-148.
14. Chen CW, Hsu S, Lin CH, Cheng MF, Yu JC. Cystic lymphangioma of the jejunal mesentery in an adult: a case report. *World J Gastroenterol*. 2005; 11: 5084-86.
15. Vu J-H, Thomas EL, Spencer DD. Laparoscopic management of mesenteric cyst. *Am Surg*. 1999; 65: 264-5.

Author Information

Samir A. Ammar, MD

Department of Surgery, Assiut University Hospitals