

# Alternative Hepaticojejunostomy For A Very Thin Bile Duct

B Gala, J Copo

## Citation

B Gala, J Copo. *Alternative Hepaticojejunostomy For A Very Thin Bile Duct*. The Internet Journal of Surgery. 2004 Volume 6 Number 1.

## Abstract

Biliary complications after pancreatoduodenectomy are a cause of morbidity, especially when the original lesion does not dilate the common bile duct (CBD). The authors present a technical modification to perform a bile-enteric anastomosis in the presence of an extremely thin CBD, on a patient with a duodenal stromal tumor.

The hepaticojejunostomy was performed as follows: The jejunal free limb of a Roux-in-Y was opened through its anterior wall with a lineal incision. The stump of the remaining CBD was introduced into the jejunal lumen through and opposite opening. Sutures were applied to the end of the stump interiorly, involving the entire bile duct wall and the jejunal mucosa and submucosa, over a silicone tutor. The jejunal external wall close to the entering site of the CBD was fixed to the later, and the jejunal anterior opening was finally closed.

The patient recovered uneventfully and is cholangitis-free, 5 years after the operation.

## INTRODUCTION

Surgical treatment prevails as the best treatment option for Gastro Intestinal Stromal Tumours (GIST), and in the case of malignant duodenal GIST, radical resection has shown the best long-term results. [1,2] Occasionally, these tumors do not involve the major duodenal papilla. Therefore, they do not produce biliary obstruction and dilation of the common bile duct (CBD). Several techniques have been described to perform biliary anastomosis using thin bile ducts [3]. Still biliary leaks, cholangitis and long-term strictures may arise in most cases postoperatively.[4]

The authors report an alternative surgical technique successfully used to perform a bile-enteric anastomosis using a very thin bile duct, while treating a malignant duodenal GIST with pancreatoduodenectomy.

## CASE REPORT

A 43 year old man was admitted at a clinical service of Hemanos Ameijeiras Hospital in Havana, Cuba, sustaining various events of upper gastrointestinal bleeding. The patient had been under oral NSAID medication due to a leg trauma and there were no other associated diseases. Physical examinations showed no significant findings.

All hematological and chemical blood test were within

normal values. Abdominal ultrasound and computed tomography scan showed a 3.5 cm tumor in the second portion of the duodenum and no liver metastases or peritoneal carcinomatosis were found. Endoscopy revealed a tumor in the second portion of the duodenum adjacent to the papilla of Vater, without involving it, and with evidences of recent bleeding. A biopsy was taken during this examination and revealed a differentiated stromal tumour with moderate mitotic index and necrosis.

## OPERATIVE TECHNIQUE

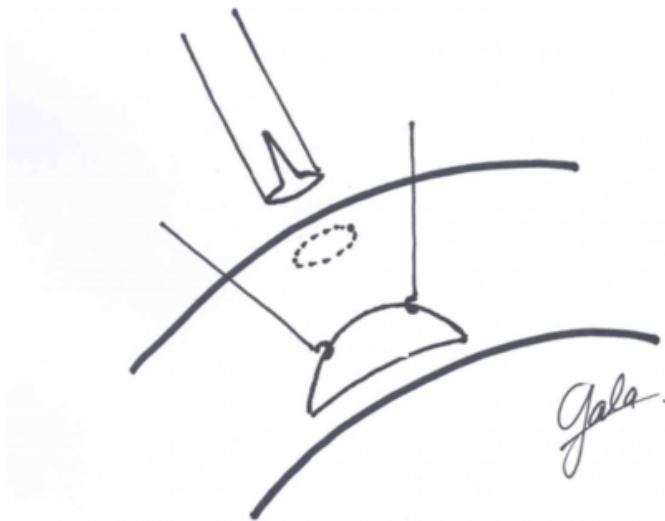
During laparotomy no evidences of extra duodenal tumor extension were found, and therefore a pancreatoduodenectomy [5] was performed. Since the mass did not involve the duodenal papilla, the CBD was not dilated (around 2 – 3 mm in diameter). Several technical possibilities to perform a biliary anastomosis were discussed, and at the end we decided to apply an alternative end-to-side anastomosis as follow:

The free jejunal limb of the Roux-in-Y to be used was opened through its anterior wall with a 3 cm lineal incision. The stump of the remaining CBD, with an opening in its anterior ending, was introduced into the jejunal lumen through and opposite small opening (figure1). Four or five discontinued stitches of 7/0 absorbable suture were applied

to the end of the stump interiorly, involving the entire bile duct wall and the jejunal mucosa and submucosa, over a suitable silicone catheter acting as a tutor. The jejunal external wall, close to the entering site of the CBD was fixed to the later with two lateral superficial sutures. Two further stitches were applied to fix the jejunal limb to the liver capsule, in order to avoid tension on the anastomosis. Finally, the anterior opening of the jejunal limb was closed in normal fashion (figure 2). This biliary reconstruction was performed under loupe magnification.


**Figure 1**

Figure 1: Initial aspect of the anastomosis. The common bile duct (CBD) has been opened in its anterior ending. The jejunal loop (JL) presents an anterior incision (1) to work inside the lumen and a small opposite opening (2) to introduce the duct.



**Figure 2**

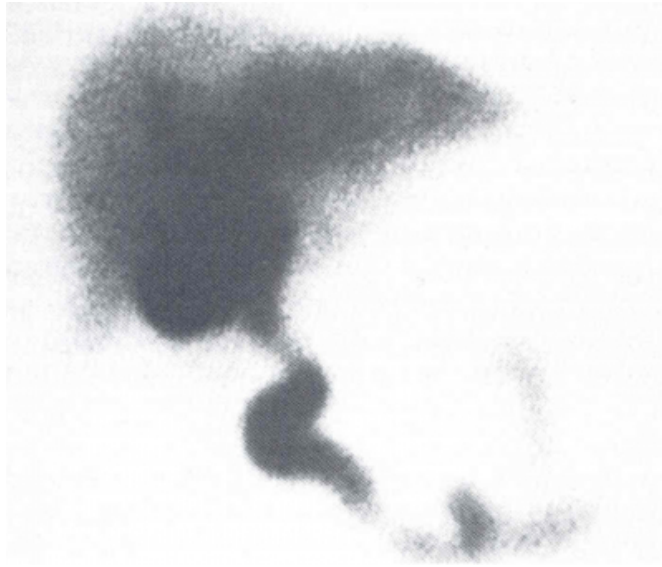Figure 2: Final aspect of the anastomosis. The common bile duct (CBD) is already introduced into the jejunal loop (JL) and sutured to the jejunal mucosa interiorly using discontinued absorbable stitches (2). A silicone tube (T) is left as a tutor and the jejunal anterior incision is closed (1). The anastomosis is secured by stitches involving the jejunal external wall and bile duct wall (3), as well as stitches involving the jejunal serosa and the liver capsule (4).



Postoperative recovery followed uneventfully and the patient was discharged on the 10th postoperative day, receiving further treatment with Imatinib mesylate (a tyrosine kinase inhibitor [6]). The patient is now totally recovered and free of disease and without any events of cholangitis after 5 years of follow-up. Figure 3 presents a 99mTc HIDA scan view showing normal functioning of the anastomosis 5 years after the operation.

**Figure 3**

Figure 3: 99mTc HIDA scan view showing normal functioning of the anastomosis 5 years after the operation.



**DISCUSSION**

Biliary complications after pancreatoduodenectomy are a major cause of morbidity. They usually present shortly, as biliary leaks, which could lead to more serious complications, including intraperitoneal abscess, subsequent sepsis and massive hemorrhage by activating pancreatic fistula [4,7]. Furthermore, long-term complications may arise by means of strictures of the anastomosis and subsequent cholangitis.[8]

This paper presents a technical modification to perform an end-to-side hepaticojejunostomy in the presence of an extremely thin bile duct, preserving higher biliary segments for future reconstruction, if needed.

This technique is low time-consuming, requires few dissection and is easy to reproduce. It has only been used once, since no other patient with same bile duct diameter has ever presented. Still, that single patient showed no short neither long-term complications after 5 years of follow-up.

As a conclusion, we offer this technique for the surgeon's armamentarium, to be used when a very thin bile duct presents. Yet, further studies involving larger series may be required to ensure total validity.

**CORRESPONDENCE TO**

Boris L. Gala. MD, MSc. Calle 54 #4905, e/ 49 y 51. Playa. Havana, Cuba. Postal code 11400. Phone: (537)2093703, e-mail gala32486@yahoo.com

**References**

1. Hompes D, Topal B, Ectors N, Aerts R, Penninckx F. Gastro-intestinal stromal tumour of the duodenum: extreme presentation in two cases. *Acta Chir Belg* 2004; 104(1): 110-113.
2. Parreira J, de Freitas W, Rasslan S. Upper gastrointestinal haemorrhage due to duodenal stromal tumor. *Arq Gastroenterol* 2003; 40(3): 188-191.
3. Compagnon P, Lakehal M, Boudjema K. Roux-en-Y limb anastomosed to small biliary duct. *Ann Chir* 2003; 128(3): 191-194.
4. Suzuki Y, Fujino Y, Tanioka Y, Ajiki T, Hiraoka K, Takada M, Takeyama Y, Tominaga M, Ku Y, Kuroda Y. Factors influencing hepaticojejunostomy leak following pancreaticoduodenal resection; importance of anastomotic leak test. *Hepatogastroenterology* 2003; 50(49): 254-257.
5. Whipple A, Parsons W, Mullins C. Treatment of carcinoma of the ampulla of Vater. *Ann Surg* 1935; 102: 763-79.
6. Eisenberg B. Imatinib mesylate: a molecularly targeted therapy for gastrointestinal stromal tumors. *Oncology* 2003; 17(11): 1615-1620.
7. Peters J, Carey L. Historical review of pancreaticoduodenectomy. *Am J Surg* 1991; 161: 219-225.
8. Ammori B, Joseph S, Attia M, Lodge J. Biliary strictures complicating pancreaticoduodenectomy. *Int J Pancreatol* 2000; 28(1): 15-21.

**Author Information**

**Boris L. Gala, M.D., M.Sc.**

HBP and Transplant Surgeon, Master in Science on Medical Informatics, Adjunct Professor for Medical Informatics, University of Havana

**José A. Copo, M.D.**

HBP and Transplant Surgeon., HBP Surgery and Transplant Unit, Hermanos Ameijeiras Hospital