

# Neuroclinical Anatomy of the third Cranial Nerve

T Rabiú

## Citation

T Rabiú. *Neuroclinical Anatomy of the third Cranial Nerve*. The Internet Journal of Neurology. 2009 Volume 12 Number 2.

## Abstract

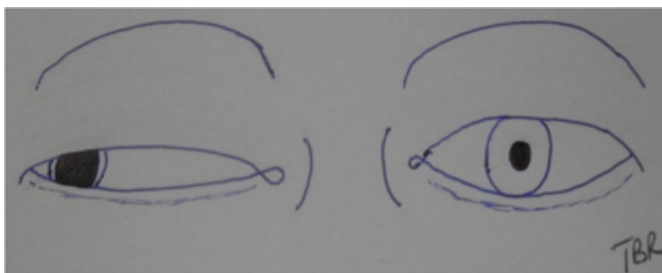
The oculomotor (third) cranial nerve arises from the upper part of the mesencephalon (midbrain). It carries both a somatic efferent (motor) supply to some of the extra-ocular muscles and a general visceral efferent (parasympathetic) supply to the sphincter pupillae and ciliaris muscles. Its contribution to the pupillary light reflex represents an important aspect of its function and is an essential component of the evaluation of neurological patients. This paper reviews the neuroclinical aspects of the nerve's anatomy and provides easily understandable guidance to an effective assessment of its dysfunction. The contributions of the third cranial nerve to pupillary reaction to light, the changes in pupillary size reflecting the various stages of its dysfunction in intracranial pathologies, and its association with neurotrauma as well as some of the eponymous syndromes associated with it are discussed.

## INTRODUCTION

Oculomotor (third cranial nerve) palsy is one of the most commonly encountered cranial nerve deficits in clinical practice. Milanes-Rodriguez and his colleagues<sup>1</sup> have given a concise description of the origin and course of the nerve. It is the first nerve to arise from the brain stem (the first {olfactory} and second {optic} nerves arise in the nasal olfactory epithelium and ganglion cells of the neural retina respectively)<sup>2</sup>. The classic finding in third nerve palsy is ptosis and downwards and outwards position of the ipsilateral eye (looking down and out).(Fig. 1)

### Figure 1

Fig. 1: Right ptosis, pupillary dilatation and a 'down and out' eye in third nerve palsy



## FIBERS AND NUCLEI

The dysfunction of the nerve includes that of the peripherally located fibers mediating pupillary constriction (parasympathetic supply to the sphincter pupillae muscles) as well as the motor supply to all extra-ocular muscles with the exception of the superior oblique (supplied by the fourth cranial {trochlear} nerve) and the lateral rectus (supplied by

the sixth cranial {abducens} nerve) muscles. (A useful mnemonic is LR6, SO4; that is, Lateral Rectus supplied by the 6<sup>th</sup> nerve; Superior Oblique supplied by the 4<sup>th</sup> nerve). The two nuclei of the nerve (oculomotor nucleus {somatic efferent} and the Edinger-Westphal nucleus {parasympathetic} are located in the upper part of the midbrain<sup>2</sup>.

## THE PUPIL IN THIRD NERVE PALSY

An examination of the pupil provides a good insight into the functional status of the oculomotor nerve. Specifically, the pupillary light reflex assesses both the optic nerve (afferent) as well as the oculomotor nerve (efferent). As such, the absence of direct light reflex in the ipsilateral eye in the presence of consensual light reflex in the contralateral eye indicates a third nerve deficit rather than an optic nerve problem. In the patient with acute traumatic brain injury, this finding is highly indicative of brainstem compression.

Incomplete or partial oculomotor nerve paresis can be pupil-sparing or non-pupil sparing. This phenomenon is a reflection of the topographic arrangements of the nerve fibers. The fibers supplying the sphincter pupillae muscles are located peripherally and are therefore affected early in extrinsic compression of the nerve<sup>3</sup> by, for example, posterior communicating artery aneurysm, tumours and brainstem herniation in intracranial mass lesions. In contrast, intrinsic lesions of the nerve, affecting the inner fibers which supply the extra-ocular muscles, spares the pupillary fibers (and therefore the pupillary light reflex is preserved) until

very late in the course of the disease. This commonly results from micro-ischaemia as caused by, for example, diabetes mellitus, atherosclerosis (as in chronic hypertension), temporal arteritis and myasthenia gravis<sup>4</sup>. Rarely, pupil-sparing oculomotor palsy has been described following an intra-axial lesion such as midbrain infarction<sup>5</sup>.

Pupillary changes in uncal herniation in neurotrauma, brain tumours or other intracranial supratentorial space occupying lesions may be staged<sup>6</sup> as follows:

Hutchinson’s stage I: ipsilateral miosis due to oculomotor nerve irritation

Hutchinson’s stage II: oculomotor nerve paresis causing ipsilateral pupillary dilatation and a sluggish response to light

Hutchinson’s stage III: Progressive dilatation of the ipsilateral pupil and miosis of the contralateral pupil (heralds progressive third nerve palsy due to temporal lobe herniation)

Hutchinson’s stage IV: bilateral dilation of the pupil (terminal stage)

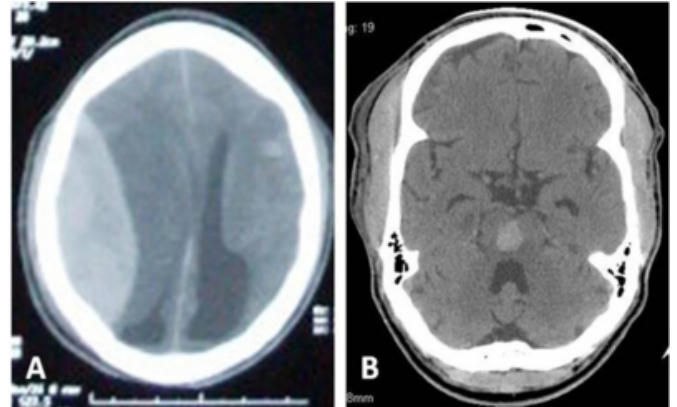
**THE THIRD NERVE IN HEAD INJURY**

Head injuries are a major cause of morbidity and mortality worldwide. It is estimated that a head injury occurs every 15 seconds and a patient dies of head injury every 12 minutes<sup>7</sup>. Its incidence has been reported as 109 per 100,000 population<sup>8</sup>. While road traffic accidents are the leading cause of head injury worldwide<sup>7</sup>, the contribution of war and conflicts are nonetheless very significant. In the Iraqi war, an estimated 1700 military personnel were thought to have sustained this injury to varying degrees<sup>9</sup>.

Cranial nerve injuries are common in head injuries. The incidence of oculomotor nerve damage in head injury has been reported as 2.7% in one study<sup>10</sup>. The nerve may be damaged directly by, for example, skull fractures or brainstem haematoma involving its nuclei (Fig. 2) or indirectly by intracranial mass lesion, such as an haematoma (Fig. 2) which cause uncal herniations and pressure on it.

**Figure 2**

Fig. 2: Examples of causes of oculomotor nerve damage as found on cranial computerized tomography: huge right parietal acute extradural haematoma (A) and midbrain haematoma (B).



Depending on the affected part of the nerve, the injury might be complete or partial. Lesions in the orbit tend to affect the branches of the nerve in unequal proportion. Lesions affecting the superior division of the nerve cause ptosis and impaired elevation of the eye while those of the inferior division cause impairment of depression, adduction and pupillary reaction<sup>4</sup>.

**EPONYMOUS SYNDROMES**

Lesions affecting the midbrain (mesencephalon) may present with disorders of the oculomotor nerve functions in combination with other deficits<sup>11</sup>, in particular, motor deficits may be concomitant findings as a result of the involvement of the descending corticospinal tracts by such lesions. Though mostly described for vascular lesions such as cerebrovascular disease (CVD), the syndromes may also be found in traumatic injury of the midbrain. (Table 1).

**Figure 3**

Table1: Eponymous syndromes associated with third nerve palsy

Syndrome	Ipsilateral	Contralateral	Lesion site
Weber's	Oculomotor palsy	Hemiparesis	Cranial nerve III, Cerebral peduncle
Benedikt	Oculomotor palsy	Tremors + Hemianaesthesia	Cranial nerve III, Red nucleus ± Medial longitudinal fasciculus, Spinothalamic tract
Claude's	Oculomotor palsy	Tremor and ataxia	Cranial nerve III, Red nucleus, Brachium conjunctivum
Nothnagel's	Oculomotor palsy and ataxia	Oculomotor palsy ± ataxia	Cranial nerve III, Brachium conjunctivum
Plus-minus lid	Ptosis	Lid retraction	CN III fascicles to the levator palpebrae muscle; Nucleus of posterior commissure

## **CONCLUSION**

The third cranial nerve provides an essential and invaluable guide in the accurate assessment of the neurological patient. An understanding of the various clinical presentations of its disorder is essential to accurately localize the cause of the deficit as well as the location of the offending lesion.

## **References**

1. Milanes-Rodriguez G, Ibañez-Valdés LdeF, Foyaca-Sibat H. Oculomotor nerve: Clinical anatomy. *The Internet Journal of Neurology*;2008; 10 (1)
2. Singh I. *Textbook of human neuroanatomy* (6th ed.). New Delhi: Jaypee Brothers Med Pub Ltd ; 2002; 99-115.
3. Green WR, Hackett E R, Schlezinger NS. Neuro-ophthalmologic evaluation of oculomotor nerve paralysis. *Arch. Ophthalmol*;1964; 72:154
4. Greenberg MS. Neurophthalmology. In: *Handbook of Neurosurgery* (5th ed). New York: Thieme; 2001; 579-580
5. Breen LA, Hopf HC, Farris BK, Gutmann L: Pupil-Sparing Oculomotor Nerve Palsy due to Midbrain Infarction. *Arch Neurol*; 1991;48:105-106
6. Kulkarni AR, Aggarwal SP, Kulkarni RR, Deshpande MD, Walimbe PB, Labhsetwar AS. Ocular manifestations of head injury: a clinical study. *Eye*; 2005; 19: 1257–1263
7. ACS Committee on Trauma. *Advanced Trauma Life Support Course for Physicians* (3rd edn.) Student Manual. Chicago: American College of Surgeons; 1993
8. Thurman DJ, Jeppson L, Burnett CL, Beaudoin DE, Rheinberger MM, Sniezek JE. Surveillance of traumatic brain injury in Utah. *West J Med*; 1996; 165: 192–196.
9. Warden D. Military TBI during the Iraq and Afghanistan wars. *Journal of Head Trauma Rehabilitation*; 2006; 5: 398–402
10. Odebode TO, Ademola-Popoola DS, Ojo TA, Ayanniyi AA. Ocular and visual complications of head injury. *Eye*; 2005; 19: 561–566
11. Afifi AK, Bergman RA., editors. *Functional Neuroanatomy: Text and Atlas* (2nd ed.) McGraw-Hill; 2005; 150-152

**Author Information**

**Taopheeque Bamidele Rabiou, M.B.Ch.B**

Department of Neurological Surgery, University College Hospital