

# Abnormal Neurophysiologic Findings In A Patient After Heart Transplantation With Respiratory Insufficiency Following Encephalitis

G Litscher, G Schreyer

## Citation

G Litscher, G Schreyer. *Abnormal Neurophysiologic Findings In A Patient After Heart Transplantation With Respiratory Insufficiency Following Encephalitis*. The Internet Journal of Neurosurgery. 2000 Volume 1 Number 2.

## Abstract

Multiparametric neuromonitoring was performed in a 60-year-old patient after heart transplantation and respiratory insufficiency following encephalitis. Abnormal findings were seen in the brainstem auditory evoked potential interpeak latencies (IPL) at the level of the mid to upper brain stem (wave IV-V IPL), which were significantly increased on both sides. This neurophysiologic abnormality could be in context to previous findings in a girl with the central alveolar hypoventilation syndrome<sup>1</sup> and is consistent with findings in patients with respiratory insufficiency following encephalitis<sup>2</sup>.

## INTRODUCTION

Modern biomedical technology has an important role in intensive care units (ICU). Especially neurophysiologic brain function monitoring is receiving increasing attention. The recording of brain stem auditory evoked potentials (BAEPs) is a neurophysiologic study of brain stem function. This report describes abnormalities of BAEPs and of 40 Hz auditory stimulus induced oscillations in a 60-year-old male intensive care patient.

## METHODS

### BAEP-RECORDINGS AND 40 HZ OSCILLATIONS

BAEPs were recorded with a multivariable monitoring system according to standard procedures<sup>3</sup>. Acoustic stimulation was performed with alternating clicks with a duration of 0.2 ms. The interstimulus interval varied randomly between 90 and 110 ms. The intensity was 85 dB SPL (sound pressure level) and the clicks were presented monaurally to the right and left ear through small earphones (type: YE-1023, Nihon Kohden). The non-stimulated ear was masked with white noise. BAEPs were recorded from CZ-Cb1 and CZ-Cb2 with Fpz as ground electrode. The filter bandpass was 250 Hz - 3 kHz (-6 dB points, 12 dB/octave). The interelectrode impedances were less than 3 kOhm. Analysis time was 10 ms and the sampling rate was 5.2 kHz.

Acoustic stimuli for 40 Hz oscillations<sup>4,5</sup> were applied

monaurally in the form of clicks with a duration of 0.2 ms in an alternating mode and an intensity of 85 dB SPL. The contralateral ear was masked with white noise (45 dB nHL). In addition to the BAEP and the 40Hz oscillations, a 2-channel EEG was performed and assessed for quality control. All evoked potentials and the EEG were recorded with gold-cup electrodes (Grass E5GH), which were applied with a conducting electrode paste (Grass EC2). The filters were set for the 40Hz responses of 0.5-200 Hz. The bandwidth of the EEGs was 0.5-30 Hz.

The different potentials and the EEG were recorded simultaneously and continuously with the Viking System IV (Nicolet, EMS, Korneuburg, Austria).

The stimulus-induced 40Hz oscillations, ~1000 as well as ~2000 of the BAEP single responses were averaged and the resulting curve was reproduced at least twice. The latency of waves I-V (BAEP) and the mean amplitude of the 40Hz oscillations were assessed.

## CASE REPORT

Heart transplantation was performed on a 60-year-old male patient suffering from congestive cardiomyopathy. Two months after surgery, the patient developed a febrile infection of unknown genesis. Two weeks later, increasing confusion with a rapid decrease in consciousness peaking in a comatose state occurred. The patient was intubated and artificially respired.

## Abnormal Neurophysiologic Findings In A Patient After Heart Transplantation With Respiratory Insufficiency Following Encephalitis

The initial neurologic examination to clarify the origin of the cerebral symptoms indicated cephalaea of indistinct genesis and mild hemiparesis on the left after apoplexy 1 1/2 years earlier. The following CT showed an expansive process in the intracerebral and particularly extracerebral subarchnoid spaces and calcification in the choroid plexus region. Further cerebral structures were without pathological findings.

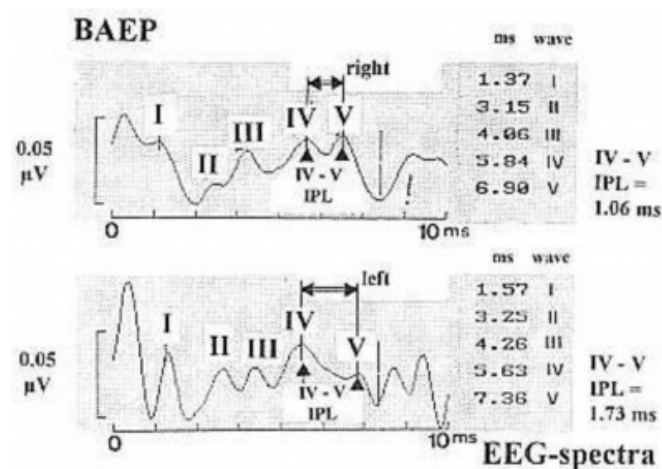
One week later, the patient underwent further neurologic examination. This time the patient showed symptoms of an organic neuropsychologic disorder primarily caused by herpes simplex virus encephalitis. The CT done after the second neurologic examination showed massive deterioration of the patients condition compared to the first CT. Massive hypodensities in the pons and base of the cerebral peduncle as well as in the left temporopolar region and middle mediadivision were visible. These findings correlate to the clinical picture of encephalitis with multiple infarctions. Further, a massive supratentorial, bihemispherical cerebral edema and supratentorial hydrocephalus could be observed.

At the same time, no reaction to pain (to pressure at the nail matrix) was detectable. Pupils were isocor and divergent and bilateral light reflexes were negative. The corneal reflex could be triggered on both sides.

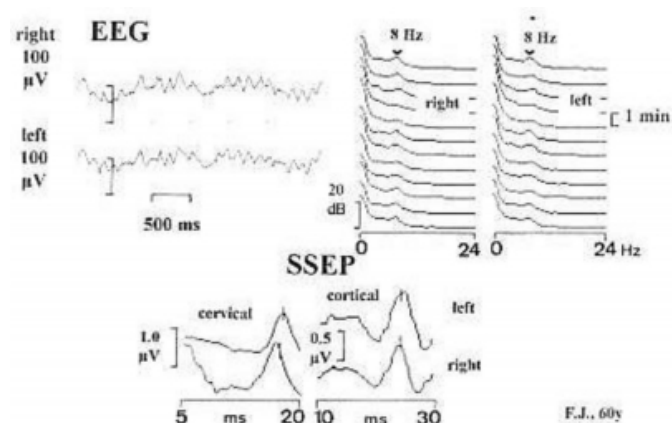
The results of the first EEG and evoked potentials are shown in Figure 1.

### Figure 1

Fig. 1: Results of the neurophysiologic parameters from the 60-year-old patient.



### Figure 2

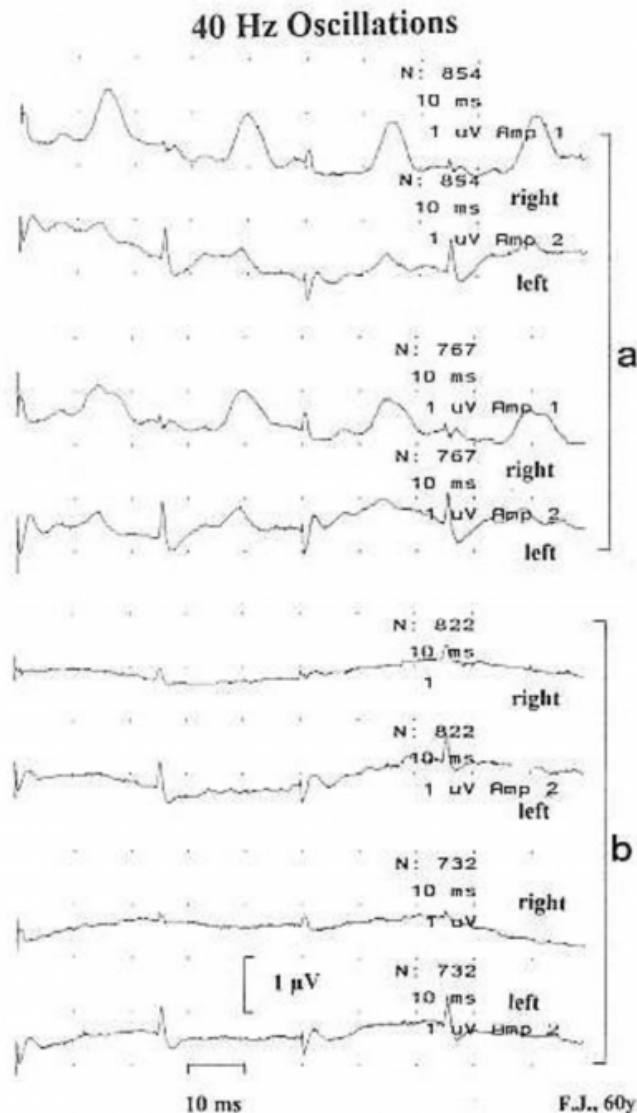


Waves I to V of BAEPs were seen in both the recording of the right and of the left side. The most prominent finding was that IPL IV-V were significantly prolonged (left: 1.73 ms; right: 1.06 ms).

Auditory induced 40 Hz oscillations showed amplitudes within the normal range on the right side at the first measurement (Fig. 2a, first and third trial). However, on the left side amplitudes were markedly reduced (Fig. 2a; second and fourth trial).

**Figure 3**

Fig. 2: 40 Hz oscillations after stimulation of the right and left ear at two different measuring times (a and b)



EEG showed dominant slow wave activity, but also a peak in compressed spectral array at 8 Hz on the left and right hemisphere (see Fig. 1, middle panel).

Short latency somatosensory evoked potentials (SSEP) showed increased latencies N17 (cervical component at C2) and N23 (cortical components) on both sides (Fig. 1, bottom).

Two days later, a control CT was done. The CT showed diffuse medullar hypodensities in both cerebral hemispheres as well as at the brain stem, unchanged diffuse cerebral swelling on both sides, reduction of the expansive process in

the intracerebral subarchnoid space and a new area of bleeding in the right hippocampus (~ 7 mm in diameter). Simultaneous control measurements of BAEP confirmed the significant increase in IV-V interpeak latency.

The patient died 6 days after the first monitoring procedure. The post mortem examination confirmed encephalitis in addition to other clinical findings.

## DISCUSSION

The recording of neurophysiological parameters is a standard method in ICUs. However, less attention was performed on the interpeak-latency of wave IV to V in the past. There are only few reports in the literature to this problem<sup>1,2</sup>. Schwarz et al.<sup>2</sup> studied artificially ventilated patients with respiratory insufficiency resulting from severe inflammatory encephalopathies and found a significant prolongation of wave III in addition to various abnormal BAEP patterns of the IV/V complex. They concluded that because the auditory pathways are in the near vicinity of the respiratory control centers in the brainstem, the electrophysiologic abnormalities of wave III and especially the IV/V complex may be a reflection of disturbed central control of ventilation. The abnormal BAEP findings in our patient suggests also parallel dysfunction in BAEP and central respiratory control in encephalitis with respiratory insufficiency. However, it is also possible that damage to the respiratory centers led to hypoxia which secondarily affected the BAEP generators<sup>2</sup>.

## ACKNOWLEDGEMENTS

The study was supported by the Austrian National Bank (project 8134).

## References

1. Litscher, G., Schwarz, G., Reimann R. (1996) Abnormal brainstem auditory evoked potentials in a girl with the central alveolar hypoventilation syndrome. *Intern J Neurosci*, 87, 113-117.
2. Schwarz, G., Litscher, G., Rumpl, E., Pfuerscheller, G., Reimann R. (1996) Brainstem auditory evoked potentials in respiratory insufficiency following encephalitis. *Intern J of Neurosci*, 84, 35-44.
3. Litscher, G. (1995) Continuous brainstem auditory evoked potential monitoring during nocturnal sleep. *Intern J Neurosci*, 82, 135-142.
4. Litscher, G. (Ed.) *Monitoring of stimulus-induced 40 Hz brain oscillations*. Pabst Science Publishers, Lengerich, 1998.
5. Litscher, G. (1995) Middle latency auditory evoked potentials in intensive care patients and normal controls. *Intern J Neurosci*, 83, 253-267.

**Author Information**

**Gerhard Litscher, Ph.D.**

Biomedical Engineering, Anesthesiology and Critical Care, University of Graz

**Georg Schreyer, MD**

Biomedical Engineering, Anesthesiology and Critical Care, University of Graz