

Hemorrhagic infarction due to transverse sinus thrombosis mimicking cerebral abscesses

N Barua, M Bradley, N Patel

Citation

N Barua, M Bradley, N Patel. *Hemorrhagic infarction due to transverse sinus thrombosis mimicking cerebral abscesses*. The Internet Journal of Neurosurgery. 2008 Volume 5 Number 2.

Abstract

Cerebral venous sinus thrombosis is an uncommon condition which remains a diagnostic challenge for the clinician and radiologist. The wide spectrum of clinical and radiological manifestations can result in delayed or misdiagnosis. The authors present the case of a 50-year-old woman with headaches following an episode of mastoiditis. CT imaging revealed temporal ring-enhancing lesions which were thought to represent cerebral abscess formation and the patient proceeded to image-guided aspiration. MR venography, biopsy and histological examination confirmed the diagnosis of hemorrhagic infarction secondary to transverse sinus thrombosis.

CASE REPORT

Cerebral venous sinus thrombosis remains a challenging condition due to its variability in clinical and radiological manifestation and relative rarity. Presenting features can range from headache to neurological deficit, seizures and coma². Women are more commonly affected than men, and recognised associations include pregnancy and use of the hormonal contraceptive pill³. Magnetic resonance venography has superseded invasive angiography as the gold standard investigation, and is more sensitive than CT alone. Hemorrhagic infarction due to elevated venous and capillary pressure is estimated to occur in 10-50% of cases, and usually occurs in the adjacent cortex and white matter⁶. We present a histologically confirmed case of hemorrhagic infarction due to transverse sinus thrombosis, with ring-enhancing lesions on CT scanning which were initially thought to represent cerebral abscesses.

HISTORY AND EXAMINATION

A 50-year-old woman presented to her GP with a 3-day history of pain behind the left ear following an upper respiratory tract infection. On eliciting tenderness of the mastoid, the GP made a clinical diagnosis of mastoiditis and prescribed a course of oral antibiotics. As the patient's symptoms persisted, a second course of antibiotics were prescribed. The patient reported improvement in her ear pain but over the following weeks she developed progressively severe headaches which were noted to be worse in the morning. An outpatient CT scan of the brain was performed,

which revealed an area of subcortical hypodensity in the left temporal region. (Fig. 1a + 1b).

Figure 1

Figure 1a: CT images. Non-contrast enhanced CT images reveal left posterior temporal hypodensity suggestive of transverse sinus thrombosis.

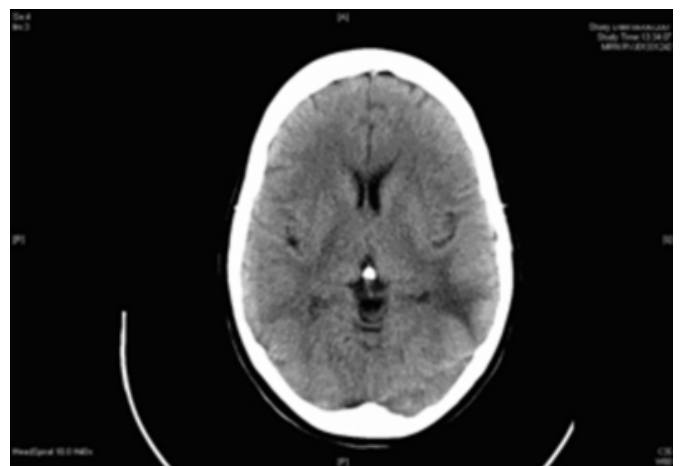
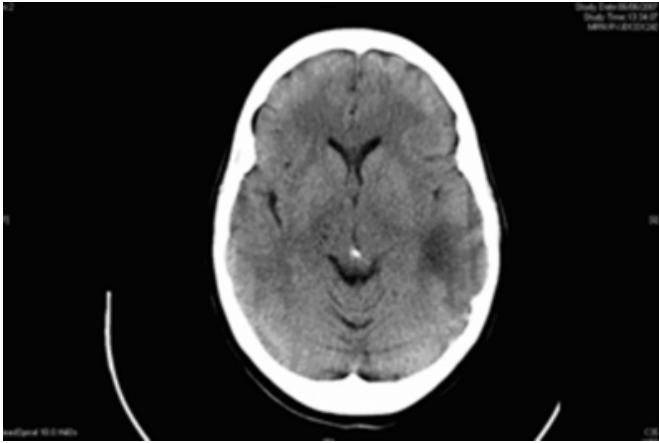


Figure 2



In view of the history of an infective process as well as the characteristic CT findings, contrast-enhanced CT and CT venography were performed, which revealed left temporal ring-enhancing lesions (Fig. 2a + 2b) and a filling defect in the left transverse venous sinus (Fig. 2c).

Figure 3

Figure 2abc: CT imaging. Contrast-enhanced CT scanning revealed left temporal ring-enhancing lesions, and CT venography confirmed a filling defect in the left transverse sinus extending into the sigmoid sinus and jugular bulb.

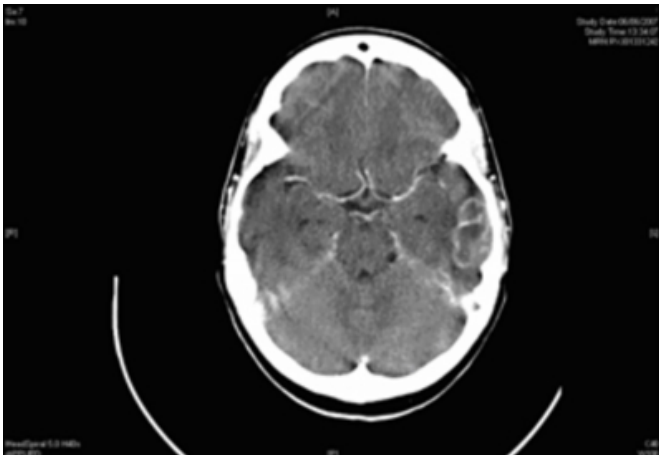


Figure 4

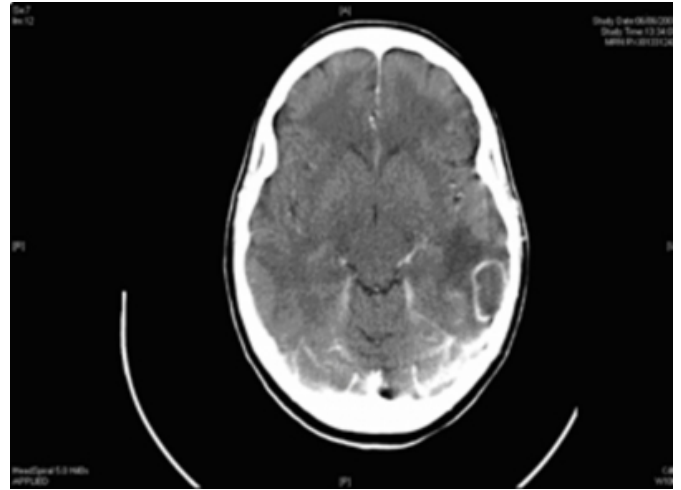
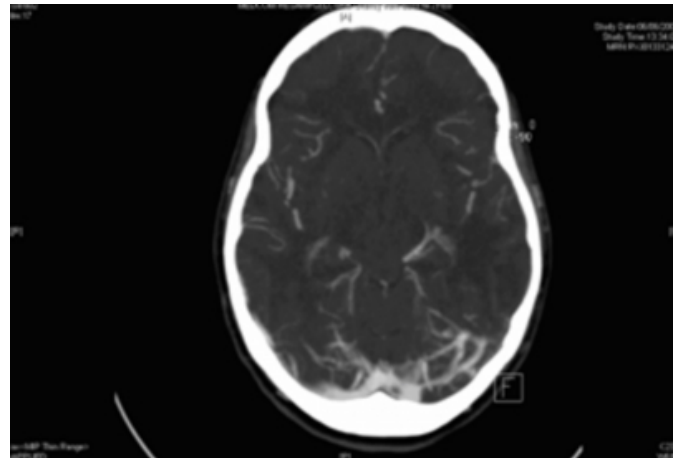


Figure 5



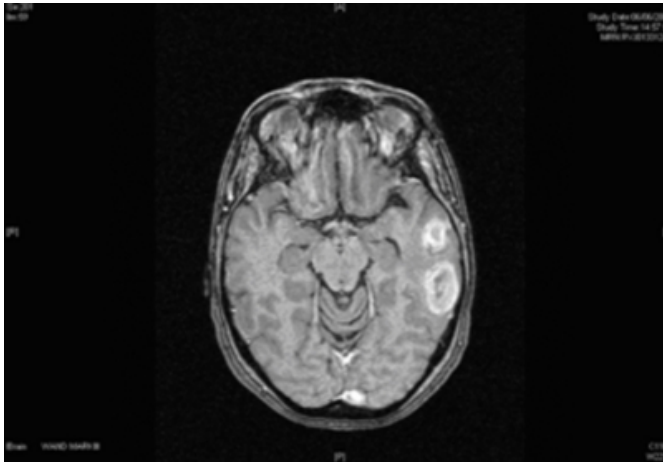
The CT imaging findings and patient history were consistent with a diagnosis of cerebral abscess formation and transverse sinus thrombosis as a consequence of mastoiditis. No elevation of serum inflammatory markers was found, but this was considered to be a result of recent antibiotic treatment. In order to isolate the infective organism the patient was prepared for burr hole aspiration of the abscesses.

OPERATION

To facilitate image-guided aspiration of the ring-enhancing lesions using the Stealth neuro-navigation system (Medtronic SNT, Tennessee), a pre-operative Stealth sequence MRI scan was performed, which once again confirmed the presence of ring-enhancing lesions (Fig.3).

Figure 6

Figure 3: MR image. sequence MRI confirming the location of the ring-enhancing lesions and used for intra-operative neuro-navigation.



Intra-operatively no pus was found, but hemorrhagic and necrotic material within a pseudo-capsule was excised and sent for microbiological, cytological and histological assessment. Gram staining revealed only scanty white cells and no organisms. Cytological examination also confirmed the absence of tumour cells.

POSTOPERATIVE COURSE

The absence of pus or tumour cells on initial microscopy led to the patient undergoing formal MR imaging and venography. This more comprehensive study demonstrated low signal material within the walls of the lesions on T2 weighted images, which was suggestive of haemosiderin deposition and consistent with recent hemorrhage (Fig. 4a). As this investigation was undertaken on the first post-operative day, sufficient time had not passed for hemosiderin deposition to be the result of bleeding due to surgery. This examination also better demonstrated thrombus within the left transverse sinus extending into the sigmoid sinus and proximal internal jugular vein (Fig. 4b + 4c). The patient was commenced on intravenous heparin, which was later converted to an oral anticoagulant. Her headaches resolved over a one week period and she was discharged home with no neurological deficits.

Figure 7

Figure 4abc: MR imaging. Formal MRI scanning revealed the presence of hemosiderin and extension of the thrombus as far as the proximal jugular vein.

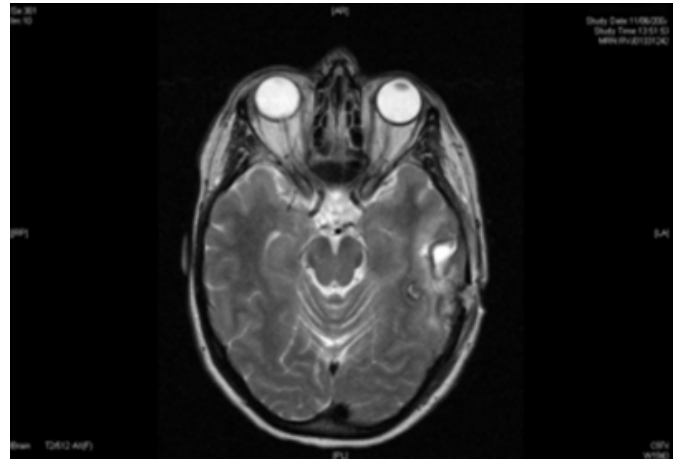


Figure 8

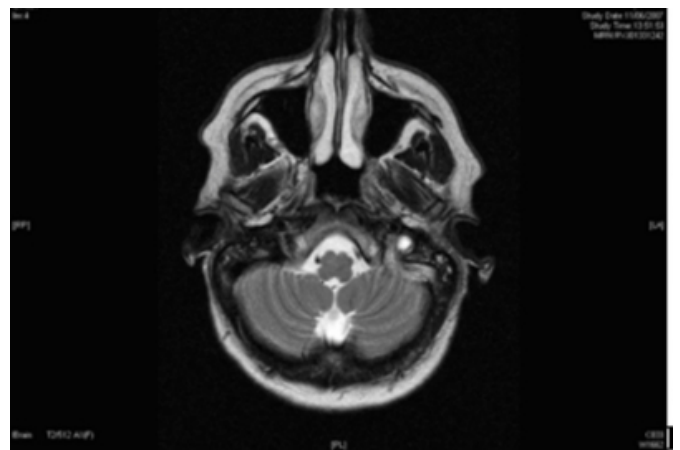
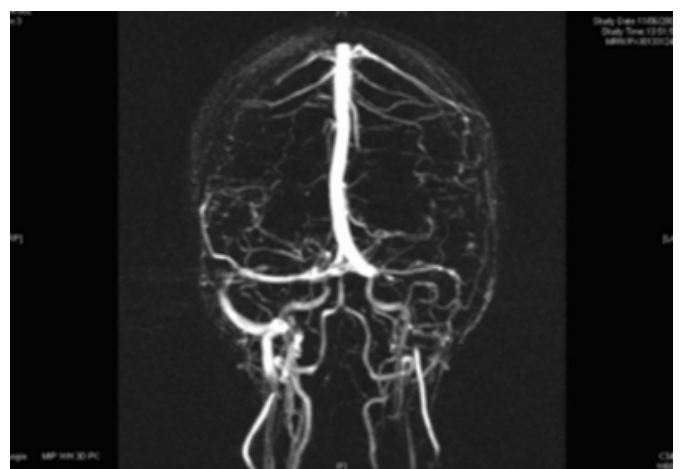

Figure 9



HISTOPATHOLOGICAL FINDINGS

The excised tissue and capsule were processed and stained. A diagnosis of hemorrhagic venous infarction was confirmed. No evidence of infective or malignant disease was demonstrated.

DISCUSSION

This case demonstrates some of the potential pitfalls in the diagnosis and management of patients with cerebral venous thrombosis as a result of the wide variety of clinical and radiological manifestations and their insidious onset. Hemorrhagic infarction is a relatively rare but potentially devastating outcome, and unilateral lobar hemorrhage associated with extensive oedema and mass effect has been reported⁷. In delayed presentations a hematoma is iso- or hypo-dense on CT scanning, and may also demonstrate ring-enhancement on administration of contrast thereby mimicking an infective or malignant process.

Although the clinical presentation of cerebral venous sinus thrombosis is highly variable, several typical symptom groups have been described¹ – headache with papilloedema and visual disturbance; headache with progressive neurological deficit; and seizures often followed by a Todd's paresis. Thrombosis of the superior sagittal sinus classically presents with bilateral or alternating signs, and cavernous sinus thrombosis with chemosis, proptosis and ophthalmoplegia. A minority of patients present with a progressive coma as a consequence of thrombus progression into deep veins.

Univariate analysis has identified prognostic factors associated with poor outcome and these include papilloedema, reduced conscious level, coma, older age, intracerebral hemorrhage and involvement of the straight sinus³. A multivariate regression analysis in the same study identified hemorrhage as a statistically significant predictor of poor outcome.

MRI and MRV have replaced invasive venography as the investigation of choice, and have sufficient sensitivity to be utilised as the sole investigation for cerebral venous thrombosis^{8,9}. However, it is likely that CT imaging will be the first-line investigation in most cases – which may be normal in 10 to 20% of patients with proven thrombosis¹. CT venography may become more widely used as CT technology improves and evidence emerges demonstrating its efficacy in visualising sinuses and smaller veins with low flow⁵.

It is arguable as to whether formal pre-operative MRI

scanning and MR venography, as opposed to a limited Stealth sequence, would have resulted in the avoidance of surgery in this patient, as the finding of hemosiderosis in the walls of the lesions was more consistent with a diagnosis of hemorrhagic infarction than with abscess. Conversely it could be argued that in the presence of a recent history of a regional infective process and ring-enhancing lesions on CT, aspiration was mandatory.

CONCLUSIONS

A high index of clinical suspicion for cerebral abscess is required in any patient with signs and symptoms of raised intracranial pressure and a recent history of an infective process⁸. Cerebral abscess is a treatable condition which can progress rapidly if misdiagnosed and if there is any diagnostic doubt aspiration or surgical exploration is mandatory. The variability in the clinical and radiological manifestations, insidious onset of symptoms, and relative rarity of cerebral venous sinus thrombosis makes this condition a diagnostic challenge. One possible consequence of thrombosis is hemorrhagic infarction, which is recognised as a poor prognostic indicator. A delay in recognition can result in iso- or hypo-dense and ring-enhancing appearances on CT scanning which can be misdiagnosed as infective or malignant processes. In order to maximise the clinician's ability to correctly diagnose cerebral venous thrombosis and its sequelae the authors advocate MRI and MR venography.

References

1. Allroggen H, Abbott RJ. Cerebral venous sinus thrombosis. *Postgrad Med J* 76: 12-15, 2000
2. Bousser MG, Chiras J, Borjes J, Castagne P. Cerebral venous thrombosis - a review of 38 cases. *Stroke* 16: 199-213, 1985
3. de Bruijn SFT, de Haan RJ, Stam J. Clinical features and prognostic factors of cerebral venous sinus thrombosis in a prospective series of 59 patients. *J Neurol Neurosurg Psychiatry* 70: 105-108, 2001
4. de Bruijn SF, Stam J, Koopman MM, Vandenbroucke JP. Case-control study of risk of cerebral sinus thrombosis in oral contraceptive users who are cautious of hereditary prothrombotic conditions. *BMJ* 316: 589-592, 1998
5. Ozsvath RR, Casey SO, Lunstrin ES, Alberico TLA, Hassankhani A, Patel M. Cerebral venography: comparison of CT and MR projection venography. *AJR* 169: 1699-1707, 1997
6. Provenzale JM, Joseph GJ, Barboriak DP. Dural sinus thrombosis: findings on CT and MRI imaging and diagnostic pitfalls. *AJR* 170: 777-783, 1998
7. Singh T, Chakera T. Dural sinus thrombosis presenting as unilateral lobar haematomas with mass effect: an easily misdiagnosed cause of cerebral haemorrhage. *Australasian Radiology* 46(4): 351-365, 2002
8. Stam J. Thrombosis of the cerebral veins and sinuses. *NEMJ* 352: 1791-1798, 2005
9. Vogl TJ, Bergman C, Villringer A, Einhaupl KM, Lissner J, Felix R. Dural sinus thrombosis: value of venous MRA for

diagnosis and follow-up. AJR 162: 1191-1198, 1994

Author Information

Neil Barua, MRCS

Dept. of Neurosurgery, Frenchay Hospital

Marcus Bradley, FRCR

Dept. of Neuroradiology, Frenchay Hospital

Nitin Patel, FRCS(SN)

Dept. of Neurosurgery, Frenchay Hospital