Verrucous Carcinoma Of The Oral Cavity: Case Report

N Kaushal, N Madan

Citation

N Kaushal, N Madan. *Verrucous Carcinoma Of The Oral Cavity: Case Report*. The Internet Journal of Geriatrics and Gerontology. 2009 Volume 6 Number 1.

Abstract

Ackerman first recognized verrucous carcinoma as a distinct entity in 1948. Although it occurs in other anatomic sites, most intraoral cases involve buccal mucosa, alveolar mucosa and gingiva. The cells of verrucous carcinoma do not show dysplastic features and mitosis is also absent. The recurrence rate after treatment of verrucous carcinoma is high due to the dysplasia left close to verrucous carcinoma. A case of male patient is being presented who was diagnosed as a case of verrucous carcinoma.

INTRODUCTION

In 1896, Buschke, and subsequently in 1925, Buschke and Loewenstein, described a penile lesion which appeared benign cytologically, yet which behaved in a malignant fashion. Due to its histologic similarity to the benign condyloma acuminatum, this tumor has been termed the giant condyloma acuminatum or the Buschke-Loewenstein tumor.[1] This was the genital form of verrucous carcinoma. In 1948, Lauren V. Ackermann first described this neoplasm of the oral mucous membrane, which is now also know as Verrucous Carcinoma of Ackermann or Ackermann's tumor.[2]

Tobacco chewing is a significant etiological factor for its development. Lesions often develop at the site where the tobacco is placed habitually. These are the same factors that predispose individuals to the development of premalignant lesions such as, leukoplakia, submucous fibrosis, and erythroplakia.

CASE REPORT

A 65 year old male patient reported with a chief complaint of growth on the right corner of the mouth for the last 2 years. The patient had a history of tobacco chewing 3-4 times a day for the last 30 years. During clinical examination an exophytic reddish white growth was seen intra orally involving the right buccal mucosa and extending extra orally to the corner of mouth.

RESULTS

The histopathological examination of the tissue biopsied revealed it to be case of verrucous carcinoma with numerous dysplastic features. The hematoxylin and eosin stained section showed epithelium and connective tissue. The epithelium was hyperplastic stratified squamous type which was parakeratinised in nature (figure 1). The epithelium showed seep clefts which showed keratotic plugging (figure 1). The rete ridges were are broad and blunt with a pushing margin and an intact basement membrane (figure 1). There was a very dense inflammatory cell infiltrate consisting of lymphocytes and plasma cells (figure 2).

DISCUSSION

Verrucous carcinoma is an uncommon but distinct variety of well differentiated squamous cell carcinoma first delineated by Ackerman in 1948[3].The term verrucous carcinoma refers to those exophytic mucosal or cutaneous squamous tumors that are heaped above the epithelial surface with a papillary micronodular surface and pushing margins[4].Predominantly being a squamous mucosal lession, verrucous carcinoma may also be found on cutaneous surfaces. Whether the carcinoma occur in the upper aerodigestive tract (verrucous carcinoma), on the genitalia (condyloma acuminatum), or on extremities (carcinoma cuniculatum), they are essentially the same neoplasm with slow growing, locally invasive and nonmetastasizing behavior[3]. With respect to the upper aero digestive tract, where the verrucous carcinoma most often arises, the oral cavity, particularly the cheek mucosa, gingivae and retromolar areas, remains the most common site of origin[4].

The tumor may also be found on different sites including skin, paranasal sinus, bladder and anorectal region, male and female genitalia, sole of the foot, and ear[4]. It is often associated with long-term use of smokeless tobacco although examples occur among nonusers. Bethel nut chewing, poor

dental hygiene and Human Papilloma Virus (HPV) infection have been implicated in the development of oral verrucous carcinoma[4].

It accounts for 5% of all intraoral squamous cell carcinomas[5]. It is generally seen in elderly patients, the mean age of occurrence being 60-70 years, with nearly 75% of the lesions developing in males[6] as reported in this case report of a 65 year old male patient.

The macroscopic appearance of Ackerman's trumour depends on several factors like duration of lesion, degree of keratinization and the changes in adjacent mucosa. The fully developed carcinoma in an exophytic gray to red bulky lesion with a rough, shaggy, papillomatous surface[3]. The surface is usually heavily keratinised. The presence of keratin on an irregular moist mucosal surface gives the lesion its white, warty clinical appearance[7]. On the cut surface, it is firm or hard, tan to white, and may show keratin-filled surface clefts[8].

The development of verrucous carcinoma from proliferative lesions makes it likely that the tumor develops from a benign precursor. Thus, Hansen et al. described 10 histologic stages of proliferative verrucous leukoplakia, ranging from a persistant and slowgrowing benign unifocal, homogenous leukoplakia to a less differentiated squamous cell carcinoma. Batsakis et al. reduced the number of histologic stages to the following four: clinical flat leukoplakia without dysplasia, verrucous hyperplasia, verrucous carcinoma, and conventional squamous cell carcinoma[4].

Microscopically, verrucous carcinomas consist of thickened club shaped filiform projections lined with thick, well-differentiated squamous epithelium with marked surface keratinisation ("church-spire" keratosis)[9,10]. Parakeratin typically fills the numerous clefts or crypts (parakeratin plugs) between the surface projections[11] as was seen in this case report (figure 1)

The squamous epithelial cells in verrucous carcinomas are large and lack the usual cytologic criteria of malignancy[9].The histologic appearance of verrucous carcinoma is that of a benign appearing squamous cell proliferation and consists of uniform cells without dysplastic features or mitosis[10,12]. The differentiation of verrucous carcinoma from a conventional squamous cell carcinoma is based on the presence or absence of cytologic abnormalities[10].

The lower border of the lesion is well defined and formed by blunt rete processes which indent but do not invade the underlying tissues[9]. These findings were similar to the findings of this case report which also showed blunt rete ridges which did not invade the underlying tissues (figure 1).

The inflammatory reaction in the stroma consists of lymphocytes, plasma cells and histiocytes that tend to limit the tumor mass[4].

Difficulties remain as to the appropriate classification of those lesions with dominant features of verrucous carcinoma which also contain small foci of squamous cell carcinoma. In 20% of verrucous carcinoma coexistent foci of less-differentiated squamous cell carcinoma could be found. A non-verrucous squamous cell carcinoma (of varying degree and differentiation) that arises synchronously with the verrucous carcinoma and in the same microscopic fields is defined by Batsakis et al as a ''hybrid verrucous carcinoma'', which must be separated from papillary squamous carcinoma[4].

Differential diagnosis includes verrucous hyperplasia, well-differentiated squamous cell carcinoma, papillary squamous cell carcinoma, and squamous papilloma. Lack of atypia helps to rule out the conventional squamous cell carcinoma and papillary squamous cell carcinoma[8].

Figure 1

Figure 1: Epithelial clefts with parakeratotic plugging. 10X magnification. Hematoxylin and Eosin stain.

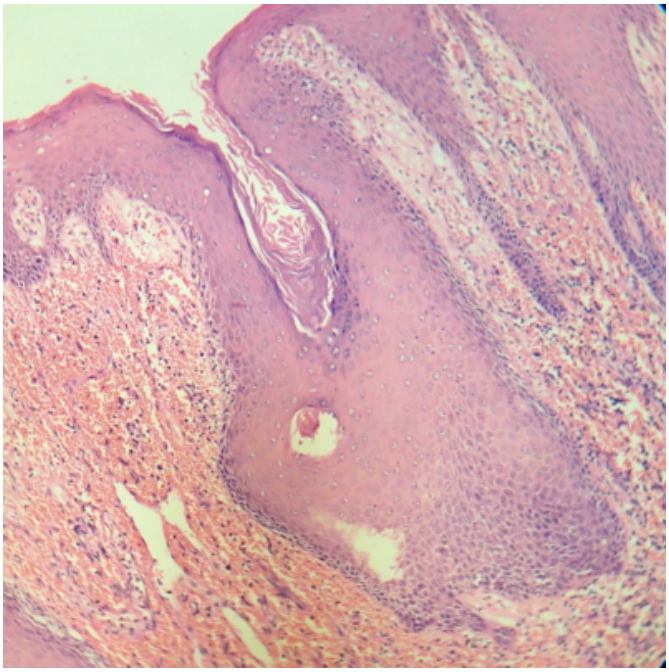

Figure 2

Figure 2: Dense inflammatory cell infiltrate chiefly lymphocytes and plasma cells. 10X magnification. Hematoxylin and Eosin stain.

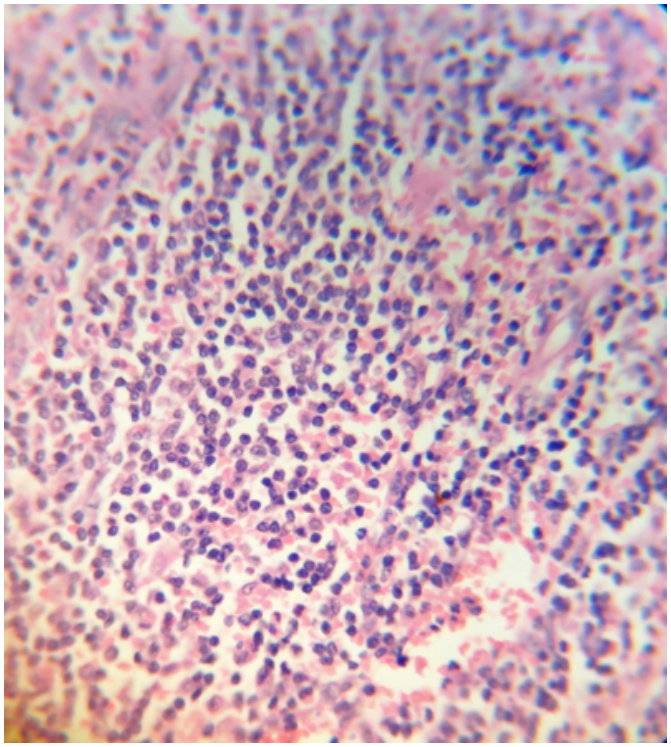

CONCLUSION

To date histological evaluation remains a problem as benign microscopic appearance is controversial to tumor's destructive clinical behavior[4]. Verrucous carcinoma is characterized by a high frequency of initial misdiagnosis. This emphasizes the need for close cooperation between the pathologist and the clinician in order to establish the diagnosis of verrucous carcinoma. An adequate, full thickness biopsy specimen must be taken when a clinician suspects a verrucous carcinoma; moreover, multiple biopsies may be needed to rule out a conventional squamous cell component in a verrucous carcinoma[8]. No matter what the treatment is, the rate of local recurrences is said to be high ranging from 30% to 50% and not unusually is the result of inadequate surgery because of the size of the tumor and left dysplasia close to the verrucous carcinoma[4].

References

1. Prioleau. P.G, Santa Cruz D.J and Meyer J.S : Verrucous carcinoma: A light and electron microscope auto radiographic and immunofluorescence study. Cancer.1980; 45: 2849.
2. Walvekar R.R: Verrucous carcinoma of the oral cavity: A clinical and pathological study of 101 cases. Oral Oncology 2009; 45:47– 51.
3. Singh K, Kalsotra P, Khajuria R and Manhas M: Verrucous carcinoma (Ackerman's Tumor) of mobile tongue. JK Science 2004; 6(4): 220-222.
4. Depprich R.A, Handschel J.G, Fritzemeier C.U, Engers R and Kubler N.R: Hybrid verrucous carcinoma of the oral cavity: A challenge for the clinician and the pathologists. Oral Oncology Extra; 2006; 42: 85-90.
5. Regezi A.J, Sciuba J.J and Jordan R.C.K: Oral pathology clinical pathological correlations. 5th edition. St. Louis Missouri: Saunders Elsvier; 2008.
6. Rajendran R: Benign and malignant tumors of the oral cavity In: Rajendran R, Sivapathasundaram B. Shafer's textbook of oral pathology. 5th edition. New Delhi: Elsevier; 2006: 309-356.
7. Varshney S, Singh J, Saxena R.K, Kaushal A and Pathak V.P: Verrucous carcinoma of larynx. Indian Journal of Otolaryngology and Head and Neck Surgery; 2004; 56 (1): 54-56.
8. Cardesa A and Slootweg P.J: Pathology of the head and neck. Germany: Springer Verlag Berlin Heidelberg; 2006.
9. Cawson R.A, Odell E.W and Porter S: Cawson's essentials of oral pathology and oral medicine, 7th edition. Edinburgh: Churchill Livingstone; 2002.
10. Bruce M, Wenig and Cohan J.M: General principles of management of head and neck cancer. In: Harrison LB, Sessions RB, Hong WK. Head and neck cancer: A multidisciplinary approach. 3rd edition. Philadelphia: Lippincott William & Wilkins; 2003: 30.
11. Neville B.W, Damm D.D, Allen C.M, and Bouquot J.E: Oral & Maxillofacial Pathology. 2nd edition. Philadelphia: W.B. Saunders; 2002.
12. Stokes S.M, and Castle C.J: Oral cancer: part II. Clinical update. 2004; 26(10).

Author Information

Nitin Kaushal, BDS, MDS
Senior Lecturer, Department of Oral Pathology, B.R.S. Dental College and Hospital

Natasha Madan
Professor, Department of Conservative Dentistry, PDM Dental College and Research Institute