

Role of 3D ultrasound in the diagnosis of rare case of angular pregnancy

H Elhalwagy, P Sinha

Citation

H Elhalwagy, P Sinha. *Role of 3D ultrasound in the diagnosis of rare case of angular pregnancy*. The Internet Journal of Gynecology and Obstetrics. 2008 Volume 11 Number 2.

Abstract

Angular pregnancy is a rare variety of cornual pregnancy (ectopic). It is a potentially life threatening condition and has impact on the future fertility. The diagnosis was confirmed by 3-D trans-vaginal ultrasound scan (USS). The treatment included diagnostic laparoscopy, attempted suction evacuation of pregnancy and combined with intramuscular methotrexate.

CASE REPORT

A 20 years old primigravida woman presented with lower abdominal discomfort with 6 weeks of amenorrhea. There was no past gynaecological history of clinical significance. Abdominal and pelvic examination revealed a bulky uterus with mild discomfort.

She had a 2D transvaginal ultrasound scan which has suspected cornual ectopic pregnancy. She was referred to the gynaecological emergency for the further management. Due to lack of symptoms, 3-D USS using Voulson expert, G.E machine. The findings confirmed an eccentrically placed gestational sac measuring 12X7X9 mm (fig 1). There was yolk sac with a fetal pole measuring 6 mm with positive fetal heart beat seen. The gestational sac was very small in comparison with the fetal pole. On reconstruction of the image using rendering technique, the gestational sac was found very close to the right uterine cornua (fig 2). Both adnexae appeared normal. The differential diagnoses were cornual and angular ectopic pregnancy. Her serum β hCG was 3533 IU/L.

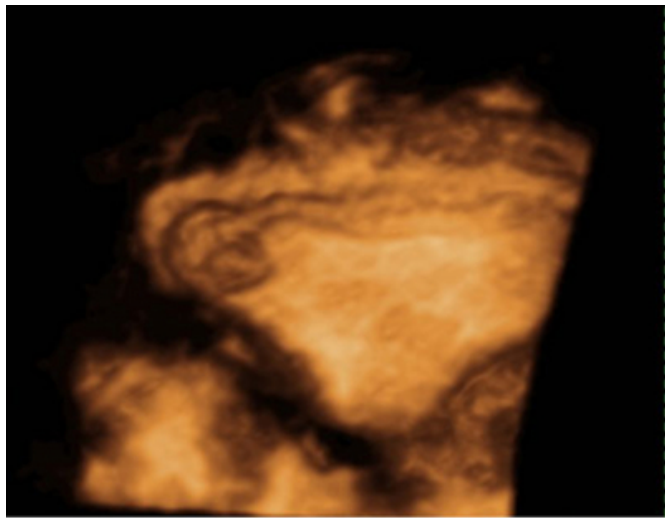
Figure 1

Fig (1) A two dimensional ultrasound image shows the eccentric location of the gestational sac with the foetal pole inside

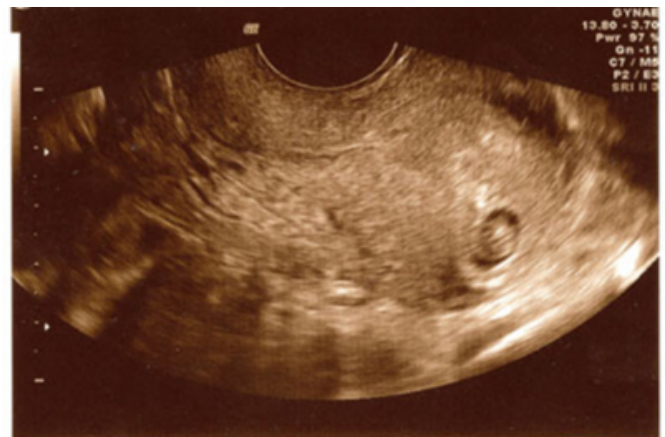

Figure 2

Fig. (2) A 3 –D ultrasound image reproduced with rendering represents the gestational sac near the right cornual angle of the uterus



The patient underwent diagnostic laparoscopy and guided evacuation of product of conception (ERPC) under general anaesthesia. On laparoscopy the right angle of the uterus was mildly enlarged (fig.3). Both tubes and ovaries were normal. Single dose of intramuscular methotrexate calculated according to the surface area of the body was given. The patient made an uneventful recovery. A TVS performed in the 2nd day of the operation revealed a remnant of product of conception. β hCG level 4 days later had dropped to 168 IU/L and 10 days later was less than 2IU/L.

{image:3}

DISCUSSION

The Angular pregnancy is distinct from the cornual pregnancy. Though it usually occurs in abnormal uterus both congenital and acquired, the pregnancy is always intrauterine and occur medial to the insertion of the fallopian tube .Most cases are asymptomatic and some cases present with abdominal pain and vaginal bleeding. Anatomically the angular pregnancy is implanted medial to the round ligament (1).

The maternal mortality rate is 1 per 1000 and this is twice

the mortality rate of tubal ectopic pregnancies. The portion of the uterine cavity medial to the cornu is a highly vascularised, muscular site that offers more support and distensibility to the embryo than any other portion of the fallopian tube. These anatomic features allow the gestation to advance much further into its development than when the embryo implants in other portions of the fallopian tube(2). The prognosis for the fetus is poor if pregnancy progress.

Few angular pregnancies develop into a normal uterus will rupture, but many of these pregnancies abort. Approximately a quarter results into a live birth. A third will develop into a cornual pregnancy and end up by uterine rupture(1). If it develops into cornual ectopic pregnancy, there is high risk of rupture at all gestational age, up to and including full term with surgical delivery (3).

While cornual ectopic pregnancy account for only 2-4% of all ectopic gestations, they cause a disproportionately high incidence of haemo-peritoneum and shock, and the mortality rate is approximately twice that of other types of ectopic pregnancies (4). Because of the undetermined sequelae of such pregnancies termination may be a wise approach to preserve patient future fertility potential.

The ultrasound findings of interstitial pregnancy have been described in previous reports as follows (3,4,5); A gestational sac surrounded by an incomplete or asymmetric uterine myometrial mantle is highly indicative of an angular pregnancy. A suggestive but nonspecific sign is an eccentrically located gestational sac. These findings are similar to those in the case described above, in which a gestational sac was identified at one cornu of the uterus.

References

1. Jansen R P.S, Elliott P M. Angular intrauterine pregnancy. *Obstetrics & Gynecology*1981;58:167-175
2. Kerr LM, Anderson DF. Angular pregnancy: A clinical entity. *Br Med J* 1:1113-4,1934.
3. Maliha WE, Gonella P, Degnan EJ. Ruptured interstitial pregnancy presenting as an intrauterine pregnancy by ultrasound. *Ann Emerg Med* 20:910-912,1991.
4. Coady DJ, Synder JR, Golstein SR, et al. Ultrasound diagnosis of interstitial pregnancy. *NY State J Med* 85:655-666,1985.
5. Jafri SZ, Loginsky SJ, Bouffard JA, et al. Sonographic detection of interstitial pregnancy. *JCU* 15:253-257,1987.

Author Information

H. Elhalwagy, MD, MRCOG

Associate Specialist in Obstetrics and Gynaecology

P. Sinha, FRCOG, MRCPI

Consultant in obstetrics and gynaecology