

# Factor XIII Concentrate Is Effective In Persistent Infection Of PEG Site.

S Furukawa, H Otsuki, K Fujino, T Tabata, K Matsumura, Y Eguchi

## Citation

S Furukawa, H Otsuki, K Fujino, T Tabata, K Matsumura, Y Eguchi. *Factor XIII Concentrate Is Effective In Persistent Infection Of PEG Site.* The Internet Journal of Gastroenterology. 2009 Volume 10 Number 1.

## Abstract

Percutaneous endoscopic gastrostomy (PEG) administration of enteral feeds is the most commonly used method of nutritional support for patients in the community. PEG tube was placed by the standard technique without difficulty, but persistent infection of PEG site was discovered. Plasma factor XIII is participated in tissue remodeling and wound healing. We administrated factor XIII concentrate, as a result, the PEG site healed without intervention. We report the effect on fibrinolysis of factor XIII concentrate.

## INTRODUCTION

Percutaneous endoscopic gastrostomy (PEG) is a surgical procedure for placing a tube for feeding without having to perform an open operation on the abdomen. The procedure is performed in order to place a gastric feeding tube as a long-term means of providing nutrition to patients who cannot productively take food orally. PEG administration of enteral feeds is the most commonly used method of nutritional support for patients in the community. Many stroke patients, for example, are at risk of aspiration pneumonia due to poor control over the swallowing muscles; some will benefit from a PEG performed to maintain nutrition. PEGs may also be inserted to decompress the stomach in cases of gastric volvulus (1)

In certain situations where normal or nasogastric feeding is not possible, gastrostomy may be of no clinical benefit. In advanced dementia, studies show that PEG placement does not in fact prolong life (2). Quality improvement protocols have been developed with the aim of reducing the number of non-beneficial gastrostomies in patients with dementia.

PEG takes less time, carries less risk and costs less than a surgical gastrostomy which requires opening the abdomen. PEG is a commonly-performed so there are many physicians with experience in performing the procedure. When feasible, PEG is preferable to a surgical gastrostomy.

The physician makes a small incision in the skin of the abdomen over the stomach and pushes a needle through the skin and into the stomach. The tube for feeding is pushed

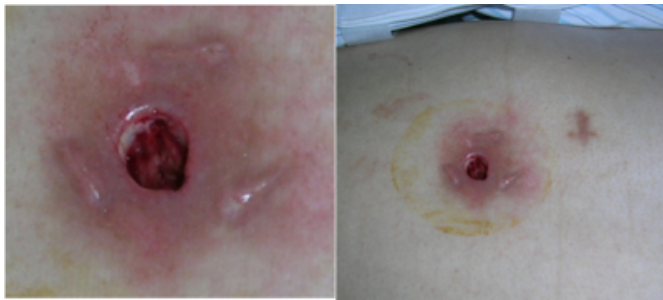through the needle and into the stomach. The tube is sutured in place to the skin. Possible complications include infection of the puncture site dislodgement of the tube, with leakage of the liquid diet that is fed through the tube into the abdomen, and clogging.

## CASE REPORT

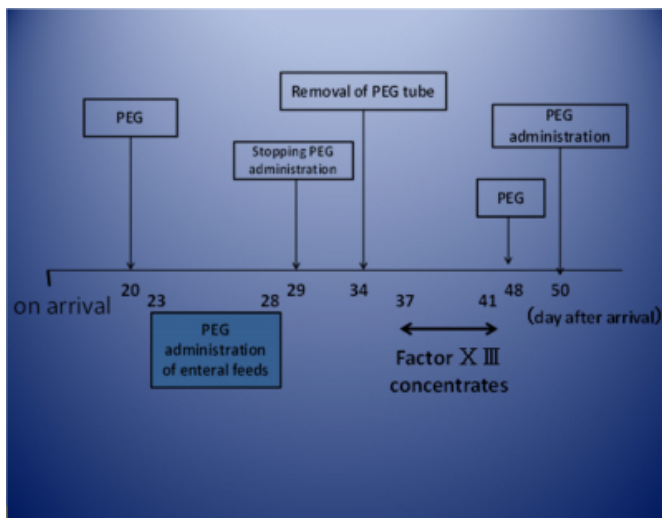
The patient was a 49-year-old man with cardio-pulmonary arrest. Resuscitation was likely to be successful. Sudden cardiac arrest occurred when the heart developed an arrhythmia that caused it to stop beating. He had a blood pressure of 59/34; and heart rate, 120 beats/min. The estimated Glasgow coma scale score was 3. His breathing was shallow. Pulmonary and abdominal examination were normal. The only available biological laboratory data were obtained at the moment of admission. These data showed the following values: serum total protein level of 6.7g/dl, serum albumin level of 4.2g/dl, and the factor XIII activity was 45%(normal, >70%).

PEG tube was placed by the standard technique without difficulty. But persistent infection of PEG site was discovered five days later. Despite several courses of therapy with different antibiotics and getting adequate nutrition, the fistula did not heal spontaneously (Fig 1). We removed PEG tube, and administrated intravenously a 240-U dose of factor XIII concentrate for 5 days. The fistula was minimized gradually and closed perfectly without infectious change. (Fig 2)

**Figure 1**



**Figure 2**



## DISCUSSION

Hyperfibrinolysis is a pathological state encountered in clinical settings like liver transplantation, cardiopulmonary bypass, or trauma, and can result in severe bleeding and breakdown of the hemostatic system. A group of proteins in the blood called clotting factors work together to make a patch called a fibrin clot. The fibrin clot keeps the platelet plug in place and expands to seal the hole in the blood vessel and stop the bleeding.

Factor XIII (fibrin stabilizing factor) has roles of stabilizing clot and cross-linking fibrin polymer, so the congenital factor XIII deficient patient has clot instability and delayed bleeding episodes. Factor XIII deficiency means we have less than the normal amount of factor XIII in our blood. Depending on the amount of factor XIII in your blood, we might have poor wound healing after a cut or surgery. It is also known as fibrin stabilization factor. It is needed for forming stable fibrin clots and for wounds to heal. It stabilizes blood clots by cross-linking the web of fibrin molecules (3,4). Blood coagulation factor XIII seems to play a key role in maintaining hemostasis and supporting tissue repair (5-7).

Several studies have shown that factor XIII stimulates fibroblast proliferation and migration in vitro, thus ameliorating wound healing (8-10).

Factor XIII may play a crucial role in connective tissue repair. Factor XIII activity was measured with the latex method, and should be increased to more than 70% of the normal value. (11) In the course of conservative treatment, the fistula did not heal spontaneously. We treated the patient with intravenous administration of a coagulation factor XIII concentrate (6 vials/day, Fibrogamin P<sup>®</sup>, CSL Behring, Marburg, FRG) for 5 days. Fibrogamin P<sup>®</sup> is a purified pasteurized Factor XIII concentrate produced by Aventis Behring in Marburg, Germany. Substitution of factor XIII seemed to result in a rapid improvement of wound healing. The sealing of the fistula with factor XIII concentrate represented an ideal alternative for treating this difficult complication. It shortened the time of closing, and should be considered in all cases of easy endoscopic access (12,13). This could also explain the beneficial effects of factor XIII in the treatment of refractory fistulas.

## CONCLUSION

Plasma factor XIII is participated in tissue remodeling and wound healing. We administrated factor XIII concentrate (6 vials/day, 5 days) with the following guidelines. We recognized the beneficial effects of factor XIII replacement therapy in patients with survival following pre-hospital cardiopulmonary arrest. We recommend factor XIII concentrate for persistent infections of the PEG site.

## References

1. Gauderer MW (2001). "Percutaneous endoscopic gastrostomy-20 years later: a historical perspective". *J. Pediatr. Surg.* 36 (1): 217-9. doi:10.1053/jpsu.2001.20058. PMID 11150469.
2. Murphy LM, Lipman TO (2003). "Percutaneous endoscopic gastrostomy does not prolong survival in patients with dementia". *Arch. Intern. Med.* 163 (11): 1351-3. doi:10.1001/archinte.163.11.1351. PMID 12796072.
3. Muszbek L, Adany R, Mikkola H, Novel aspects of blood coagulation factor XIII. I. Structure, distribution, activation and function. *Crit Rev Clin Lab Sci* 1996; 33: 357-421.
4. Dardik R, Solomon A, Loscalzo J et al. Novel proangiogenic effect of factor XIII associated with suppression of thrombospondin 1(TSP-1) expression. *Arterioscler Thromb Vasc Biol* 2003; 23: 1472-7.
5. Mosesson MW. The roles of fibrinogen and fibrin in hemostasis and thrombosis. *Semin Hematol* 1992; 29: 177-88.
6. Gerngrob H, Claes L, Experimental results in factor XIII and bone-healing. In: McDonagh J, Seitz R, Egbring R, editors. *Factor XIII. Second International Conference, Marburg.* Stuttgart: Schattauer; 1993. P. 278-80.
7. Ogawa T, Morioka Y, Inoue T, Takano M, Tsuda S. Involvement of blood coagulation factor XIII in burn healing

in the carbon tetrachloride-induced hepatic injury model in rats. *Inflamm Res* 1995; 44: 264-8.

8. Bruhn HD, Christophers E, Pohl J, Schoel G. Regulation der Fibroblastenproliferation durch Fibrinogen/Fibrin, Fibronectin und Faktor XIII. In: Schimpf K, editor. *Fibrinogen, Fibrin und Fibrinkleber*. Stuttgart: Schattauer; 1980. P. 217-26.

9. Ueyama M, Urayama T. The role of factor XIII in fibroblast proliferation. *Jpn J Exp Med* 1978; 48: 135-42.

10. Brown LF, Lanir N, McDonagh J, Tognazzi K, Dvorak AM, Dvorak HF. Fibroblast migration in fibrin gel matrices.

*Am J Physiol* 1993; 142: 273-83.

11. Mishima Y, Nagao N, Ishibiki K, Matsuda M, Nakamura N: Factor XIII in the treatment of postoperative refractory woundhealing disorders. Results of a controlled study. *Chirurg* 1984; 55: 803-808. German.

12. Oshitani N, Kitano A, Hara J, Suzuki N, Aoki T, Yasuda K, et al. Deficiency of blood coagulation factor XIII in Crohn's disease. *Am J Gastroenterol* 1995; 90: 1116-8.

13. Oshitani N, Nakamura S, Matsumoto T, Kobayashi K, Kitano A. Treatment of Crohn's disease fistula with coagulation factor XIII. *Lancet* 1996; 347: 119-20.

**Author Information**

**Satoshi Furukawa, MD.,Ph.D.**

1) The Department Of Intensive Care And Emergency, Shiga University of Medical Science

**Hideki Otsuki**

1) The Department Of Intensive Care And Emergency, Shiga University of Medical Science

**Kazunori Fujino**

1) The Department Of Intensive Care And Emergency, Shiga University of Medical Science

**Takahisa Tabata**

1) The Department Of Intensive Care And Emergency, Shiga University of Medical Science

**Kazuhiro Matsumura**

1) The Department Of Intensive Care And Emergency, Shiga University of Medical Science

**Yutaka Eguchi**

1) The Department Of Intensive Care And Emergency, Shiga University of Medical Science