

Cecal bleeding as a complication of conservative management of acute colonic pseudo-obstruction

D Holena, B Braslow

Citation

D Holena, B Braslow. *Cecal bleeding as a complication of conservative management of acute colonic pseudo-obstruction*. The Internet Journal of Emergency Medicine. 2008 Volume 5 Number 2.

Abstract

An 86 year-old man resented to the emergency department after falling down a flight of stairs with a chief complaint of lower back pain. Physical examination was unremarkable except for tenderness to palpation along the lumbar paraspinal musculature. Although a trauma workup revealed no visceral injury or bony fracture the patient had lower back pain severe enough to require intravenous hydromorphone and so he was admitted for pain management.

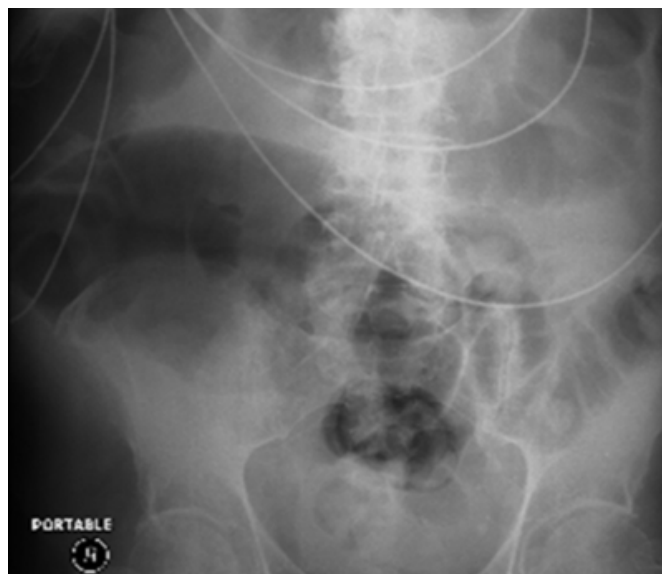
INTRODUCTION

An 86 year-old man resented to the emergency department after falling down a flight of stairs with a chief complaint of lower back pain. Physical examination was unremarkable except for tenderness to palpation along the lumbar paraspinal musculature. Although a trauma workup revealed no visceral injury or bony fracture the patient had lower back pain severe enough to require intravenous hydromorphone and so he was admitted for pain management.

Over the next 48 hours, the patient reported increasing abdominal distention and obstipation; an abdominal radiograph demonstrated a cecal diameter of 11 cm (Fig. 1).

Figure 1

Figure 1: Abdominal radiograph demonstrating a cecal diameter of 11 cm.



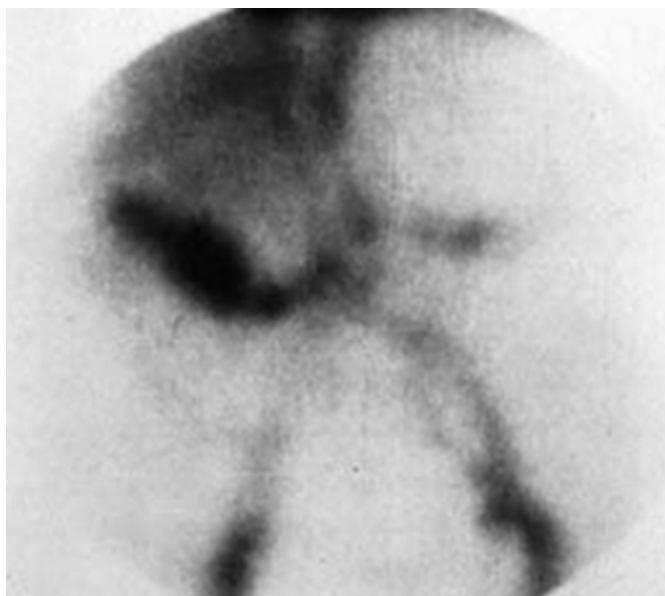Narcotics were discontinued and serum electrolytes were checked and found to be normal. Stool *C. difficile* toxin evaluation was negative, and a CT scan of the abdomen and pelvis utilizing oral contrast confirmed the extent of cecal dilation and demonstrated no distal obstruction. A presumptive diagnosis of acute colonic pseudo-obstruction was made and the patient was transferred to the intensive care unit to receive pharmacologic decompression. A rectal tube was placed and the patient received 2mg of intravenous neostigmine followed by some passage of flatus and liquid stool; however, a follow up abdominal radiograph demonstrated no change in cecal diameter. At this point the

patient was afebrile, hemodynamically stable, and had a normal white blood cell count. His abdominal exam was notable only for distention and very mild tenderness to palpation in the right lower quadrant. Because of the patient's advanced age and reassuring physiologic parameters, the decision was made to continue supportive therapy alone. Over the next 24 hours, he began to pass flatus and stool and his distention decreased significantly. A follow up abdominal radiograph demonstrated decompression of the cecum but was also notable for questionable thumbprinting of the right colon. The patient remained stable and without pain for the next 24 hours and was subsequently transferred from the ICU back to a regular floor.

The patient did well for the next days, reporting no abdominal pain and tolerating a regular diet. However, on hospital day 5 he passed a large amount of bloody stool associated with a hemoglobin drop of 2G/dl. Nasogastric tube lavage revealed only clear bile. After transfer back to the ICU and transfusion of 2 units of packed red blood cells, 99mTc-labeled RBC scintigraphy was performed, which demonstrated a blush in the right lower quadrant (Fig. 2).

Figure 2

Figure 2: 99mTc-labeled RBC scintigraphy with localization of bleeding in the right lower quadrant.



Subsequent colonoscopy revealed ulceration in the cecum with mild oozing and surrounding mucosal changes consistent with resolving ischemic colitis, which was confirmed by biopsy. The area of suspected hemorrhage was injected with an epinephrine preparation with therapeutic success. The subsequent hospital course was uneventful.

DISCUSSION

Colonic pseudo-obstruction was first described by Ogilvie in 1948 and is characterized by acute dilation of the colon in the absence of mechanical obstruction [1]. The pathophysiology of acute colonic pseudo-obstruction has not been definitively characterized, but is felt to involve perturbation of the autonomic nervous system supplying the colon [2]. In a review of 400 cases of acute colonic pseudo-obstruction, trauma was the underlying cause in 11% of cases; other common causes include infection (10%) and cardiac disease (10%) [3]. According to the law of LaPlace, the site of largest diameter in a cylinder requires the least pressure to distend. Because the cecum is the widest portion of the colon it is the area that requires the least pressure to distend; it is therefore most susceptible to the effects of distal obstruction. As the cecum becomes increasingly dilated, wall tension increases until transmural pressure exceeds perfusion pressure, thus leading to ischemia of the bowel. Because the mucosa of the colon is the most metabolically active, decreased perfusion affects this tissue layer first. Mucosal ischemia may progress to frank necrosis of the entire bowel wall with ensuing perforation, leading to mortality rates of up to 50% [4].

By history, patients with acute colonic pseudo-obstruction may report abdominal pain and distention accompanied by nausea and vomiting; obstipation is common. Physical examination demonstrates a distended tympanitic abdomen; the presence or absence of tenderness does not reliably indicate or exclude underlying colonic ischemia [3]. Diagnosis is confirmed by abdominal radiography that demonstrates proximal colonic distension, but not left sided distension.

Once other causes of colonic dilation have been excluded (including but not limited to mechanical obstruction and C. difficile-associated colitis) a decision regarding therapy must be made. Up to 96% of cases of colonic pseudo-obstruction will resolve with supportive therapy consisting of nasogastric tube decompression and cessation of narcotic medications [5]. Therapeutic options for those cases that do not resolve spontaneously include intravenous neostigmine, colonoscopic decompression, and surgical intervention and depend on the clinical status of the patient and the degree to which ischemia or perforation is suspected. Strong evidence indicates intravenous neostigmine is an effective modality for decompression of acute colonic pseudo-obstruction [6] and should be considered first-line therapy in patients with cecal diameter >12cm without signs of ischemia or

perforation who have failed supportive therapy. However, because the parasympathetic side-effects of neostigmine include bradycardia, patients should be placed on a cardiac monitor and with atropine at the bedside prior to administration [7].

Here we present a case of acute colonic pseudo-obstruction in which the cecal wall tension was sufficient to cause ischemia to the mucosal layer but the tension was relieved before progression to transmural ischemia occurred. This ischemic episode then caused a delayed lower gastrointestinal bleed. Although the vast majority of cases of acute colonic pseudo-obstruction may be successfully managed supportively, subclinical ischemia may be more common than is recognized. Even in patients in whom conservative management initially appears successful, sequelae of subclinical ischemia may occur and thus close continuing observation is mandated.

CORRESPONDENCE TO

Daniel N Holena, Division of Traumatology and Surgical Critical Care, 3400 Spruce Street, Philadelphia PA 19140.
email: Daniel.holena@uphs.upenn.edu Phone (215) 588-5144 Fax (215) 614 0375

References

1. Ogilvie WH. Large-intestine colic due to sympathetic deprivation, *Br Med J* 1948; 671–673.
2. Spira IA, Rodrigues R, and Wolff WI. Pseudo-obstruction of the colon, *Am J Gastroenterol* 1976; 65:397–408.
3. Vanek VW and Al-Salti M. Acute pseudo-obstruction of the colon (Ogilvie's syndrome). An analysis of 400 cases. *Dis Colon Rectum* 1986; 29:203–210.
4. Rex, DK. Colonoscopy and acute colonic pseudo-obstruction, *Gastrointest Endosc*
5. Sloyer AF, Panella VS, Demas BE et al. Ogilvie's syndrome. Successful management without colonoscopy, *Dig Dis Sci*; 1988; 33:1391–1396.
6. Ponc J, Saunders, MD, and Kimmey MB. Neostigmine for the treatment of acute colonic pseudo-obstruction, *N Engl J Med* 1999; 341:137–141.
7. Eisen GM, Baron TH, Dominitz JA et al. Acute colonic pseudo-obstruction. *Gastrointest Endosc* 2002; 56:789–792.
8. Saunders, MD. Acute colonic pseudo-obstruction. *Best Pract Res Clin Gastroenterol* 2007; 21:671-687.

Author Information

Daniel N. Holena, MD

Division of Traumatology and Surgical Critical Care, The Hospital of the University of Pennsylvania

Benjamin Braslow, MD

Division of Traumatology and Surgical Critical Care, The Hospital of the University of Pennsylvania