

Laryngocele: A Case Report and Review of Literature

J Gulia, S Yadav, A Khaowas, S Basur, A Agrawal

Citation

J Gulia, S Yadav, A Khaowas, S Basur, A Agrawal. *Laryngocele: A Case Report and Review of Literature*. The Internet Journal of Otorhinolaryngology. 2012 Volume 14 Number 1.

Abstract

Laryngocele is a rare, benign dilatation of the laryngeal saccule which may be asymptomatic or they may present with cough, hoarseness, stridor, sore throat and swelling of the neck. The incidence of laryngocele is 1 per 2.5 million people per year. The clinical presentation, investigations and the surgical management is reviewed.

INTRODUCTION

The laryngeal ventricle of Morgagni is normally a small elliptical recess located between the false cords above and true vocal cords below. The antero-superior aspect of this recess ends in a blind pouch, which is called the appendix of the ventricle of Morgagni or saccule. A laryngocele is an abnormal saccular dilatation of the appendix of the laryngeal ventricle of Morgagni. It forms an air sac lined with pseudo-stratified ciliated columnar epithelium, which maintains its communication with the ventricle by means of a narrow stalk¹.

Laryngocele are of three type's namely internal, external and combined or mixed laryngocele according to their relationships with the thyrohyoid membrane². When the ventricular appendage increases in size, it extends medial and superior to the thyroid cartilage till it reaches the thyrohyoid membrane. If this dilated sac doesnot pierce the thyrohyoid membrane it remains within the larynx and results in internal laryngocele. When this sac pierces the thyrohyoid membrane and protrudes through the thyrohyoid membrane in to the neck it becomes an external laryngocele. A laryngocele, both medial and lateral to the thyrohyoid membrane, is called combined or mixed laryngocele.^{3,4} Laryngocele is usually unilateral; however bilateral internal⁵ as well as bilateral external laryngocele⁶ has been reported.

A case of an external laryngocele is being presented.

CASE REPORT

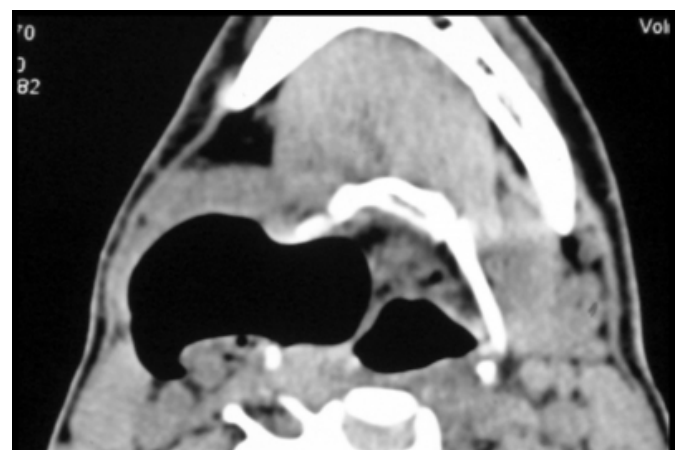
A 40 year old male patient presented with three year history of swelling right side of the neck which has slowly increased in size. There was no history of hoarseness, dysphagia, sore throat or chronic cough. The patient was a smoker and

laborer by profession. Past history was insignificant.

General physical examination of the patient was normal. Otorhinolaryngological examination revealed a non-tender soft and reducible swelling on right side in the upper one-third of neck which increased in size on Valsalva maneuver. Indirect laryngoscopic examination was normal. The patient was investigated and his haematological examination and X-ray chest were normal. X-ray soft tissues neck AP view and lateral view showed an air filled cavity on the right side of neck. Ultrasound of the neck also revealed similar findings. Computed tomography of the neck was done which showed air filled sac communicating with the larynx (Fig 1). A diagnosis of laryngocele was made.

Figure 1

Figure 1: Computed tomography neck showing a air filled sac communicating with the larynx

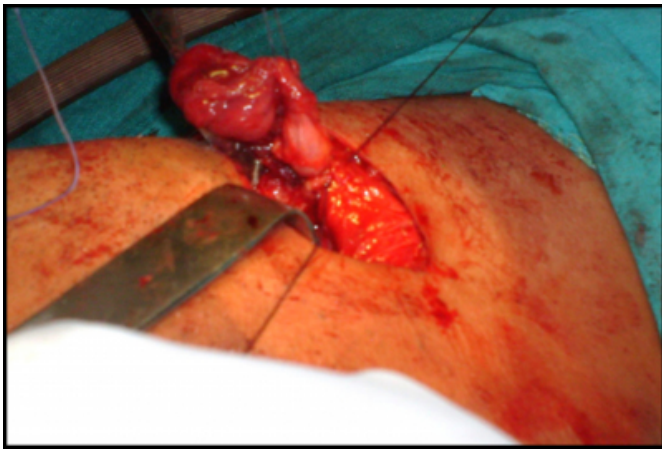


After anesthetic fitness the patient was taken up for surgery under general anesthesia. Laryngocele was resected through an external approach. A collar incision was given over the

upper border of thyroid cartilage extending laterally up to the anterior border of the sternocleidomastoid muscle. Skin flaps including the platysma were elevated up to the hyoid bone superiorly and down to the lower border of the thyroid cartilage. The strap muscles were retracted laterally. The fundus of the sac was defined and with blunt dissection, the laryngocele was dissected up to its opening in the thyrohyoid membrane and after ligation at its neck the sac was removed. (Fig 2)

Figure 2

Figure 2: showing the dissected and exposed laryngocele before its excision.



Thyrotomy and entry into the laryngeal lumen was avoided and the wound was closed in layers with a negative suction drain for 48 hours. Sutures were removed after 7 days and the patient was discharged in a stable condition. After follow up of 18 months the patient was symptom free.

DISCUSSION

Laryngoceles may be congenital or acquired and occur at any age. Laryngocele have been reported to be five to seven times more frequent in males, with a peak incidence in the sixth decade of life.^{1,7,8} The estimated incidence of laryngocele is 1 per 2.5 million people per year. Eighty-five percent of laryngocele have been found to be unilateral without any right or left side predominance.^{2,3}

The etiology of the laryngocele is unknown but certain predisposing factors are associated with their development. Congenitally, the laryngeal saccule may represent atavistic remnants corresponding to the lateral laryngeal air sacs of the higher anthropoid apes.⁹ Increased intralaryngeal pressure may be brought about by many activities (like lifting defecating), involving a strain which requires fixing the diaphragm in forced expiration against closed larynx

resulting in increased glottis and ventricular pressure. Increased intra-laryngeal pressure is also caused by activities requiring a modified valsalva maneuver in which intrathoracic pressure is increased during expiration and is fixed against the lips. This mechanism causes increased ventricular pressure in wind instrument players^{1,10,11}.

There is a well documented association of laryngocele with laryngeal carcinoma and the reported incidence varies from one to ten percent. Supra-glottic carcinoma is the most common laryngeal carcinoma reported to be associated with laryngocele. It may result in a valve like closure at the neck of the ventricular appendage, which allows the entrance of air but prevents its exit. Hence a carcinoma must be ruled out if a laryngocele is detected clinically or radiologically.¹²⁻¹⁴ An association of laryngocele with other laryngeal disease has been reported including papillomatosis in children¹⁵, amyloidosis¹⁶, rheumatoid arthritis¹⁷ and oncocystic cysts¹⁸.

Laryngoceles commonly present with dysphonia or a swelling in the neck which typically becomes more prominent during Valsalva maneuver. The other symptoms related to laryngoceles include cough, dyspnea, inspiratory stridor, dysphagia, and foreign body sensation in the throat^{1,2,11}.

Internal laryngocele presents with hoarseness of voice, dyspnea and sensation of foreign body. On indirect laryngoscopy a swelling/ fullness of false vocal cords and aryepiglottic fold region with normal overlying mucosa is seen. External laryngocele presents as a mass evident in the lateral aspect of the neck, which is round or ovoid, soft, elastic, moveable, painless and covered by a normal skin. It decreases in size by gentle palpation and pressure as the air escapes in the larynx. Mixed laryngocele produces the subjective symptoms of internal laryngocele and the objective signs of an external laryngocele. Almost pathognomonic of the mixed type of laryngocele is the rapid, sudden worsening of symptoms, especially dyspnea following compression of the external component. The passage of air from the external to the internal part of the sac results in sudden enlargement of internal component of laryngocele and it may cause acute upper airway obstruction^{1,2,6,10,11}.

Laryngoceles rarely may even result in death of the patients. An external laryngocele can produce pressure and displace the larynx causing obstruction and death¹⁹. An external laryngocele can cause sudden death by asphyxia from

spillage of muco-purulent material in to the trachea.²⁰

The diagnosis of laryngocele is essentially a clinical. Plain X-rays soft tissue necks in anterior- posterior and lateral views are of value, especially if the Valsalva maneuver is performed. Ultrasound examination of neck is also useful. Computed tomography provides a cross-sectional image and superior contrast resolution and has replaced many conventional techniques and has become the initial radiographic method of evaluating the larynx and neck. It is the also useful investigation in cases with suspicion of concomitant laryngeal pathology. Uncomplicated laryngocele appear on CT as air filled structures lying in the para-laryngeal space (internal), lateral neck (external) or in both locations (mixed).Magnetic resonance imaging, because of its multiplanner capability provides high definition of soft tissues, offers detailed information on the boundaries of the air-filled sac and, is useful when laryngomucocoele or laryngopyocoele are suspected. MRI is also helpful to distinguish obstructed mucus and inflammation from neoplastic disease.^{21,22,23}

Differential diagnosis of laryngocele includes, saccular cyst, branchial cyst, neck abscess and lympho-adenopathy.^{1,11,24}

Treatment of laryngocele is surgical. External surgery is preferred for large or external laryngocele, while endoscopic resection is favored for small, internal laryngocele. External approach provides an excellent exposure during the dissection of the plane between the neck of laryngocele and surrounding paraglottic tissue. Further this approach offers less recurrence rate, minimal morbidity, and negligible complications^{4,14,25}. Endoscopic resection with CO2 laser is the treatment of choice in patients with internal laryngocele. It requires lesser operation time and causes minimal damage to the endolarynx and vocal folds. The quality of voice and swallowing functions can be preserved.^{14,25}

The mixed laryngocele can be completely removed via an external cervical approach, however a combined external and endoscopic laser approach to ensure complete removal of the mixed laryngocele has been advocated.^{14,25, 26}

References

1. Holinger LD, Barnes DR, Smid LJ, Holinger PH. Laryngocele and saccular cysts. *Ann Otol Laryngol* 1978; 87(5 Pt 1):675-685.
2. Verret DJ, DeFatta RJ, Sinard R. Combined laryngocele. *Ann Otol Rhinol Laryngol* 2004;113:594-6.
3. Glanz I, Grunebaum M. The radiographic appearances of ventricular laryngocele. *Isr J Med Sci* 1971; 7: 1155-59.
4. Thome R, Thome DC, De La Cortina RAC. Lateral thyrotomy approach on the paraglottic space for laryngocele resection. *Laryngoscope* 2000; 110:447-50.
5. Meda P. Symptomatic laryngocele in cancer of larynx. *Arch Otolaryngol* 1952; 56: 512-20.
6. Bateman GH. Case of bilateral external laryngocele. *J Laryngol Otol* 1957; 71: 769-72.
7. Gallivan KH, Gallivan GJ. Bilateral mixed laryngoceles: simultaneous stroboscopy and external video examination. *J Voice* 2002; 16: 258-66.
8. Ingrams D, Hein D, Marks N. Laryngocele: an anatomical variant. *J Laryngol Otol* 1999;119:675-7.
9. Broyles EN. Anatomical observations concerning the laryngeal appendix. *Ann Otol Rhinol Laryngol* 1959;68 :461-70.
10. Stell PM, Maran AG: Laryngocoele. *J Laryngol Otol* 1975; 89:915-24.
11. Amin M, Maran AG: The aetiology of laryngocoele. *Clin Otolaryngol Allied Sci* 1988; 13:267-72.
12. Harney M, Patil N, WalshR, Brennan P, Walsh M. Laryngocele and squamous cell carcinoma of the larynx. *J Laryngol Otol* 2001; 115: 590-92.
13. Pietrantonil L, Felisati D, Finzi A. Laryngocele and laryngeal cancer. *Ann Otol Rhinol Laryngol* 1959; 68: 100-107.
14. Matino Soler E, Martinez Vecina V, Leon Vintro X, Quer Agusti M, Burgues Vila J, de Juan M. Laryngocele: clinical and therapeutic study of 60 cases. *Acta Otorrinolaringol Esp* 1995; 46: 279-86.
15. Altamer-Rios J, Morales Roza O. Laryngocele and pyolaryngocele. *An Otorrinolaringol Ibero Am* 1992; 19: 393-9.
16. Aydin O,Ustundag E, Iseri M, Ozkarakas H, Oguz A. Laryngeal amyloidosis with laryngocele. *J Laryngol Otol* 1999; 113: 361-3.
17. Erdogmus B, Yazici B, Ozturk O, Ataoglu S, Yazici S. Laryngocele in association with ankylosing spondylitis. *Wien Klin Wochenschr* 2005; 117: 718-20.
18. McDonald SE, Pinder DK, Sen C, Birchall MA. Oncocytic cyst presenting as laryngocele with surgical emphysema. *Eur Arch Otorhinolaryngol* 2006; 263:237-40.
19. Mays CA. A case of fatal asphyxia due to infection of a ventricular laryngocele. *Br J Surg* 1954; 41: 662-3.
20. Beautyman W, Chir B, Hatdak GL, Taylor M. Laryngopyocoele- Report of a Fatal Case. *N Engl J Med* 1959; 260:1025-27.
21. Parsons CA, Chapman P, Courter RT, Grundz A. The role of computed tomography in tumors of the larynx. *Clin Radiol* 1980; 31: 529-33.
22. Kumar G, Bradley PJ, Wastie ML. What a blow! *Br J Radiol* 1998; 71: 799-800.
23. Mitroi M, Capitanescu A, Popescu FC, Popescu C, Mogoanta CA, Mitroi G, Surlin C. Laryngocele associated with laryngeal carcinoma. *Rom J Morphol Embryol* 2011; 52 :183-4.
24. Griffin J, Ramadan HH, Wetmore SJ. Laryngocele: a cause of stridor and airway obstruction. *Otolaryngol Head Neck Surg* 1993;108:760-62.
25. Dursun G, Ozgursoy OB, Beton S, Batikhan H. Current diagnosis and treatment of laryngocele in adults. *Otolaryngol Head Neck Surg* 2007;136: 211-5.
26. Ettema SL, Carothers DG, Hofmann HT. Laryngocele resection by combined external and endoscopic laser approach. *Ann Otol Rhinol Laryngol* 2003;112:361- 4.

Author Information

Joginder Singh Gulia

Professor, Department of Otolaryngology, Pt. B.D Sharma University of Health Sciences

S P S Yadav

Senior Professor, Department of Otolaryngology, Pt. B.D Sharma University of Health Sciences

Ajoy Khaowas

Ex Resident, Department of Otolaryngology, Pt. B.D Sharma University of Health Sciences

Sukhdeep Kaur Basur

Postgraduate student, Department of Otolaryngology, Pt. B.D Sharma University of Health Sciences

Arpit Agrawal

Postgraduate student, Department of Otolaryngology, Pt. B.D Sharma University of Health Sciences