

Giant Pleomorphic Adenoma of the Parotid gland- A Case Report

O M.E, U A.N, U Akpan, K J, I Bassey

Citation

O M.E, U A.N, U Akpan, K J, I Bassey. *Giant Pleomorphic Adenoma of the Parotid gland- A Case Report*. The Internet Journal of Otorhinolaryngology. 2012 Volume 14 Number 1.

Abstract

Pleomorphic adenoma is the commonest salivary gland tumor. It occurs more frequently in the parotid gland where it accounts for 65% of tumors. Although a benign tumor, it can attain an enormous size if untreated. Risk factors to malignant transformation include long duration and history of a rapid growth phase. Most cases of giant Pleomorphic adenoma were seen before 1980's, but some cases have been published recently.

We present a case of giant Pleomorphic adenoma weighing 1.25kg within 2 years of onset in a 58 year old female.

Treatment was by superficial parotidectomy with facial nerve preservation. Histology revealed an entirely benign mass despite the history of a rapid growth phase in the last 6 months.

Preoperative assessment of exact extent of tumor was not possible because of the lack of radiological facilities for CT and MRI Scan.

INTRODUCTION

Pleomorphic adenoma is a benign salivary gland tumor. It is the commonest salivary gland tumor. The aetiology is unknown but it has been suggested that prolonged exposure to radiation and the simian virus (SV40) may play a role in the development.^{1,2}

It is more frequent in the parotid gland where it accounts for 65% of tumors. There is a female sex preponderance and a peak age range of 5th to 6th decade for all Pleomorphic adenomas.^{1,3,4} Pleomorphic adenoma usually presents clinically as a painless, slow-growing mass, varying from 2-6 cm when resected.³ Although a benign tumor it can attain an enormous size if untreated.

Cases of giant Pleomorphic adenoma usually present as an irregular multinodular mass weighing 1 to 27 Kg.⁵ Literature review shows most cases involve the parotid gland with an age range of 20 to 40 years old.⁵ A mean tumor weight of 7.81 Kg and mean age of 56.2 was reported in a review of the ten largest Pleomorphic tumors before the 1980's in English literature.⁶ There is no statistical documentation of geographic or racial predilection. Risk factors to malignant transformation show some association with long duration, multiple recurrences, deep lobe tumors, male gender, and older age. Facial nerve involvement, pain, trismus and a rapid enlargement of a tumor nodule should raise concern

about the development of malignant change. Malignant change has been reported to occur in 2-7% of cases.⁷

However, many reports have shown long duration of tumor without malignant transformation.³

Diagnosis is usually by a combination of clinical history, Fine needle aspiration biopsy for cytology and histological confirmation of excised tumor.

Computerized Tomography (CT) scan, Magnetic Resonance Imaging (MRI) and Ultrasonography Scan may be necessary to assess extent of gland involvement.

Treatment is usually by superficial parotidectomy with facial nerve preservation although some authors have treated by total parotidectomy with facial nerve preservation.²

CASE REPORT

A 58-year-old woman presented to the outpatient Otorhinolaryngology (ORL) clinic of the University of Calabar Teaching Hospital, Calabar- Nigeria, with a 2 year history of a progressive swelling in the right parotid region. There was a history of rapid growth in the last 6 months. Clinical examination revealed a giant, irregularly shaped, mobile, non tender, firm multinodular mass with a bosselated surface. The mass measured approximately 22cm by 20cm. There were no signs of facial nerve involvement.

Giant Pleomorphic Adenoma of the Parotid gland- A Case Report

(Figures 1&2). Complete blood count, HIV screening, blood urea, electrolyte and creatinine, electrocardiogram and chest x-ray were all normal. CT and MRI scan was not done because of lack of facilities in our center.

The tumor was completely excised under general anesthesia via endotracheal intubation. (Figure 3). The patient was placed in the anti trendelenberg position with head turned to the left side. (Figure 2). The mass was resected by superficial parotidectomy with preservation of the facial nerve. The mass was well encapsulated hence was dissected from the surrounding tissue. The facial nerve branches were identified as they exit the mass at the anterior border of the masseter muscle. The mass was dissected free of the facial nerve branches beginning from terminal branches anteriorly to the main branches posteriorly. Hemostasis was by very cautious use of bipolar diathermy and catgut ligatures. Corrugated drain was kept inside and the skin incision closed in 2 layers. Pressure bandage was applied. The specimen measured 22cm by 20cm and weighed 1.25 Kg. (Figure 4) This was sent for histopathological examination. Immediate post operatively, the facial nerve was intact. (Figure 5) The patient was discharge after One week. The patient is being followed up and there was no recurrence after 9 months.

Histology Report showed tissue composed of proliferating ductal elements lined by benign epithelium in myxoid and fibrocollagenous stroma with foci of hemorrhage. No evidence of malignancy was seen in the sections. (Figure 6)

Figure 1

Figure 1-Giant PLA before resection

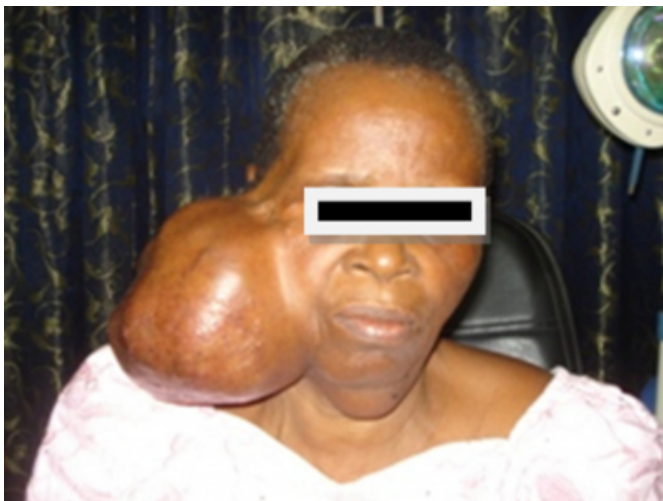

Figure 2

Figure 2- Side view

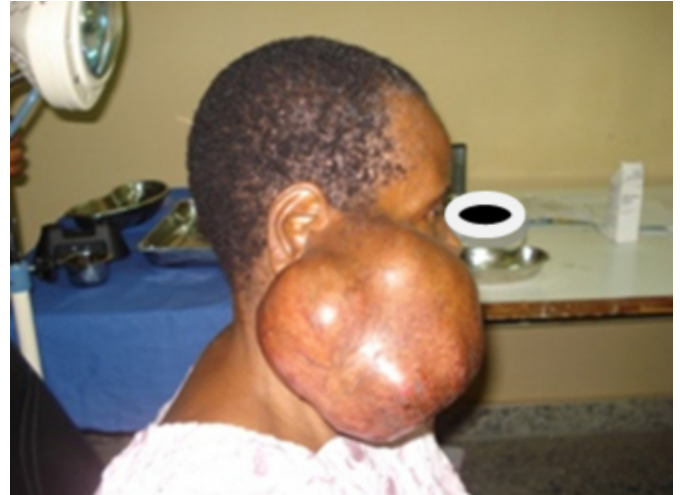

Figure 3

Figure 3- Patient under GA, ET Intubation

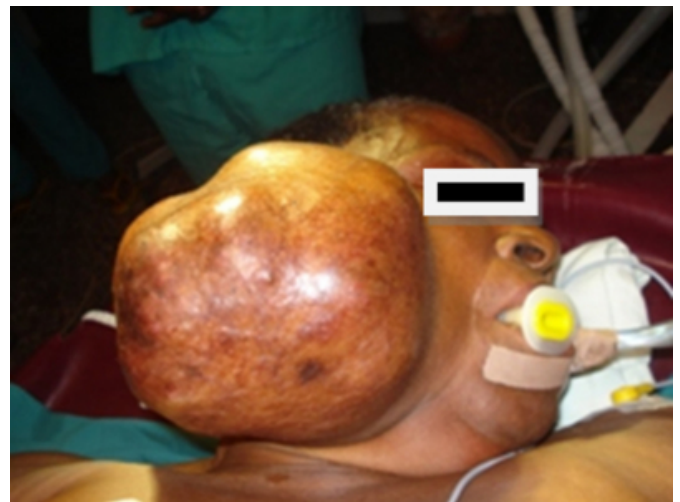

Figure 4

Figure 4- Excised tumor lobulated and well encapsulated.

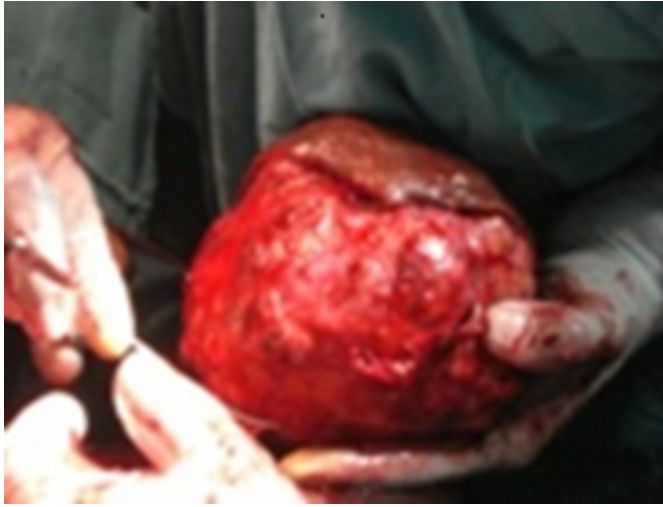

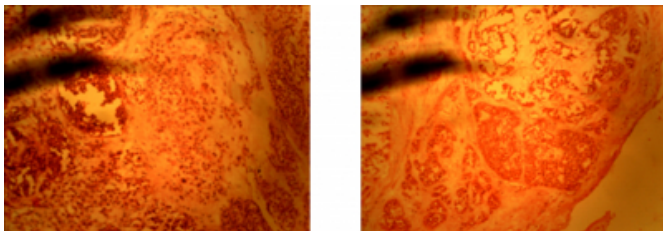
Figure 5

Figure 5-Facial nerve intact after resection

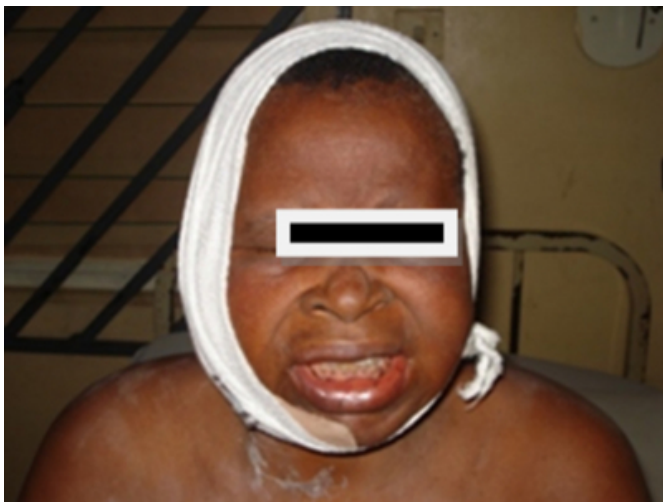

Figure 6

Figure-6: Photomicrograph showing proliferating ductal elements lined by benign epithelium in myxoid and fibrocollagenous stroma with foci of hemorrhage.



DISCUSSION

Pleomorphic adenoma is the most common salivary gland tumor and the parotid gland is mostly involved. Our case

was a female 58 years of age with a giant Pleomorphic parotid tumor weighing 1.25kg. This agrees with literature review of giant Pleomorphic adenoma which shows a female predominance and weight of the tumor between 1-27kg.⁵ Patients of any age may be affected, but more frequently between fifth and sixth decade. A mean age of 56.2 year has been reported⁵.

The period of evolution of growth into a giant tumor in our patient was rather short in contrast to most literature reports.¹

Although, treatment was surgical by superficial parotidectomy with preservation of the facial nerve but this was a management challenge. There was a rapid growth phase of mass in the last 6 month in our patient. This is a known risk factor for malignancy in parotid adenoma. However, our patient could not have the benefit of a preoperative CT or MRI scan assessment of exact extent of the tumor because these facilities are lacking in our center.

Histology of excised tumor was completely benign as extensive histological evaluation ruled out any malignant transformation. However, the patient will be closely followed up in case of recurrences.

CONCLUSION

Giant Pleomorphic adenoma is still common and may have a short period of evolution. The lack of adequate radiological facilities is a management challenge of giant Pleomorphic adenoma in the third world. Also a rapid growth phase does not necessarily mean malignant transformation. However, an extensive histopathological assessment of excised tumor is mandatory to rule out malignant transformation.

References

1. Ellis GL, Auclair PL. Pleomorphic adenoma. In: Ellis GL, Auclair PL. Tumors of the Salivary Glands (Atlas of Tumor Pathology). Facicle 17. Washington, DC: Armed Forces Institute of Pathology; 1996:39-57
2. Martinelli M, Martini F, Rinaldi E, et al. Simian virus 40 sequences and expression of the viral large T antigen oncoprotein in human pleomorphic adenomas of parotid glands. Am J Pathol. Oct 2002; 161(4):1127-33.
3. Takahama AJ, Perex DE, Magrin. Case report giant Pleomorphic adenoma of the parotid gland. Med oral Pathol Oral cir Bucal 2008 Jan 1:13 (1) E58-60.
4. Eveson JW, Cawson RA Salivary gland tumor. A review of 2140 cases with particular reference to histological types, site, age and sex distribution J. Pathol 1985; 146: 51-8.
5. Schultz coulon HJ. Pleomorphic giant adenomas of the parotid gland Laryngorhinologic 1989 Aug. 68 (8): 445-9.
6. Bunting S E, Smith TL, Holmes DK, giant Pleomorphic adenoma of the parotid gland: case report and review of the literature. Ear nose throat J. 1998 aug. 77 (8): 634, 637-8 640.
7. M Sherif Said, Pleomorphic Adenoma. eMedicine

Specialties > Pathology > Head Updated: Jul 14, 2009

Author Information

Offiong M.E

Department of Otorhinolaryngology, University of Calabar Teaching Hospital

Umana A.N

Department of Otorhinolaryngology, University of Calabar Teaching Hospital

Umoh Akpan

Department of Otorhinolaryngology, University of Calabar Teaching Hospital

Kuni J

Department of Otorhinolaryngology, University of Calabar Teaching Hospital

Ima-Abasi Bassey

Department of Pathology, University of Calabar Teaching Hospital