

A Rare Case Of Dysgerminoma In A 58-Year Old Postmenopausal Woman In Makurdi, North Central Nigeria.

H SK, M TP

Citation

H SK, M TP. *A Rare Case Of Dysgerminoma In A 58-Year Old Postmenopausal Woman In Makurdi, North Central Nigeria.* The Internet Journal of Oncology. 2012 Volume 8 Number 2.

Abstract

The cause of ovarian cancers is not known but the most common risk factor is a positive family history of ovarian or breast cancer. Primary tumors of the ovaries may arise from the epithelium (82%), sex cord and germ cell (20%) areas. About 3-5% of all germ cell tumors (GCTs) are malignant with the most common being the dysgerminoma which also accounts for 4-5% of all ovarian cancers. Dysgerminomas are most commonly seen in women of reproductive age who are sexually active and they make up to 60% of all malignant ovarian tumors in women younger than 20 years.

We present a rare case of ovarian dysgerminoma in a 58-year old post menopausal woman who, presented to the gynecological unit of a secondary health care center in Makurdi, Nigeria. She had staging laparotomy and cytoreductive surgery. Initial chemotherapy with bleomycin, etoposide and cisplatin showed a good response. The appearance of this cancer in this age group should be a reminder to practitioners of the need to develop effective screening methods for ovarian cancers and the sensitization of patients to present early while attempts are made to open up well equipped cancer treatment centers, with adequately trained personnel. This is important since, ovarian cancers are the second most common gynecological malignancies and have the highest case fatality world wide; but once diagnosed dysgerminomas respond well to treatment.

INTRODUCTION

The ovaries in their normal state produce the female eggs as well as the sex hormones, estrogen and progesterone.

Ovarian tumor results from an uncontrollable or abnormal growth of the normal ovarian cells. The three (3) major types of ovarian tumors are epithelial, sex cord, and germ cell.

Epithelial cell tumors represent the majority of all ovarian neoplasms (82%). Conversely, germ cell tumors (GCT) are rare, comprising approximately 20% of all ovarian tumors, both benign and malignant. About 3-5% of ovarian GCTs are malignant; with the most common being the dysgerminoma which accounts for 1-5% of all ovarian cancers¹. Dysgerminomas affect women of reproductive age and sexually active group and make up to 60% of all malignant ovarian neoplasms in women younger than 20 years^{1,2}. About 5% of dysgerminomas occur in dysgenetic gonads. The most common risk factor for ovarian cancer is a positive family history of ovarian or breast cancer.

Ovarian cancer is the second most frequent gynecological malignancy and has the highest case fatality rate among gynecological cancers worldwide because of lack of effective screening methods and late presentation^{3,4}. In one study in Ibadan, Nigeria, eighty-one percent of the patients

presented in stage III and IV³.

We present a rare case of dysgerminoma in a 58 year old grand multi-parous woman who was 8 years post menopausal as a reminder to practitioners of the occasional appearance of this cancer in this age group. This is important because once diagnosed, dysgerminomas respond well to treatment.

CASE REPORT

A 58 year old married grand multiparous, 8 years postmenopausal woman reported to the out-patient department of General Hospital North Bank, Makurdi and was subsequently referred to the Gynecological Department with complaints of a lower abdominal mass associated with mild pain and progressive distention of 6 months duration. Her last child birth was 22 years before presentation. She also had progressive swelling of the lower limbs. She had initial dysuria which subsided after a course of antibiotics but there was no history of vagina discharge or bleeding. She had been gradually losing weight in the previous 2 months and although her appetite remained good she had easy satiety due to abdominal distention. There was no cough or difficulty in breathing. She was treated for these complaints in

A Rare Case Of Dysgerminoma In A 58-Year Old Postmenopausal Woman In Makurdi, North Central Nigeria.

two different private hospitals with peritoneal taps that yielded clear fluid and also had two units of blood transfusion. There was no history of contraception, diabetes mellitus, hypertension or a family history of ovarian or breast cancer.

On examination, she was found to be an ill looking, elderly woman with pallor, wasting and pitting pedal and sacral. Her pulse rate was 82 beats per minute and regular, while the blood pressure was 100/80 mmHg. There was no cardiomegaly and heart sounds were normal. The chest was clinically clear. The abdomen was grossly distended with ascites (figure: 1) and there was a firm to hard irregular suprapubic mass arising from the pelvis and extending to the level of the umbilicus. The overlying skin was normal. The liver span was about 4cm, below the epigastrium and was soft with a smooth surface. The kidneys could not be ballotable due to ascites. Pelvic examination revealed an atrophic vulvo-vagina with a 2 cystocoele. The cervix was healthy and centrally located. On rectovaginal examination, the mass was found to be filling the pelvis to a size similar to that of a 20-weeks pregnancy. It was firm to hard in consistency, irregular, fixed and moderately tender. There was healthy with no evidence discharged. A diagnosis of ovarian cancer with 2^o cystocoele was made and she was admitted and prepared for staging laparotomy to which she consented after adequate counseling. Abdominal ultrasound showed a large (20.40cm x 10.80cm), irregular pelvic mass of mixed echogenicity. The uterus and ovaries were not separately visualized. The bladder and kidneys were normal. The liver and spleen were enlarged and there was marked ascites.

The result of blood investigations showed red blood cell count of $5.24 \times 10^{12}/L$ (normal range $4.5-5.0 \times 10^{12}/L$), hemoglobin 11.30g/dl (normal range 13-18g/dl), platelets $409 \times 10^3/\text{up}$, white cell count of $9.2 \times 10^3/\text{ul}$ (lymphocytes 19%, neutrophils 68%, eosinophils 10% and monocytes 3% with hypersegmentation of neutrophils), Na^+ 138 mmol/L (normal range 135-145mmols/L), K^+ 5.0mmol/L (3.5-5.1mmols/L), normal bicarbonate and chloride; urea 21mg/dl and uric acid 6.0mg/mg/dl (2.6-6.0mg/dl). The liver function tests were all within normal limits. Her urinalysis was normal. A routine pregnancy test was negative. Intravenous pyelography showed hydroureters and a filling defect of the bladder. Cancer antigen (Ca)-125 could not be done. Initial analysis of the ascetic fluid tap showed an acellular smear. The gross specimen after laparotomy

revealed a grayish-white soft tissue with multiple nodules measuring 15x13x7cm and weighing 1000grams. Histological sections revealed a loose fibrous stroma within which were seen sheets and cords of large vesicular cells with abundant clear cytoplasm, well defined boundaries and centrally placed nuclei. These were seen invading the stroma in broad fronts separated by scant fibrous tissue infiltrated by chronic inflammatory cells, confirming the diagnosis of dysgerminoma in this woman.

At surgery, a midline subumbilical incision was made with extension to the epigastrium to enhance exposure. The intra-operative findings were a huge, irregular, firm to hard abdomino-pelvic mass (figure: 2) with soft (non-cystic) areas, measuring about 16-18 weeks pregnancy size. It was fixed to the intestines, bladder, rectum and adjoining structures in the pelvis. Tumor deposits were seen on the omentum, intestines and the parietal peritoneum. The liver and spleen did not have any deposits on their surfaces. Clear ascetic fluid approximately 8L was drained from the abdomen. The para-aortic and retroperitoneal lymph nodes were not accessible for assessment and biopsy. She had infra-colic omentectomy with careful resection of some areas of the tumor including the peritoneal deposits. Radical surgical resection of both tumor and gut including the nodes was not done. The estimated blood loss was about 1000mls. A left paramedian drain was placed into the abdominal cavity and connected to a urine bag for closed drainage. She had 2 units of whole blood.

Her post operative period was uneventful. Her packed cell volume on the 2nd day after the operation was 27% and she was placed on double dose haematinics. The drain stopped functioning on the fourth day and was removed. The abdominal wound sutures were removed on the 10th post-operative day and wound healing was satisfactory. She was counseled jointly with her husband and children on the nature of the surgery and the need for further chemotherapy and possible radiotherapy. She opted to remain in hospital due to the remote location of her residence while, the relatives sought for funds for her chemotherapy since, radiotherapy was not an option for her due to the cost and its nonavailability in the centre and immediate locality. Her progress was satisfactory and she was well mobilized 4 weeks after surgery with minimal ascites and pitting edema of the legs. The first course of chemotherapy was started 4 weeks after surgery with bleomycin, etoposide, cisplatin (BEP) and dexamethasone after her haematocrit was built to

34%. It was well tolerated although she later developed ulcers in the mouth and vulva and mild diarrhea which were treated symptomatically. She however succumbed after the second course of chemotherapy from refractory hypovolemic shock.

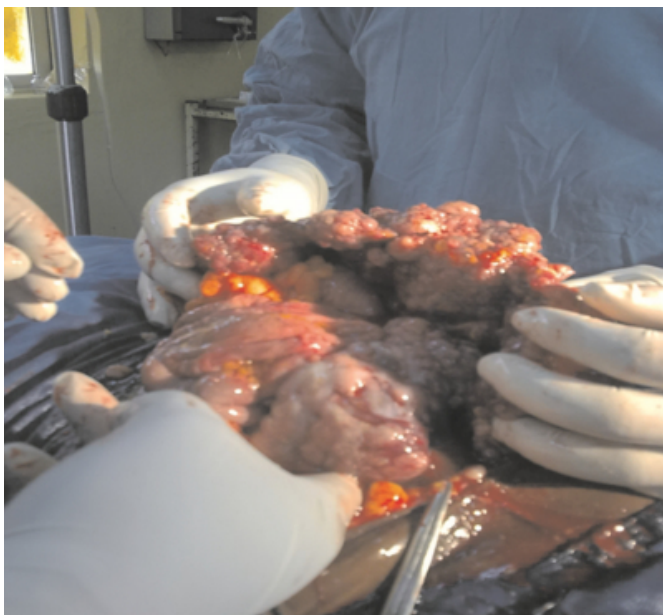Figure 1

Figure 1: Patient before surgery




Figure 2

Figure 2: Ovarian cancer mass at surgery



DISCUSSION

A dysgerminoma is a malignant tumor of the ovary that is composed of primitive, undifferentiated germ cells. Of the

germ cell ovarian tumors, 97% are benign (i.e. mature teratomas) and the remaining 3% are malignant. Primitive unipotent germ cells are the precursors to ovarian dysgerminomas and their testicular analog, the seminoma, while pluripotential germ cells divulge along different lines of differentiation such as choriocarcinoma, yolk sac, polyembryona tumors, teratomas⁵.

Common signs and symptoms are universal for any adnexal / ovarian mass and nonspecific for dysgerminoma and include abdominal pain, a palpable abdomino-pelvic mass, vaginal bleeding and occasionally ascites. There may also be early satiety, urinary frequency and dysuria. These tumors are usually unilateral and can occur during pregnancy. Rapid growth may predispose to rupture and torsion with associated signs of acute abdomen. Because dysgerminomas affect women of reproductive and sexually active age, they should be screened for sexually transmitted diseases. Regardless of the clinical environment, urine pregnancy test should also be done.

The standard workup for suspected GCTs requires lactic dehydrogenase (LDH), alpha fetoprotein (AFP), and beta human chorionic gonadotrophin (bHCG) both for diagnosis and follow-up of patients, although dygerminomas are an exception. The absence of elevated AFP or bHCG does not exclude the diagnosis of dysgerminoma as they rarely express hormones. Useful tumor markers for follow-up and tracking of adjuvant therapy include bHCG, AFP, LDH and carcino-embryonic antigen125 (CA-125). Elevated levels of neuron-specific enolase, calcium, inhibin, placental alkaline phosphotase (PLAP) and prolactin¹ have been reported.

Dysgerminomas are solid in nature, pale and measure more than 10cm (20cm in this case) and the microscopic appearance as presented here was characteristic. The initial approach should be an attempt to determine the nature and extent of the pelvic mass. Transvaginal ultrasound is used to find out if the mass is ovarian. More importantly, the presence of thickened septations, solid and cystic components including the presence of free fluid and bilaterality increases the suspicion of malignancy. Other imaging techniques include CT, MRI and chest radiographs. Additional work-ups include barium enema, upper GI series, Colonoscopy and intravenous pyelography (IVP).

Dysgerminomas like all other ovarian cancers are staged surgically. Women who have completed childbearing should undergo exploratory laparotomy, pelvic washings, total

abdominal hysterectomy, bilateral salpingo-oophorectomy, ipsilateral pelvic and bilateral para-aortic lymph node sampling, omentectomy and peritoneal biopsies^{1,6}. The role of adjuvant chemotherapy should be reserved for resectable yet advanced tumours¹.

Exploratory laparotomy is required for histological confirmation, staging and tumor debulking and should be performed by a surgeon trained in this aspect of ovarian cancer management⁷. Patients with early-stage disease, limited to the ovary or pelvis (Stage I and II, respectively) have a survival rate of 80-95%, whereas those with advanced disease (upper abdomen and beyond i.e. stages III and IV, respectively) is 10-30%. Those with higher-risk early diseases (pelvic extension, capsular rupture or involvement, positive washings, ascites or high-grade lesions) and for patients with advanced-stage disease (stage III and IV), postoperative combination chemotherapy with a taxane and platinum combination is the standard of care⁷.

Primary surgery for ovarian cancer can be categorized into simple and radical surgical procedures performed as part of cytoreductive surgery. Simple cytoreduction include TAHBSO, infracolic omentectomy, limited excision of retroperitoneal lymph nodes, and segmental resection of the small intestine. Radical procedures on the other hand, are associated with increase in blood loss, operative time, hospital stay, and risk of complications. These risks can be mitigated by careful pre-operative evaluation and preparation, meticulous surgical technique, sound clinical judgment, and a watchful eye in the postoperative period. Example of radical cytoreductive procedure includes oophorectomy, resection of the recto-sigmoid colon, splenectomy, diaphragm peritonectomy or resection, and extensive nodal debulking⁶.

Radiotherapy can be administered to patients with stage Ib-III tumors, although it has been mostly abandoned due to the high success rates of chemotherapy, and the long-term complications including sterility and early menopause in younger women¹. Primary radiotherapy is reserved for patients who can not tolerate chemotherapy or surgical resection. Palliative care for advanced cases should be aimed at improving quality of life and pain reduction.

The ovarian cancer patients in the developing world are younger and of higher parity³, the projected increase in the

incidence of ovarian neoplasms in this region may be due to the decreasing fertility and increasing use of ovulation induction drugs³. Despite multimodal treatment, mortality due to ovarian cancer is unsatisfactorily high^{1,3,4}. It has been shown that the removal of all tumor is the most important prognostic factor and that a high percentage of optimal debulking surgery is strongly dependent on the surgical expertise⁸, experience and philosophical approach of the surgeon to advanced ovarian cancer^{6,8}. In conclusion, primary cytoreductive surgery with or without adjuvant chemotherapy including radiotherapy is essential in the successful management of patients with ovarian cancer especially dysgerminoma which has a high cure rate if detected early. It is also worthy of note that the training of doctors with the necessary skills and experience should be stepped up especially in the developing countries. There should be a deliberate programme by hospitals for the establishment of cancer centers manned with the infrastructure and personnel including other resources needed to maintain such a programme. A multidisciplinary approach to ensure that patients get the best care before, during and after treatment is essential. Lastly, a deliberate cancer awareness programme should be incorporated in the primary health care scheme for routine health checks, for early presentation and treatment of ovarian cancer cases.

References

1. Michener CM, Wu AY. Ovarian Dysgerminoma. <http://emedicine.medscape.com/article/253701-print>. 12/15/2010
2. Gershenson DM, Morris M, Cangir A, Kavanash JJ, Stringer CA, Edwards CL. Treatment of Malignant germ cell tumors of the ovary with bleomycin, etoposide, and cisplatin. *J Clin Oncol* Apr 1990; 8 (4): 715-20 (medline).
3. Odukogbe AA, Adebamouno CA, Ola B, Olayemi O, OladoKun A, Adewole IF et al. Ovarian cancer in Ibadan: Characteristics and management. *J Obstet Gynaecol*. 2004 Apr; 24 (3):294-7
4. Gharoro EP, Eirewele O Cancer of the Ovary at the University of Benin Teaching Hospital: a 10-year review 1992-2001 *Afr J Med Med Sci* 2006 Jun; 35 (2): 143-7
5. Hazard GKF. Dysgerminoma Ovary. *Emedecine specialties* <http://emedicine.medscape.com/article/1610927-overview#a w2aab6b3> Updated: Aug 24, 2010
6. Bristow RE, Primary Cytoreductive Surgery for Advanced stage ovarian cancer: Indications for Radical Resection. *Bristow, Cancerologia* 2, Suplemento 1:2007: 31-36.
7. BerKen blit A, Cannistra SA. Advances in the management of epithelial ovarian cancer. *J Reprod Med*. 2005 Jun; 50 (6): 426-38.
8. Vergote I, Coens C, Casado A. Neoadjuvant chemotherapy or primary surgery in Advanced Ovarian cancer. *N Engl J Med*. 2010; 363:2370-2372

Author Information

Hembah-Hilekaan SK

Department of Obstetrics and Gynecology, College of Health sciences, Benue State University

Mbaave TP

Department of Medicine, College of Health sciences, Benue State University