

# Appendico-Vaginal Fistula – A Rare Complication Of Appendicitis

P Chatra, V U S

## Citation

P Chatra, V U S. *Appendico-Vaginal Fistula – A Rare Complication Of Appendicitis*. The Internet Journal of Radiology. 2012 Volume 14 Number 1.

## Abstract

Appendicitis is one of the most common conditions encountered in emergency surgical practice. Fistulous communication of appendix into adjacent organs is rare. Appendico- vaginal fistula is extremely rare.

## INTRODUCTION

Appendicitis is one of the most common differentials for a pain in the right iliac fossa. These patients usually seek emergency surgical attention and surgical intervention is curative in most of the cases. Albeit some patients do go in for complications mostly due to patient's delay in seeking medical help and delay in making the appropriate diagnosis. In this study we describe an extremely rare complication of appendicitis.

## CASE REPORT

A 67 year old lady presented with burning micturition since one month. She was a known diabetic for the past 15 years and was on oral hypoglycemic agents with fairly controlled blood glucose. She had undergone abdominal hysterectomy for fibroid uterus 8 years ago.

On clinical examination the patient was febrile and tenderness was elicited at right iliac fossa and suprapubic region. Per speculum examination showed presence of fecal matter in the right vaginal vault.

Laboratory examination revealed elevated total leukocyte count of  $18,000 \text{ mm}^3$  (normal: 4,000-11,000) with predominant neutrophilia. The random blood sugar was 184 mg/dl. ESR was 11mm/ hour (normal: 4-10). Urine examination showed plenty of pus cells per HPF (normal: 1-3 per HPF).

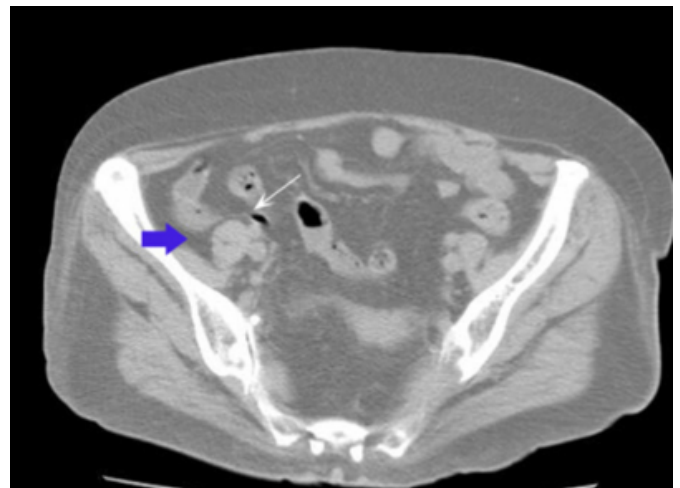
Clinical diagnosis of entero-vaginal fistula was made & the patient was subjected to CT scan of abdomen to localize the site of enteric fistula.

C.T Scan of the abdomen was performed with oral, rectal

and IV contrast media. Plain CT scan (figure-1) showed an inflamed appendix. Few air pockets were seen in the fistulous tract (figure 2). The appendix was inflamed and showed peri appendiceal inflammation.

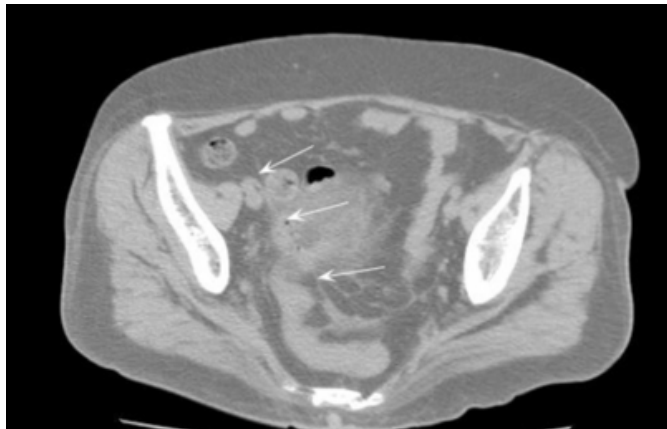
## Figure 1

Figure 1: CT axial non contrast image showing air pocket (arrow) in the tract extending from the appendix (arrowhead) into the pelvis.



**Figure 2**

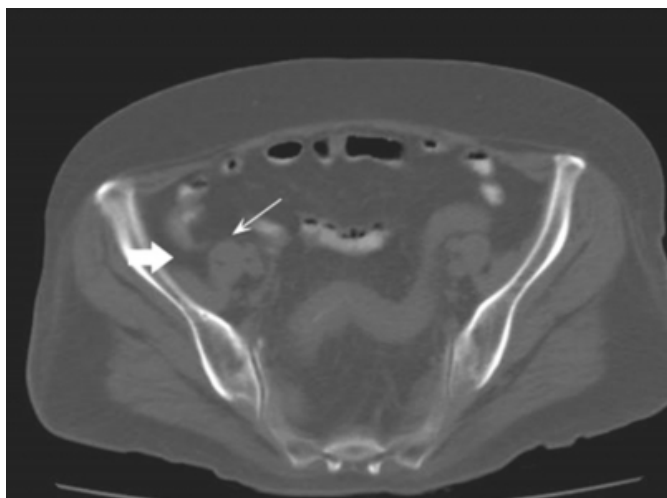
Figure 2: CT axial non contrast image demonstrating air pockets (arrows) in the fistulous tract.



On oral and rectal contrast study, the small and large bowel loops were unremarkable except for the appendix. A fistulous communication was demonstrated between the inflamed appendix and the vaginal vault (figure 3-6).

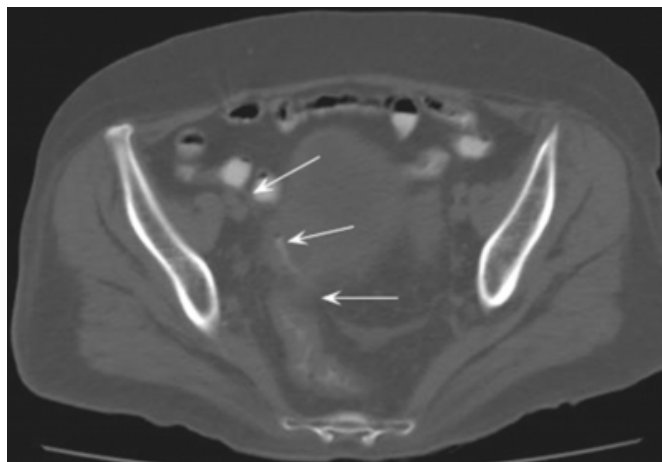
**Figure 3**

Figure 3: CT axial image with oral and rectal contrast showing inflamed appendix (arrowhead) filled with contrast.



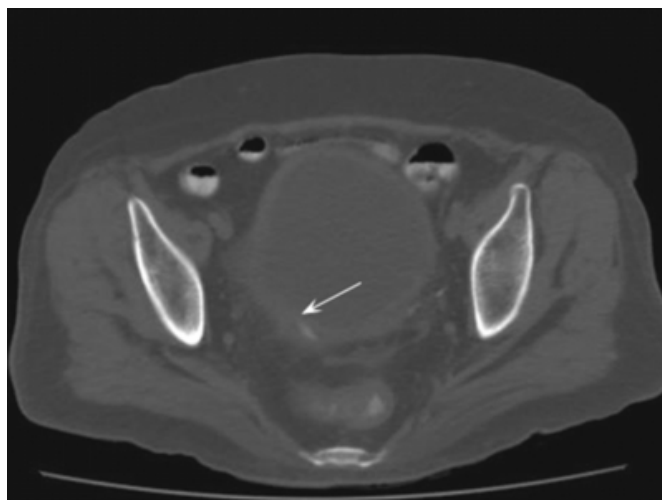
**Figure 4**

Figure 4: CT axial image with oral and rectal contrast showing extension of the rectal contrast (arrows) into the fistulous tract.



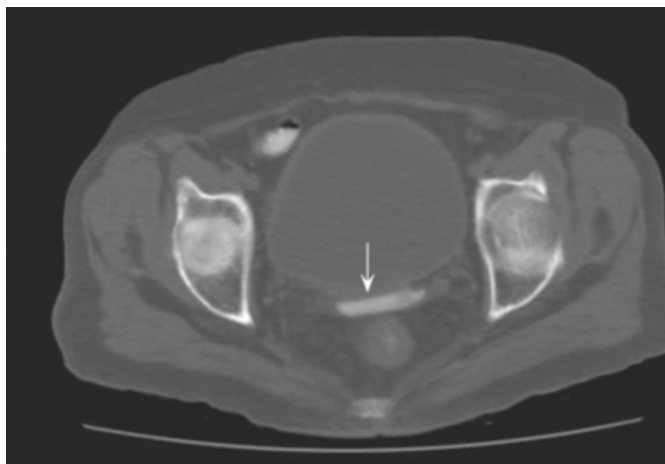
**Figure 5**

Figure 5: CT axial image with oral and rectal contrast showing extension of contrast (arrow) into the tract in the pelvis



### Figure 6

Figure 6: CT axial image with oral and rectal contrast showing extension of contrast (arrow) into the tract in the vaginal vault



The patient was then taken up for surgery with the diagnosis of appendicitis complicating into appendico-vaginal fistula. Per operatively surgeon found an inflamed appendix which was 10cm long with a ruptured tip. This inflamed appendix was excised and stump was buried in the cecum. Then the surgeon focused on the fistulous tract and inflamed tissue around the vaginal vault was debrided and vaginal vault repair was done. Post operative period was uneventful; the patient recovered and was discharged one week post surgery.

### DISCUSSION

Appendicitis is the most common cause of acute abdomen in surgical practice<sup>(1)</sup>. Clinically patient presents with pain and tenderness in the right iliac fossa. USG is the imaging modality of choice and appendicitis is seen as dilated, noncompressible, aperistaltic, blind ending loop in the right iliac fossa<sup>(2)</sup>. Common complications of appendicitis are appendicular abscess, rupture and peritonitis<sup>(3)</sup>. Uncommon complications include ascending septic thrombophlebitis, and septic emboli. Rare complication includes fistula formations<sup>(4)</sup>. There are a handful of rare appendicular fistulas reported in literature. These include appendico-cutaneous fistula<sup>(5)</sup>, appendico-renal sinus fistula<sup>(6)</sup>, gastrojejunoappendicular fistula<sup>(7)</sup>, appendico-vesical fistula<sup>(8)</sup> and appendicoumbelical fistula<sup>(9)</sup>. On the other hand vaginal fistulas are comparatively common. The most common of them is vesico-vaginal fistula (VVF)<sup>(10)</sup>.

Pathogenesis of appendico-vaginal fistula could be understood by knowing the pathogenesis of pelvic abscess. An inflamed appendix ruptures at its tip and the inflammatory contents are then emptied into pelvis forming

pelvic abscess<sup>(2)</sup>. Appendicular fistulas are as a result of direct rupture of the inflamed appendix into adjacent organs. The persistence of the fistulous tract is facilitated by epithelization of the tract<sup>(11)</sup>. Appendico-vaginal fistula results when the inflamed appendix directly ruptures into vagina forming a fistula<sup>(12)</sup>. The development of fistula in our patient was likely to be facilitated by previous hysterectomy which allowed close proximity to appendix.

Clinical diagnosis is often difficult as patient will be on antibiotics and all clinical signs are masked<sup>(8)</sup>. Most of them present with foul smelling vaginal discharge and are treated as urinary tract infection in the view of pus cells found on urine examination<sup>(12)</sup>. Imaging studies available to us in these patients include colonoscopy, barium enema, ultrasound and CT scan. Accuracy of colonoscopy in detecting colonic fistulas vary from 50-79%<sup>(13,14)</sup>. The sensitivity of barium enema in detection of appendicular fistulas is less than 50%<sup>(15)</sup>. Ultrasound of abdomen is a very helpful investigation in these patients to look for appendicitis. The accuracy of USG in detecting appendicitis under a well trained radiologist is 74-100%<sup>(16,17,1)</sup>.

Fistulogram through the vagina by endoscopic method is a simple and useful adjunct to the available methods of imaging enterovaginal fistulas<sup>(18)</sup>. CT scan of abdomen is the investigation of choice to look for enteric fistulas<sup>(8)</sup>. Further CT scan with oral contrast can delineate the fistulous tract, intravenous contrast shows enhancement of the tract which helps the surgeon in pre operative planning. Presence of oral contrast in the vaginal vault is confirmatory of fistula. Effort should also be made to look for predisposing factors for fistula formation such as radiation<sup>(19)</sup>, Crohn's disease<sup>(20)</sup>, appendicular diverticulitis<sup>(15)</sup>, cystadenocarcinoma of the appendix<sup>(21)</sup>, carcinoid tumors, neuroma<sup>(22)</sup> and cystic fibrosis<sup>(23)</sup>.

### CONCLUSION

In summary, appendico-vaginal fistula is one such complication of appendicitis which should be kept in mind in all cases of suspected entero-vaginal fistulas. Clinical diagnosis is often difficult as patient would have received prior antibiotics. CT scan is the imaging modality of choice. Demonstration of air pocket in continuation from the inflamed appendix to vaginal vault on plain study; and presence of oral contrast in the vaginal vault on contrast study confirms the diagnosis. Surgery is treatment of choice, appendectomy followed by vaginal vault repair is the surgical procedure of choice.

**References**

1. HS Fung, S Lau, JCW Siu, CM Chan, SCH Chan Audit of Ultrasonography for Diagnosis of Acute Appendicitis: a Retrospective Study *J HK Coll Radiol*. 2008;11:108-111
2. RK Jain, M Jain, CL Rajak, S Mukharjee, PP Bhattarcharyya, MR Shah Imaging of Acute Appendicitis : A Review *Ind J Radiol Imag* 2006 16:4: 523-532.
3. Susan L. Bratton, Charles M. Haberkern, and John H. T. Waldhausen Acute Appendicitis Risks of Complications: Age and Medicaid Insurance *Pediatrics* 2000; 106(1):75-78
4. Nuno Pinto Leite, José M. Pereira, Rui Cunha, Pedro Pinto, Claude Sirlin CT Evaluation of Appendicitis and Its Complications: Imaging Techniques and Key Diagnostic Findings *Am J Roentgenol* 2005; 185:406–417
5. Anuj Mishra Spontaneous appendico-cutaneous fistula: A rare complication *Eur J Radiol Extra* 2006; 59:19-21
6. Abraham Mammen, Shaji Ponnambathayil, K. Karthikeya Varma, E. K. Suresh Kumar A rare complication of appendicitis: appendiculorenal sinus with renal cellulitis *Pediatr surg Int* (2005) 21: 582- 584.
7. Cunnigaiper Dhanasekaran Narayanan, Achi Ranganath Bhaskarappakash, Balakumar vijay, Shanthi Vijayaraghavan, Varadachari Srinivasan Rare finding of a gastrojejuno appendicular fistula during a laparotomy for roux-en-y conversion *Int J Surg* 2008; 6(6): 86-88.
8. F. Golfam, S. K. Forootan, P. Golfam, A. R. Khalajl, S. S. Sayedmortaz Appendicovesical fistula: a rare complication of appendicitis *Acta Medica Iranica*, 2008; 46(2): 159-162
9. WH Park, SO Choi, SK Woo, SS Lee Appendicumbilical fistula as a sequela of perforated appendicitis *J Pediatr Surg* 1991; 26(12): 1413-1415
10. A.A. Creangaa, R.R. Genadryb Obstetric fistulas: A clinical review *Int J Gynecol Obstet* (2007) 99:S40–S46.
11. Jagdish S, Ninan S, Pai D, Ratnakar C. Spontaneous appendicocutaneous fistula. *Indian J Gastroenterology* 1996;15:31
12. Kneeece SM, Wackym PA, Dudley BS, Sawyers JL, Gray GF Jr. Appendicovaginal fistula and primary appendiceal cystadenocarcinoma *South Med J*. 1987 Jul;80(7):914-6.
13. Athanassopoulos A, Speakman MJ. Appendicovesical fistula. *Int Urol Nephrol* 1995;27:705
14. C.-A. Vasilevsky, P. Belliveau, J. L. Trudel, B. L. Stein and P. H. Gordon Fistulas complicating diverticulitis *Int J Colorectal Dis* 1998; (13): 57-60.
15. Steel MC, Jones IT, Webb D. Appendicovesical fistula arising from appendiceal diverticulum suspected on barium enema. *ANZ J Surg*. 2001; 71(12):769-770.
16. Gaitini D, Beck-Razi N, Mor-Yosef D, et al. Diagnosing acute appendicitis in adults: accuracy of color doppler sonography and MDCT compared with surgery and clinical follow up *Am J Roentgenol*. 2008; 190:1300-6.
17. Chan I, Biknell SG, Graham M. Utility and diagnostic accuracy of sonography in detecting appendicitis in a community *Am J Roentgenol*. 2005; 184:1809-12.
18. M. H. Nguyen, Joseph Zakon, Tim Wagner, David Lloyd Imaging of an enterovaginal fistula with flexible colposcopy, an endoscopic retrograde cholangiopancreatography cannula and radiographic screening *ANZ J Surg*. 2004 ;74(10): 905–907
19. Carson, C.C., Malek, R.S. Remine, W.H. Urologic aspects of vesicoenteric fistula. *J.urol.*1978; 119: 744.
20. Steinberg R, Freud E, Dinari G, Schechtman Y, Zer M. Appendicovesical fistula in a child with Crohn's disease: a unique case. *J Pediatr Gastroenterol Nutr*. 1999; 29(1):99-100.
21. Ikeda I, Miura T, Kondo I. Case of vesico-appendiceal fistula secondary to mucinous adenocarcinoma of the appendix. *J Urol*. 1995;153(4):1220-1221.
22. Lund PG, Krogh J. Appendicovesical fistula associated with neuroma of the appendix. *Urol Int*. 1988;43(6):362-363.
23. Felix Schier Appendico-ileal fistula in cystic fibrosis *J Pediatr Surg*1986;35:634-635

**Author Information**

**Priyank S Chatra, DMRD, DNB**

Dept of Radiology, Yenepoya medical college

**Vinayaka U S, DMRD, DNB**

Dept of Radiology, Yenepoya medical college