

Abdominal Tuberculosis In A Hernial Sac: A Rare Presentation

M Vashist, N Singhal, M Verma, S Deswal, S Mathur

Citation

M Vashist, N Singhal, M Verma, S Deswal, S Mathur. *Abdominal Tuberculosis In A Hernial Sac: A Rare Presentation*. The Internet Journal of Surgery. 2012 Volume 28 Number 2.

Abstract

Tuberculosis is very common in countries like India. It may be pulmonary or extrapulmonary. In extrapulmonary tuberculosis one of the common sites is the abdomen. In the abdomen it may involve peritoneum, gastrointestinal tract, omentum and lymph nodes. Diagnosis of abdominal tuberculosis from presence of straw-coloured fluid in the hernial sac and slight thickening of omentum and sac is extremely rare. This requires high index of suspicion so that timely treatment can be started and complications can be minimized. The authors present a case of abdominal tuberculosis diagnosed on the basis of suspicion arising out of presence of an excessive amount of peritoneal fluid in the hernial sac and by taking a biopsy from the hernial sac which confirmed the diagnosis of tuberculosis. Meshplasty was done and the patient was put on multidrug antitubercular treatment with uneventful recovery.

CASE REPORT

Abdominal tuberculosis (TB) is a common entity in India. It has been extensively studied and various modes of presentations and diagnostic modalities have been described, but to diagnose it primarily at the operating table through the contents of a hernia sac while performing hernia repair (a common surgical problem) is extremely rare.

We describe here a case of a 50-year-old male patient who presented with a right inguinoscrotal swelling of 6 months duration. On examination the patient had a right complete indirect inguinal hernia. He had no history suggestive of tuberculosis. His chest x-ray done for pre-anaesthetic checkup was normal. At the operating table, on inguinal exploration, an indirect inguinal hernial sac was found. The sac was dissected and on opening the sac, along with omentum (content of sac) a large amount of straw-colored fluid came out. The omentum was slightly thickened but there were no tubercles in the omentum suggestive of tuberculosis. Suspicious about the presence of a large amount of straw-colored fluid in the hernia sac, a biopsy of sac wall and omentum was taken and sent for histopathology. Repair of hernia was done with prolene meshplasty.

Post-operative recovery of the patient was uneventful. There was no wound infection. Histopathology report showed fibrocollagenous tissue with dense inflammatory infiltrate

along with numerous Langhans giant cells (Figure 1) and necrotizing granulomatous inflammation in fibroadipose tissue (Figure 2) which were suggestive of tuberculosis. The patient was put on multidrug antitubercular treatment and was doing well at follow-up after 3 months. There was no mesh-related complication.

Figure 1

Figure 1: Histopathology from wall of hernial sac showing fibrocollagenous tissue with dense inflammatory infiltrate along with numerous Langhans giant cells (H&E, 20x)

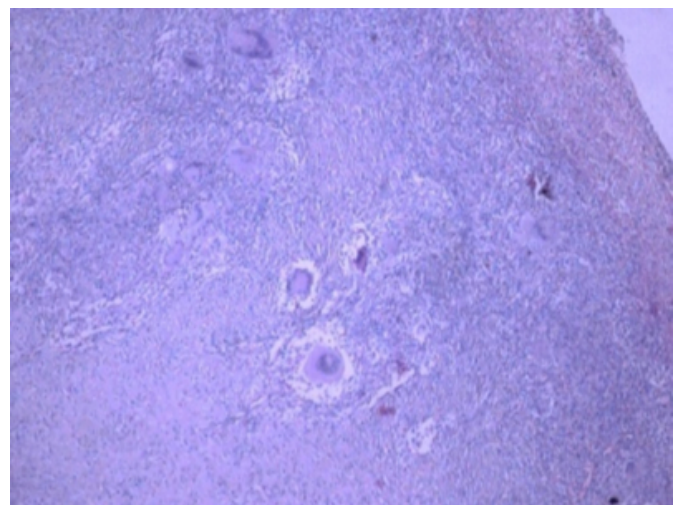
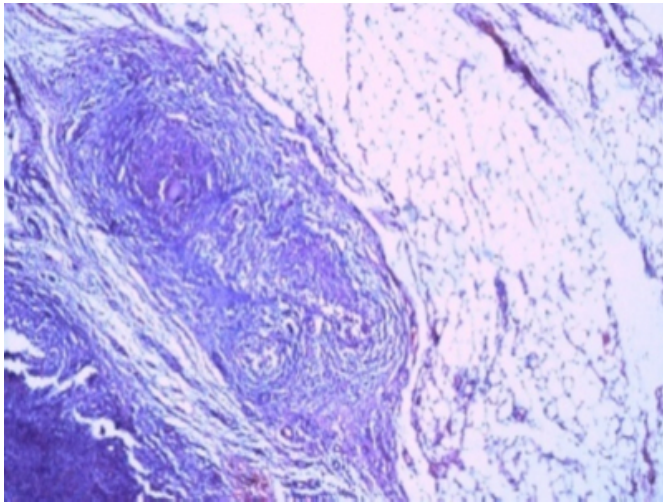


Figure 2

Figure 2: Histopathology from wall of hernial sac showing necrotizing granulomatous inflammation in fibroadipose tissue (H&E, 40x)



DISCUSSION

Tuberculosis is common in India, be it pulmonary or extra pulmonary. Pimparkar found evidence of abdominal tuberculosis in 3.72% of autopsies carried out in KEM hospital Mumbai¹. Omentum thickening is commonly seen in tubercular peritonitis². Inguinal hernia is one of the commonest surgical problems encountered in day-to-day practice and with omentum being a common content of the sac, the association between abdominal tuberculosis and inguinal hernia should not be a rare one but surprisingly, not many cases have been reported in literature^{3,4}.

Common features which should raise the suspicion of

tuberculosis in a hernia sac are presence of an excessive amount of straw-colored fluid, thickened omentum, thickened wall of hernia sac and presence of tubercles in omentum or hernia sac. Basrur et al. suggested modified Bassini repair as the method of treatment fearing mesh infection and recurrence risk in future⁵. In our case no adverse outcome was seen even with meshplasty. There was no wound infection. At follow-up after two weeks, on the basis of the biopsy report of tuberculosis, the patient was put on antitubercular treatment and at 3-month follow-up he did not report any complications.

Hence we suggest that during hernia repair, if the contents of the sac look suspicious, a biopsy should be taken for histopathology so that cases of tuberculosis can be diagnosed early and timely treatment can be started to decrease the rate of complications. If there is only suspicion without frank changes of tuberculosis as in our case, meshplasty can be done and antitubercular treatment should be started as soon as possible after confirming the diagnosis with biopsy report.

References

1. Pimparkar BD: Abdominal tuberculosis. *J Assoc Physicians India*; 1977; 25: 801-11.
2. Bhargava DK, Shriniwas MD, Chopra P, Nijhawan S, Dasarathy S, Kushwaha AK: Peritoneal tuberculosis: laparoscopic patterns and its diagnostic accuracy. *Am J Gastroenterol*; 1992; 87: 109-12.
3. Narasimharaw KL, Pradeep R, Mitra SK, Pathak IC. Abdominal tuberculosis presenting as inguinal hernia. *Indian Pediatr*; 1983; 20: 790-1.
4. Rao BJ, Kabir MJ, Varshney S: Richter's hernia: A rare presentation of abdominal tuberculosis. *Indian J Gastroenterol*; 1999; 18: 33.
5. Basrur GB, Naik RP, Doctor NH: Primary presentation of abdominal tuberculosis in an inguinal hernia. *Indian J Surg*; 2006; 68: 174.

Author Information

M. G. Vashist

Senior Professor and Unit Head Surgery, Department of Surgery and Pathology, Pandit B.D. Sharma Post Graduate Institute of Medical Sciences

Nitin Singhal

Resident Surgery, Department of Surgery and Pathology, Pandit B.D. Sharma Post Graduate Institute of Medical Sciences

Manish Verma

Assistant Professor Surgery, Department of Surgery and Pathology, Pandit B.D. Sharma Post Graduate Institute of Medical Sciences

Saurav Deswal

Resident Surgery, Department of Surgery and Pathology, Pandit B.D. Sharma Post Graduate Institute of Medical Sciences

S. K. Mathur

Senior Professor Pathology, Department of Surgery and Pathology, Pandit B.D. Sharma Post Graduate Institute of Medical Sciences