

Valvular Regurgitation And Rhythm Have Not An Impact On Mitral Valve Area: An Echocardiographic Study

? Demircanc

Citation

? Demircanc. *Valvular Regurgitation And Rhythm Have Not An Impact On Mitral Valve Area: An Echocardiographic Study*. The Internet Journal of Cardiology. 2012 Volume 10 Number 2.

Abstract

The assesment of severity of stenosis can be obtained by measuring mitral valve area (MVA) and transmitral pressure gradient. MVA can be mesured echocardiographically either pressure half-time (PHT) or planimetric methods. However, PHT may be inaccurate in some clinical settings such as aortic regurgitation (AR), mitral regurgitation (MR), poor left ventricular compliance, atrial fibrillation (AF) and immediately after mitral valvuloplasty. The effects of AR, MR and rhythm on PHT method are controversial. The aim of this study is to assess the correlation between planimetric and PHT methods in determining MVA and to investigate the effects of AR, MR , rhythm on MVA measured by PHT. Two hundred and one patients (31 male, 170 female) 16 to 72 years of age (mean age 40.9 ± 11.4) with MS were included in the study. A complete M-mode, two-dimensional and Doppler echocardiographic examinations were performed. Mitral valve area as measured by planimetry was $1.74 \pm 0.47 \text{ cm}^2$ (range 0.79-2.96), and from PHT was $1.66 \pm 0.49 \text{ cm}^2$ (0.5-2.75). MVA obtained by PHT were significantly less than those obtained by planimetry ($p < 0.001$). There was a good correlation ($r = 0.92$, $p < 0.001$) between planimetry and PHT method in pure MS and also in MS with AR, MS with MR and MS with AF ($r = 0.92$, $r = 0.91$, $r = 0.92$, respectively) Either PHT and planimetric methods may reliably be used in determining MVA because of the good correlation between them regardless of rhythm and associated valve lesions as AR and MR. However, using both methods together may help to derive more correct information and less mistakes.

INTRODUCTION

The predominant cause of mitral stenosis (MS) is rheumatic carditis. Isolated MS occurs in 40% of all patients presenting with rheumatic heart disease [1]. The timing of intervention, whether balloon catheter procedures or surgery is based on clinical status, the severity of anatomic lesion and the risks of ongoing medical therapy [1]. The assesment of severity of stenosis can be obtained by measuring mitral valve area (MVA) and transmitral pressure gradient. Previously, cardiac catheterization has been used as an accurate invasive method to obtain MVA and transmitral pressure gradient [2]. However two-dimensional (2-D) transthoracic echocardiography has been shown to be a reliable, reproducible, and accurate method of measuring MVA in patients with MS [3-5]. MVA can be measured noninvasively by using either planimetric method or Doppler pressure half-time (PHT) method [6-9]. Doppler PHT method has been described by Hatle et al. in 1979 [10]. This method has been shown to correlate well with cardiac catheterization and planimetric methods [10-12]. However, PHT may be inaccurate in some clinical settings by changing in initial pressure and compliance such as pregnancy, poor

left ventricular function, left ventricular hypertrophy, tachycardia and early after mitral valvuloplasty [13-16]. The presence of mitral regurgitation (MR) and aortic regurgitation (AR) with MS also may influence the PHT determination [17,18]. The effects of AR and MR on PHT method are controversial [19,20]. The aim of this study is to assess the correlation between planimetric and PHT methods in determining MVA and to investigate the effects of AR and MR on MVA measured by PHT.

MATERIAL AND METHODS

Two hundred and one patients patients (31 male, 170 female) 16 to 72 years of age (mean age 40.9 ± 11.4) with good quality of echocardiographic imaging were included in the study.

All patients were informed of the nature of the clinical trial and oral consent was obtained. The study was approved by the institutional review board. After physical examination, 12-lead electrocardiogram was obtained and all patients underwent transthoracic echocardiography. A complete M-mode, two-dimensional and Doppler echocardiographic

examinations were performed with a Toshiba SSH-160 A equipment (Toshiba, Tokyo, Japan), and a 2.5- or 3.5-MHz transducer was used. Echocardiographic images were obtained from the parasternal and apical windows with the patients in the left lateral recumbent position. All recordings were obtained at the end of expiration to get good quality images. Mitral valve area was measured by both direct planimetry and PHT method. In the short-axis view, MVA was obtained at the smallest valve orifice in early diastole. Patients were divided into three groups as Group I (MVA < 1.1 cm²), II (MVA 1.1-1.5 cm²) and III (MVA > 1.5 cm²) according to MVA obtained by planimetry [11]. Transmitral inflow velocities were recorded by continuous wave Doppler echocardiography from the apical four-chamber view. Valve areas were measured by averaging five beats in sinus rhythm and seven in atrial fibrillation (AF). Spectral Doppler was traced and analyzed to determine peak and mean transmitral gradients. PHT was obtained as described by Hatle et al. [9]. Doppler mitral valve area was estimated by 220/PHT formula [9]. A previously described echocardiographic assessment of mitral valve score was obtained in each patient by assigning values of 0 to 4 (with increasing abnormality) to each of four morphologic characteristics of the valve (i.e., leaflet mobility, thickening, calcification, and subvalvular thickening (score from 0 to 16) [21].

M-mode measurements were performed according to the recommendations of the American Society of Echocardiography [22].

The presence of mitral regurgitation was assessed by Doppler color flow mapping. The severity of regurgitation was evaluated in multiple views and graded from 0 to 4 according to the size and extent of the regurgitant jet within the left atrium (1 = trace, 2 = mild, 3 = moderate, and 4 = severe) [23]. The presence and severity of aortic regurgitation (grades 0 to 4) were evaluated based on the ratio of cross sections of the proximal regurgitant color jet and the left ventricular outflow tract, as described previously [23].

STATISTICAL ANALYSIS

All values were expressed as mean ± SD. Statistical analysis was performed using SPSS for Windows version 10.0 (SPSS, Inc, Chicago, Illinois). Student-t test was performed to compare the corresponding mean values. Correlation between planimetric and pressure half time method was analysed by the correlation test. Covariance analysis was

performed for testing whether there is an impact of regurgitations of the PHT area. A p value < 0.05 was considered statistically significant.

RESULTS

PATIENTS

201 patients (31 male, 170 female) 16 to 72 years of age (mean age 40.9 ± 11.4) were included in the study. The clinical characteristics of the patients are shown in Table 1.

Patients were divided into three groups according to MVA obtained by planimetry. Group I, II and Group III consisted of 17, 47, 137 patients, respectively. Echocardiographic measurements of all groups are shown in Table 2.

Sixty patients had pure MS. MS with AR and MS with MR were found in 84 (41.8%) and 117 (58.2%) patients, respectively (Table 1). MR was mild in 44.3 % of the patients, moderate in 12.9 % and severe 1 % (Table 1). AR was mild in 24.9 % of the patients, moderate in 13.4 % and severe 3.5% (Table 1).

RHYTHM VERSUS MITRAL VALVE AREA

In patients with sinus rhythm (n=129), mean MVA were 1.87 ± 0.45 cm² (range 0.90-2.96 cm²) and 1.79 ± 0.47 cm² (range 0.79-2.75 cm²) by planimetry and PHT, respectively (r= 0.88, p<0.001) (Table III-IV). In 72 patients with AF, MVA were 1.51 ± 0.41 cm² (range 0.79-2.54 cm²) and 1.41 ± 0.41 cm² (range 0.50-2.40 cm²) by planimetry and PHT respectively (r=0.92, p<0.001) (Table 3-4). MVA obtained in patients with AF were significantly less than those obtained in patients with sinus rhythm (p<0.001) (Table 3).

There was also a good correlation between PHT and planimetric method in AF and sinus rhythm (figure a).

Mitral valve area versus associated lesions

Mitral valve area as measured by planimetry was 1.74 ± 0.47 cm² (range 0.79-2.96), and from PHT was 1.66 ± 0.49 cm² (0.5-2.75) (Table 5).

Although, MVA obtained by PHT were significantly less than those obtained by planimetry (p<0.001), there was an excellent correlation between the valve areas determined by two methods in Group II and III. (Table 5). (Group II, r=0.56 p<0.001), (Group III, r=0.91, p<0.001). Whereas, no significant correlation was in Group I (r=0.30, p<0.240) (Table 5).

Valvular Regurgitation And Rhythm Have Not An Impact On Mitral Valve Area: An Echocardiographic Study

There was a good correlation ($r=0.92$, $p<0.001$) between planimetry and PHT method in pure MS and also in MS with AR and MS with MR ($r=0.90$, $r=0.90$ respectively) (Table 4). There was also a good correlation between PHT and planimetric method in mild, moderate and severe valve regurgitations (figure b, c). In covariance analysis this correlations did not change.

Figure 1

Table 1 . Clinical Characteristics of the Patients

Male/Female	31/170
Age	40.9 ± 11.4 (16 – 72)
AF/Sinus	129/72
AR	84(41.8%)
Mild	24.9%
Moderate	13.4 %
Severe	3.5%
MR	117(58.2%)
Mild	44.3%
Moderate	12.9%
Severe	1.0%
Valve Score	7.82 ± 2.5

MR: Mitral regurgitation, AR:Aortic regurgitation, AF: Atrial fibrillation

Figure 2

Table 2. Comparison of the Echocardiographic Findings of the Patients According to Mitral Valve Area.

	Group I	Group II	Group III
MVA-P (cm ²)	0.97 ± 0.11	1.29 ± 0.11	2.00 ± 0.34*
MVA-PHT(cm ²)	0.87 ± 0.16	1.25 ± 0.15	1.90 ± 0.38*
MMG (mmHg)	16.13 ± 6.07	12.25 ± 3.37	7.30 ± 3.02*
Valve Score	10.92 ± 1.5	9.18 ± 2.05	7.04 ± 2.27*
LAD (mm)	54.35 ± 6.91	52.25 ± 12.0	44.64 ± 8.35*
LVIDD (mm)	46.04 ± 3.88	47.9 ± 7.05	46.81 ± 6.31**

MVA-P: Planimetric mitral valve area, LVIDD: Left ventricular diastolic diameter

MVA-PHT: Mitral valve area derived from pressure half-time, LAD: Left atrial diameter

MMG: Mean mitral gradient , * $p<0.001$ ** Non-significant

Figure 3

Table 3. Mitral Valve Area According to Associated Lesions and Rhythm.

	Planimetric (MVA cm ²)		Doppler pressure half-time (MVA cm ²)	
	Present	Absent	Present	Absent
MR	1.75±0.46	1.73±0.48	1.66±0.47	1.65±0.51
AR	1.66±0.46	1.80±0.47	1.54±0.43	1.74±0.50
AF	1.51±0.41	1.87±0.45	1.42±0.42	1.79±0.47

MR: Mitral regurgitation, AR:Aortic regurgitation, AF: Atrial fibrillation

Valvular Regurgitation And Rhythm Have Not An Impact On Mitral Valve Area: An Echocardiographic Study

Figure 4

Table 4. Correlations Coefficients in Mitral Stenosis with Aortic Regurgitation with Mitral Regurgitation According to the Rhythm

Clinical Characteristic	Correlations coefficients
Aortic Regurgitation (+)	r=0.90
Aortic Regurgitation (-)	r=0.91
Mitral Regurgitation (+)	r=0.90
Mitral Regurgitation (-)	r=0.92
Atrial Fibrillation (+)	r=0.92
Sinus Rhythm (+)	r=0.88

Figure 5

Table 5. Mitral Valve Areas and Correlations Between Pressure Half-time and Planimetric Mitral Valve Area According to the Groups.

	MVA-P	MVA-PHT	r
Group I	0.97 ± 0.11	0.87 ± 0.16	r = 0.30**
Group II	1.29 ± 0.11	1.25 ± 0.15	r = 0.56*
Group III	2.00 ± 0.34	1.90 ± 0.38	r = 0.80*
All Group	1.74 ± 0.47	1.66 ± 0.49	r = 0.91*

MVA-P: Planimetric mitral valve area, MVA-D: Mitral valve area derived from pressure half-time

* p<0.001 ** Non-significant

Figure 6

Figure 1: Correlations between PHT and Planimetric Method in Mitral Stenosis Patients with Atrial Fibrillation (a), Aort Regurgitation (b) and Mitral Regurgitation (c).

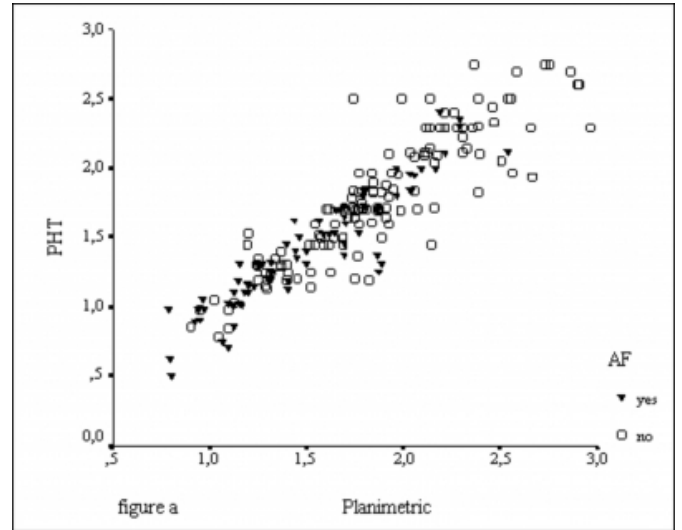


Figure 7

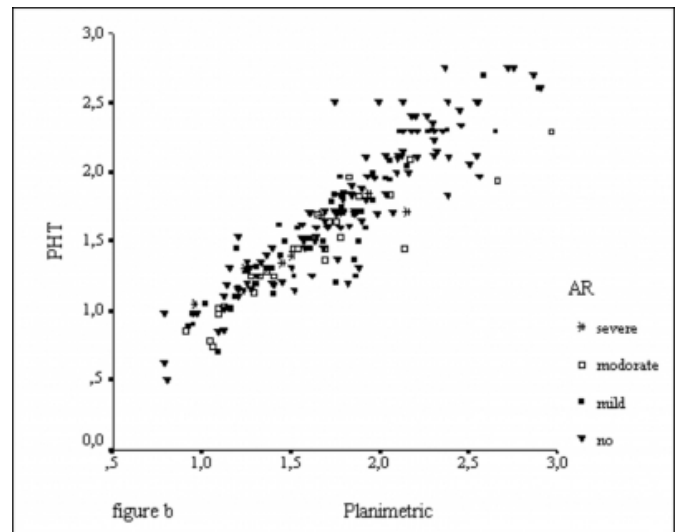
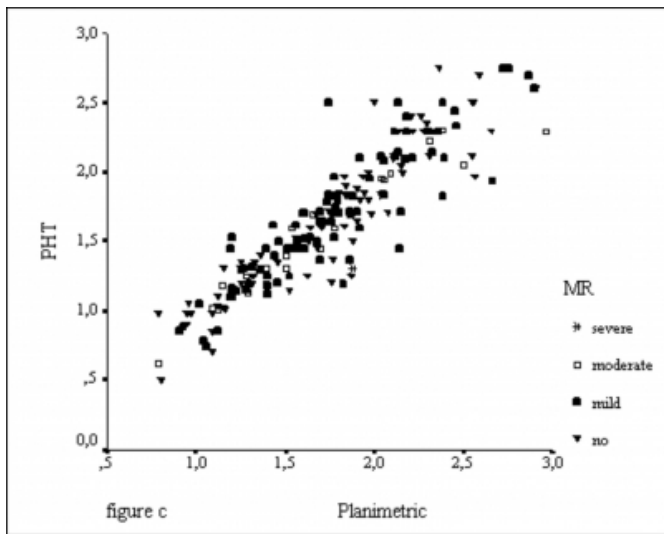


Figure 8



PHT: Pressure Half Time , MR: Mitral Regurgitation, AR:Aortic Regurgitation, AF: Atrial Fibrillation

DISCUSSION

The predominant cause of mitral stenosis is rheumatic carditis [1]. MS is associated with other valve abnormalities in 60% of all patients presenting with rheumatic heart disease [1]. In MS, timing of intervention, whether balloon catheter procedures or surgery is based on clinical status, the severity of anatomic lesion and the risks of ongoing medical therapy [1]. For this purpose, MVA must be measured correctly. Invasive and noninvasive methods can be used for measuring MVA. Previously, cardiac catheterization has been used as an accurate method to obtain MVA and transmitral pressure gradient [2]. These days, echocardiography which correlate well with cardiac catheterization is the preferred method to obtain MVA and transmitral pressure gradient [3-5].

MVA can be obtained echocardiographically either pressure half-time or planimetric methods. PHT indicates hemodynamic MVA, whereas planimetric methods provides an anatomic MVA. It has been described that planimetric method was the gold standard [19]. However, planimetric techniques may be dependent on gain and reject settings and be inaccurate in the presence of thickened, calcified mitral valve leaflets or previous commissurotomy [5]. Doppler echocardiography also has been shown to accurately reproduce the pressure gradient across the mitral valve , and the pressure half-time method has been shown to correlate well with cardiac catheterization and planimetric methods [10-12]. The PHT method is more accurate than planimetric

method in patients who had valvotomy operation [24,25]. However, PHT may be inaccurate in clinical settings such as pregnancy, left ventricular hypertrophy, aortic regurgitation, mitral regurgitation, poor left ventricular function, tachycardia and immediately after mitral valvuloplasty [13,14,17,18].

We obtained a significant correlation between planimetric and PHT methods in patients with mild and moderate MS as previously reported [19,26,27] whereas patients with severe MS did not show any correlation. Severe MS patients had also a higher valve score which may be due to the heavily calcified leaflets. It has been reported that the planimetric method may be inaccurate in the presence of thickened and calcified mitral leaflets [28].

We found that MVA obtained by PHT was significantly less than those obtained by planimetry. Similar result has been reported by other author [6]. This can be explained by the fact that the PHT is dependent on the inflow resistance due to mitral orifice and nonorifice components. Additional resistance of supavalvular apparatus can decrease flow rate and lead to a smaller MVA [6].

PHT may vary in patients with AF and changing cycle lengths make difficult to accurately determine diastolic transmitral gradient. It is required to average of at least 7 cycles in order to obtain an accurate diastolic transmitral gradient [29,30]. We found a good correlation between planimetric method and PHT method as previously described [29].

Doppler PHT method depends not only on mitral orifice area but also on left atrial compliance and left ventricular compliance and pressure gradient across the valve [13]. These parameters may be altered by aortic regurgitation. Aortic regurgitation might have an additional effect on pressure half-time. In AR, diastolic ventricular filling occurs from both left atrium and the aorta. Filling from aorta is not taken into account by the pressure half-time model. Ventricular diastolic filling from the aorta might be expected to cause the mitral gradient to fall prematurely when left ventricular pressure increases rapidly and exceeds left atrial pressure during diastole. Thus aortic regurgitation might be expected to decrease pressure half-time and thereby cause an overestimation of MVA [19].

On the other hand , aortic regurgitant jet may restrict opening of anterior mitral valve leaflet called “Austin Flint effect”. According to this effect, aortic regurgitation might

be expected to increase pressure half-time and thereby cause an underestimation of MVA [19].

Mega et al. and some others reported that AR overestimate the MVA [31, 32]. Nakatani and Moro et al. noted an overestimation only with moderate and severe AR but no significant difference with mild degree aortic regurgitation [33,34]. We found a good correlation between planimetric and Doppler PHT methods in MS despite presence of AR as others described [19,35].

MR may also affect the accuracy of PHT method by changing left atrial and left ventricular compliance. MR might be expected to cause the mitral gradient to fall prematurely due to increased left ventricular diastolic pressure thereby cause an overestimation of MVA. On the other hand, MR might underestimate MVA due to increasing in left atrial pressure [20]. In this study we have found a good correlation between planimetric and Doppler PHT methods in MS with MR. We may explain this finding as a change in the initial pressure gradient and chamber compliance in opposite direction. Similar results have also been found by others [20,29].

STUDY LIMITATIONS

Major limitations of our study are that the majority of our patients had only mild to moderate degree mitral and aortic regurgitation and the number of patients were not equal in three groups.

CONCLUSION

Either PHT and planimetric methods may reliably be used in determining MVA because of the good correlation between them regardless of rhythm and associated valve lesions as AR and MR. However, using both methods together may help to derive more correct information and less mistakes.

References

1. ACC/AHA guidelines for the management of patients with valvular heart disease. ACC/AHA Task force report. *J Am Coll Cardiol* 1998;1486-588.
2. Braunwald E, Valvular Heart Disease, Heart Disease: a Textbook of Cardiovascular Medicine, Fifth Edition, W.B. Saunders Company, Philadelphia:1994; 1007-1076.
3. Henry W, Griffith JM, Michaelis LL, McIntosh CL, Morrow AG, Epstein SE. Measurement of mitral orifice area in patients with mitral valve disease by real-time two-dimensional echocardiography. *Circulation* 1975; 51:827-831.
4. Loperfido F, Laurenzi F, Gimigliano F, et al. A comparison of the assesment of mitral valve area by continuous wave Doppler and by cross sectional echocardiography. *Br Heart J* 1987; 57:348-355.
5. Martin RP, Rakowski H, Kleiman JH, Beaver W, London E, Popp RL. Reliability and reproducibility of two- dimensional echocardiographic measurement of the stenotic mitral valve orifice area. *Am J Cardiol* 1979;43:560-568.
6. Faletra F, Pezzano A, Fusco R, et al. Measurement of mitral valve area in mitral stenosis: Four echocardiographic methods compared with direct measurement of anatomic orifices. *J Am Coll Cardiol* 1996;28:1190-1197.
7. Holen J, Simonsen S. Determination of pressure gradient in mitral stenosis with Doppler echocardiography. *Br Heart J* 1979;41:529-535.
8. Nishimura RA, Rihal CS, Tajik AJ, Holmes DRJr. Accurate measurement of the transmitral gradient in patients with mitral stenosis: A simultaneous catheterization and Doppler echocardiographic study. *J Am Coll Cardiol* 1994; 24:152-158.
9. Hatle L, Angelsen B. *Doppler Ultrasound in Cardiology: Physical Principles and Clinical Applications. Pulsed and continuous wave Doppler in diagnosis and assessment of various heart lesions. Second Edition. Lea&Febiger Philadelphia. 1985; 110-124.*
10. Hatle L, Angelsen B, Tromsdol A. Noninvasive assesment of atrioventricular pressure half-time by Doppler ultrasound. *Circulation* 1979; 60:1096-1104.
11. Holen J, Aaslid R, Landmark K, Simonsen S. Determination of pressure gradient in mitral stenosis with a noninvasive ultrasound Doppler technique. *Acta Med Scand* 1976;199 : 455 - 460.
12. Stamm RB, Martin RP. Quantification of pressure gradients across stenotic valves by Doppler ultrasound. *J Am Coll Cardiol* 1983;1:707-718.
13. Braverman AC, Thomas JD, Lee RT. Doppler echocardiographic estimation of mitral valve area during changing hemodynamic conditions. *Am J Cardiol* 1991; 68:1485-1490.
14. Bryg RJ, Gordon PR, Kudesia VS, Bhatia RK. Effect of pregnancy on pressure gradient in mitral stenosis. *Am J Cardiol* 1989; 63:384-386.
15. JD Thomas, GT Wilkins, CY Choong, VM Abascal, IF Palacios, PC Block and AE Weyman. Inaccuracy of mitral pressure half-time immediately after percutaneous mitral valvotomy. Dependence on transmitral gradient and left atrial and ventricular compliance. *Circulation* 1988;78, 980-993
16. Thomas JD, Weyman AE. Doppler mitral pressure half-time: a clinical tool in search of theoretical justification. *J Am Coll Cardiol* 1987 Oct;10(4):923-9.
17. Wisenbaugh T, Berk M, Essop R. Effect of mitral regurgitation and volume loading on pressure half-time before and after balloon valvotomy in mitral stenosis. *Am J Cardiol* 1991;67:162-168.
18. Flachskampf FA, Weyman AE, Gillam L. Aortic regurgitation shortens Doppler pressure half-time in mitral stenosis: Clinical evidence, in vitro simulation and theoretic analysis. *J Am Coll Cardiol* 1990;16:396-404.
19. Robiolio PA, Rigolin VH, Harrison JK, Kisslo KB, Bashore TM. Doppler pressure half-time method of assessing mitral valve area: Aortic insufficiency does not adversely affect

- validity. *Am Heart J* 1998; 136:718-23.
20. Fredman CS, Pearson AC, Labovitz AJ, Kern MJ. Comparison of hemodynamic pressure half-time method and Gorlin formula with Doppler and echocardiographic determinations of mitral valve area in patients with combined mitral stenosis and regurgitation. *Am Heart J* 1990; 119:121-129.
21. Wilkins GT, Weyman AE, Abascal VM, Block PC, Palacios IF. Percutaneous mitral valvotomy: an analysis of echocardiographic variables related to outcome and mechanism of dilatation. *Br Heart J* 1988; 60:299-308.
22. Sahn DJ, DeMaria AN, Kisslo J, Weyman AE. Recommendation regarding quantitation in M-mode echocardiography: results of a survey of echocardiographic measurements. *Circulation* 1978;58:1072-83.
23. Takamoto S, Kyo S, Adachi H, Matsumura M, Yokote Y, Omoto R. Intraoperative color flow mapping by real-time two-dimensional Doppler echocardiography for evaluation of valvular and congerital heart disease and vascular disease. *J Thorac Cardiovasc Surg* 1985; 90:802-812.
24. Come PC, Riley MF, Diver DJ, Morgan JP, Safian RD, McKay RG. Noninvasive assessment of mitral stenosis before and after percutaneous balloon mitral valvuloplasty. *Am J Cardiol* 1988; 61: 817-825.
25. Smith MK, Handshoe R, Handshoe S, Kwan OL, DeMaria AN. Comperative accuracy of two-dimensional echocardiography and Doppler pressure half-time methods in assessing severity of mitral stenosis in patients with and without prior commissurotomy. *Circulation* 1986;73:100-107.
26. Oku K, Utsunomiya T, Mori H, Yamachika S, Yano K. Calculation of mitral valve area in mitral stenosis using the proximal isovelocity surface area method: Comparison with two-dimensional planimetry and Doppler pressure half time method. *Jpn Heart J* 1997; 38:811-819.
27. Hatle L, Angelsen B, Tromsdal A. Noninvasive assessment of atrioventricular pressure half-time by Doppler ultrasound. *Circulation* 1979; 60(5):1096-1104.
28. Weyman AE, Principles and Practice of Echocardiography, Chapter 17. Left Ventricular Inflow Tract I: The Mitral Valve. 391-470. Second edition, Lea&Febiger, Philadelphia, 1994.
29. Bryg RJ, Williams GA, Lobovitz AJ, Aker U, Kennedy HL. Effect of atrial fibrillation and mitral regurgitation on calculated mitral valve area in mitral stenosis. *Am J Cardiol* 1986; 57:634-638.
30. Ramon G, Gasco C, Casares L, et al. The effect of the duration of the cardiac cycles on determining mitral valve area by means of pressure half-time. *Rev Esp Cardiol* 2000; 53(2):194-9.
31. Gilliam L, Chong YA, Wilkins GT, et al. The effect of aortic insufficiency on Doppler pressure half-time calculations of mitral valve areas in mitral stenosis (abstract). *Circulation* 1986;74:II-217.
32. Kawahara T, Yamagishi M, Seo H et al. Application of Doppler color flow imaging to determine valve area in mitral stenosis. *J Am Coll Cardiol* 1994; 18:85-92.
33. Moro E, Nicolosi GL, Zanuttini D, Cervesato E, Roelandt J. Influence of aortic regurgitation the assesment of the pressure half-time and derived mitral valve area in patients with mitral stenosis. *Eur Heart J* 1988; 9:1010-7.
34. Nakatani S, Masuyama T, Kodama K, Kitabatake A, Fujii K, Kamada T. Value and limitations of Doppler echocardiography in the quantification of stenotic mitral valve area: comparison of the pressure half-time and yhe continuity equation methods. *Circulation* 1988; 77:78-85.
35. Grayburn PA, Smith MD, Gurley JC, Booth DC, DeMaria AN. Effect of aortic regurgitation on the assessment of mitral valve orifice area by Doppler pressure half-time in mitral stenosis. *Am J Cardiol* 1987; 60:322-326.

Author Information

Enol Demircanc, MD

Department of Cardiology, School of Medicine, Baskent University