

Eosinophilic Cholecystitis Mimicking Adenomyomatosis.

S Aggarwal, P Garg, V Rathee, A Narang, S Mittal, S Verma, G Garg

Citation

S Aggarwal, P Garg, V Rathee, A Narang, S Mittal, S Verma, G Garg. *Eosinophilic Cholecystitis Mimicking Adenomyomatosis*. The Internet Journal of Surgery. 2012 Volume 28 Number 4.

Abstract

Eosinophilic cholecystitis (EC) is an infrequent and poorly understood inflammatory condition of the gallbladder, first described in 1949 by Albot and colleagues as an inflammatory condition of the gallbladder in which the inflammatory infiltrate is composed predominately of eosinophils so that their presence clearly overshadows the presence of any other inflammatory cell components. EC has been reported alone or in combination with manifestations such as eosinophilic cholangitis, hypereosinophilic syndromes (HES), and parasitic infestations. Large numbers of eosinophils in the inflammatory infiltrate occurred three times more commonly in patients with acalculous cholecystitis than in patients with cholelithiasis.

INTRODUCTION

Eosinophilic cholecystitis is a rare form of cholecystitis, characterized histologically by a dense, transmural eosinophilic infiltrate^{1,2}. It is an uncommon condition that was first described in 1949 by Albot and colleagues. It has a clinical presentation similar to that of typical cholecystitis; etiology is not sharply defined but suggested to be associated with allergic disease, local diathesis involving gallstones, parasites and acalculous cholecystitis, hypereosinophilic syndromes (where the eosinophils invade tissues such as brain, heart, lung, liver, and gallbladder), and eosinophilic gastroenteritis (EGE)²⁻⁷. Eosinophilic infiltration of the gastrointestinal tract may occur in these conditions also in eosinophilic granulomatous hepatitis and eosinophilic ascites⁸. The symptoms observed vary as to the location and depth of the gastrointestinal tract affected.⁹

CASE SUMMARY

A 30-year-old lady presented with an episode of cholecystitis 6 month back followed by mild continuous pain in the right upper quadrant of the abdomen associated with vomiting, particularly after meals. She had lost 6kg weight in the last 5 months. Her past medical history was significant for anti-tuberculosis treatment 1 year back (no clinico-investigative evidence of tuberculosis). There was no allergy. The physical examination was essentially normal.

Initial laboratory investigations showed a white blood count of 5700/mm³ with only 2 % eosinophils. Her liver function tests, renal function tests and complete urine examination were within normal limits. She had undergone serial

ultrasonography of the abdomen which showed microlithiasis on few occasions with thick gall bladder wall with echogenic foci in the gall bladder wall. Her barium meal follow-through was normal. Upper gastrointestinal endoscopy revealed moderate antral gastritis with grade II reflux oesophagitis. On contrast-enhanced computed tomography of the abdomen, diffuse thickening of the muscularis wall with proliferation and formation of intramural diverticula was found and a provisional diagnosis of adenomyomatosis of the gall bladder was made.

The patient underwent an open cholecystectomy. Intra-operatively, the gall bladder was very thick-walled with enlarged cystic and pericholedochal lymphnodes, but there was no evidence of cysts or any ascites or organ infiltration (fig. 1). A small wedge of the liver was resected along with the gall bladder (fig. 2). Histo-pathological examination reported eosinophilic cholecystitis. The postoperative period was uneventful and she was discharged. On follow-up she had gained 4 kg weight in one month.

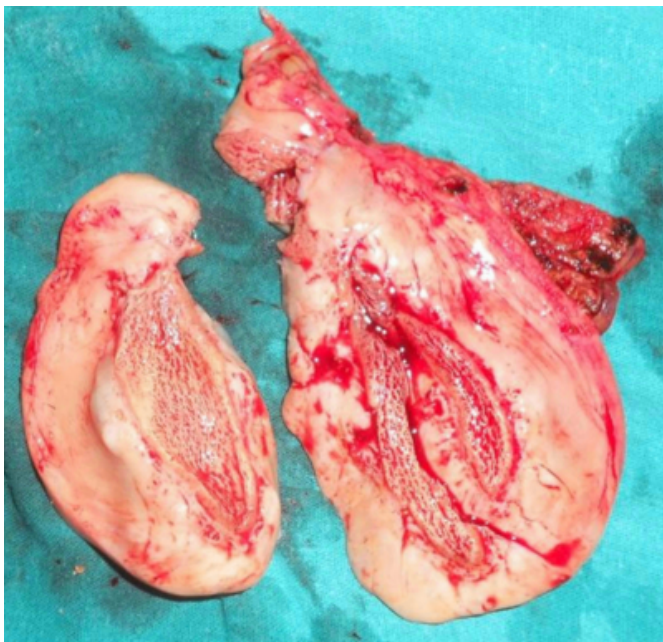
Figure 1

Fig. 1: Photograph showing a thick gall bladder with no evidence of any cyst or lymph node.

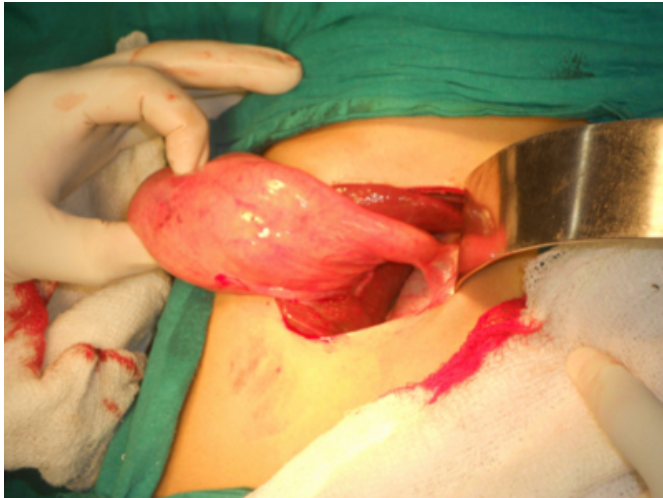

Figure 2

Fig. 2: Cut section of gall bladder showing very thick gall bladder wall.



DISCUSSION

Most of gall stones diseases are asymptomatic, but they become symptomatic when there is obstruction in the neck of gallbladder or cystic duct, cholecystitis being one of sequels of symptomatic gall stones. In cholecystitis, the inflammatory process involves influx of inflammatory cells in the wall of the gall bladder. Lymphocytes, macrophages, and neutrophils comprise the inflammatory infiltrate along with mucosal edema, vascular congestion, and regions of necrosis. Sometimes, eosinophils come in abundance and

collect forming part of eosinophilic cholecystitis; there are signs of inflammation, granulation tissue, and fibroblast propagation¹⁰⁻¹¹.

Eosinophilic infiltration of the gastrointestinal tract has also been reported to occur in many conditions, but the symptoms vary with the depth and location of the gastrointestinal tract affected.⁸ With mucosal invasion, post-prandial nausea and vomiting, diarrhea, malabsorption, and protein-losing enteropathy are observed, while with muscularis propria invasion, abdominal distention and partial or complete bowel obstruction are the main issue and with subserosal invasion, abdominal pain, distention and ascites occur.⁹

Fox et al. conducted a study in 1972 which included 625 cholecystectomy specimens, out of which 16 had eosinophilic infiltration.¹⁰ Based upon different histologic features of the inflammatory infiltrate, the majority was included in "eosinophils comprising up to 50% of cells", which consisted of group one of two in the study.

Various etio-pathogenesis has been proposed for this condition.¹⁴ Some authors have reported eosinophilic infiltration of the gall bladder or other parts of the gastrointestinal tract with some allergic stimulant while others have reported it without any association, which is known as idiopathic.^{1-9,11-15} Literature describes it to be mainly associated with parasites^{2-3,13} and drugs^{1,6,15} or to be a part of a syndrome.^{7-9,12,15} Peripheral eosinophilia is also found in some patients as in the expression of hypereosinophilic syndromes^{1,8}. As no association was found in our case, it was considered as idiopathic eosinophilic cholecystitis. Pathologic examination showed eosinophilic infiltration without any evidence of parasites. The patient recovered remarkably as evident by gaining weight and no investigation was found to show peripheral eosinophilia till last follow-up.

References

1. Felman RH, Sutherland DB, Conklin JL, Mitros FA: Eosinophilic cholecystitis, appendiceal inflammation, pericarditis, and cephalosporin-associated eosinophilia. *Dig Dis Sci*; 1994; 39: 418-22.
2. Kim YH: Eosinophilic cholecystitis in association with clonorchis sinensis infestation in the common bile duct. *Clin Radiol*; 1999; 54: 552-4.
3. Russell CO, Dowling JP, Marshall RD: Acute eosinophilic cholecystitis in association with hepatic echinococcosis. *Gastroenterology*; 1979; 77: 758-60.
4. Dabbs DJ: Eosinophilic and lymphoeosinophilic cholecystitis. *Am J Surg Pathol*; 1993; 17: 497-501.
5. Adusumilli PS, Lee B, Parekh K, Farrelly PA: Acalculous eosinophilic cholecystitis from herbal medicine: a review of

adverse effects of herbal medicine in surgical patients. *Surgery*; 2002; 131: 352-6.

6. Tenner S, Roston A, Lichtenstein D, Brooks D, Herlihy E, Carr-Locke D: Eosinophilic cholangiopathy. *Gastrointest Endosc*; 1997; 45: 307-9.

7. Hepburn A, Coady A, Livingstone J, Pandit N: Eosinophilic cholecystitis as a possible late manifestation of the eosinophilia-myalgia syndrome. *Clin Rheumatol*; 2000; 19: 470-2.

8. Butler TW, Feintuch TA, Caine WP Jr. : Eosinophilic cholangitis, lymphadenopathy, and peripheral eosinophilia: a case report. *Am J Gastroenterol*; 1985; 80: 572-4.

9. Rodriguez HE, Djohan RS, Cahill WJ, Connolly MM, Podbielski FJ: Laparoendoscopic diagnosis of eosinophilic enteritis. *JSLs*; 1998; 2: 181-4.

10. Fox H, Mainwaring AR: Eosinophilic infiltration of the

gallbladder. *Gastroenterology*; 1972; 63: 1049-52.

11. Hellstrom HR: Eosinophilic and lymphoeosinophilic cholecystitis. *Am J Surg Pathol*; 1994; 18: 215-6.

12. Tajima K, Katagiri T: Deposits of eosinophil granule proteins in eosinophilic cholecystitis and eosinophilic colitis associated with hypereosinophilic syndrome. *Dig Dis Sci*; 1996; 41: 282-8.

13. Shah OJ, Shah P: Ascariasis-induced eosinophilic cholecystitis--a unique case. *HPB*; 2006; 8: 72-3.

14. Parry SW, Pelias ME, Browder W: Acalculous hypersensitivity cholecystitis: hypothesis of a new clinicopathologic entity. *Surgery*; 1988; 104: 911-6.

15. Adusumilli PS, Lee B, Parekh K, Farrelly PA: Acalculous eosinophilic cholecystitis from herbal medicine: a review of adverse effects of herbal medicine in surgical patients. *Surgery*; 2002; 131: 352-6.

Author Information

Sourabh Aggarwal, M.B.B.S

Department of Surgery, Pt. B. D. Sharma Post Graduate Institute of Medical Sciences

Pradeep Garg, M.S, D.N.B

Department of Surgery, Pt. B. D. Sharma Post Graduate Institute of Medical Sciences

Vazir Sigh Rathee

Department of Surgery, Pt. B. D. Sharma Post Graduate Institute of Medical Sciences

Amit Narang, M.B.B.S.

Department of Surgery, Pt. B. D. Sharma Post Graduate Institute of Medical Sciences

Sachin Mittal, M.B.B.S.

Department of Surgery, Pt. B. D. Sharma Post Graduate Institute of Medical Sciences

Surender Verma, M.S

Department of Surgery, Pt. B. D. Sharma Post Graduate Institute of Medical Sciences

Gulshan Garg, M.S

Department of Surgery, Pt. B. D. Sharma Post Graduate Institute of Medical Sciences