

When In Doubt Do A Wide Local Excision: A Case Report Of An Unusual Presentation Of Cutaneous Metastasis From Breast Cancer

R B Werner, S Misra

Citation

R B Werner, S Misra. *When In Doubt Do A Wide Local Excision: A Case Report Of An Unusual Presentation Of Cutaneous Metastasis From Breast Cancer*. The Internet Journal of Surgery. 2014 Volume 31 Number 1.

Abstract

Breast cancer most commonly will metastasize to regional lymph nodes, bone, lungs, brain and liver. We report a 49-year-old woman with a subcutaneous metastatic nodule in her upper left back. The patient was diagnosed with invasive ductal carcinoma of the right breast and had undergone a modified radical mastectomy and chemoradiation two and a half years prior to appearance of the nodule. She underwent surgical removal of the nodule and pathological studies confirmed the mass was a subcutaneous lesion consistent with metastasis from her previous cancer.

INTRODUCTION

Though rare, with a reported incidence of 0.7% to 10%, nearly 51% of cutaneous metastases are attributed to breast cancer^{1,2} mainly in local regional site. We report a case of cutaneous metastases in skin of the left upper back from breast cancer treated with prior radical mastectomy and chemoradiation of the contralateral breast.

CASE PRESENTATION

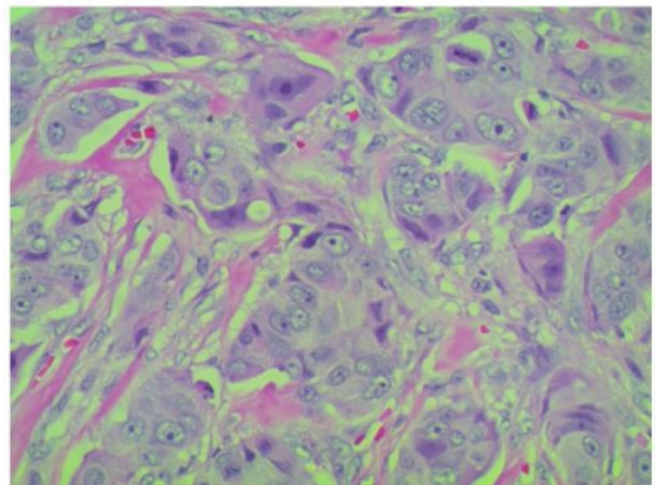
A 49-year-old female with a history of ER+/PR+ stage IIIB breast cancer was treated with a right modified radical mastectomy and chemoradiation. Two and a half years later, she presented with a new-onset nodule in the left upper back which was concerning for cancer. The patient underwent excision of the subcutaneous nodule and adjacent tissue which measured approximately 3.4cm wide by 1.0cm long by 2.4 cm deep. A rim of fatty tissue was also excised in a circumferential manner from around the nodule.

Pathological reports of the excised nodule demonstrated metastatic adenocarcinoma, consistent with the patient's clinical history of mammary ductal carcinoma with clear margins. (Figure 1)

HER-2/neu Fluorescence Hybridization demonstrated an average HER2 copy number of 6.3 making her eligible for Herceptin therapy. Additional workup with CT revealed metastasis to her liver. The patient then underwent chemotherapy.

Figure 1

Tissue specimen demonstrating metastatic adenocarcinoma (PAS staining; x400)



DISCUSSION

Breast cancer typically metastasizes via hematogenous spread to the bone, lungs, brain, liver and regional lymph nodes. Cutaneous lesions are a rare event and occur as a later event in metastatic disease. The location of cutaneous lesions is usually associated with the site of primary cancer with lesions of the chest wall from breast or lung cancer and metastatic cutaneous lesions located on the abdomen originating from the ovaries, bladder, or colon³. In a review of 164 cases of cutaneous metastases in female breast carcinoma, the most common presentation was

nodular metastatic carcinoma which is seen in 80% of cases. The most common sites of metastasis were the site of mastectomy and anterior chest with over 75% of cases⁴. Other locations included the axilla, back and scalp. Cutaneous metastases can present as solitary or multiple, pink to reddish, firm, or even ulcerated nodules⁵.

In cases of cutaneous metastases, it is important to have a high index of suspicion for metastasis to other organs. A post-surgery restaging workup should be performed and include genetic status assessment of the resected cancer compared to the original. Having a high index of suspicion can ensure that an oncologically appropriate area of marginal tissue is resected in order to completely remove cancerous tissue at the cutaneous site and prevent need for further surgery at the site of excision.

References

1. Manohar K, Mitall BR, Bhattacharya A, Singh G: Asymptomatic distant metastases detected by 18F-FDG-PET/CT in a patient with breast carcinoma. *World J Nucl Med*; 2012; 11: 24-5.
2. Benevento R, Santoriello A, Perna G, Canonico S: Electrochemotherapy of cutaneous metastases from breast cancer in elderly patients: a preliminary report. *BMC Surg*; 2012; 12: S6.
3. Anelli TF, Anelli A, Tran KN, Lebowitz DE, Borgen PI: Tamoxifen administration is associated with a high rate of treatment-limiting symptoms in male breast cancer patient. *Cancer*; 1994; 74: 74-7.
4. Hu SC, Chen GS, Wu CS, Chai CY, Chen WT, Lan CC: Rates of cutaneous metastases from different internal malignancies: Experience from a Taiwanese medical center. *J Am Acad Dermatol*; 2009; 60: 379-87.
5. Poovaneswaran S, Lee Z EJ, Lim WY, Gopal NSR, Dali FM, Mohamad I: S Poovaneswaran, Lee ZE, Lim WY, et al.: Cutaneous lesions as a presenting sign of metastases in male breast cancer: a rare clinical entity. *Med J Malaysia*; 2013; 68: 168-70.

Author Information

Robert Blake Werner, MSIV

Texas Tech University Health Sciences Center
Amarillo, TX

Subhasis Misra, MD, MS, FACCWS

Texas Tech University Health Sciences Center
Amarillo, TX