

Spontaneous Retroperitoneal Hematoma Due To A Bleeding Disorder Presenting As Acute Abdomen: Successful Non Operative Management : Case Report

S Chandramohan, D Kannan, R Rajamahendran, C Madeswaran, R Sandeep, B Duraisamy, A Amudhan, R Prabhakaran

Citation

S Chandramohan, D Kannan, R Rajamahendran, C Madeswaran, R Sandeep, B Duraisamy, A Amudhan, R Prabhakaran. *Spontaneous Retroperitoneal Hematoma Due To A Bleeding Disorder Presenting As Acute Abdomen: Successful Non Operative Management : Case Report*. The Internet Journal of Gastroenterology. 2014 Volume 14 Number 1.

Abstract

Bleeding disorders presenting as acute abdomen mimicking intra abdomen emergency is a well established entity. Surgery with a mistaken diagnosis can be disastrous. We report a case, presented to the department as acute abdomen proved to be retroperitoneal hematoma, referred to us as retroperitoneal abscess. Careful evaluation and review of the old records proved that he had von Willie brand disease. He was successfully managed conservatively only with FFP.

INTRODUCTION

Von Willie brand disease is a common bleeding disorder inherited in humans. In most cases it is mild and goes unnoticed, unless the patient undergoes any dental extraction or any surgery. The prevalence of this disease is estimated to be 1% to 2% of the general population. There are three types of VWD. Type 1 and 2 are mild types and type 3 is characterized by severe clinical manifestations like hemophilia. These patients will have prolonged bleeding time and activated partial thromboplastin time with normal prothrombin time. Musculo-skeletal hemorrhage occurs commonly in vWD type-3 like hemophilic patients. Iliopsoas hemorrhage is a serious complication because a delay in beginning treatment may result in hemorrhagic shock or a permanent femoral nerve palsy. The present case report describes a man with Spontaneous Iliopsoas hematoma that responded well to Fresh frozen plasma.

CASE PRESENTATION

A 32 year old gentleman was referred as acute abdomen from department of Orthopaedics and Trauma. He has had in-patient treatment twice at Orthopaedic department as psoas abscess in past 6 weeks. Image guided aspiration has yielded only blood stained aspirate.

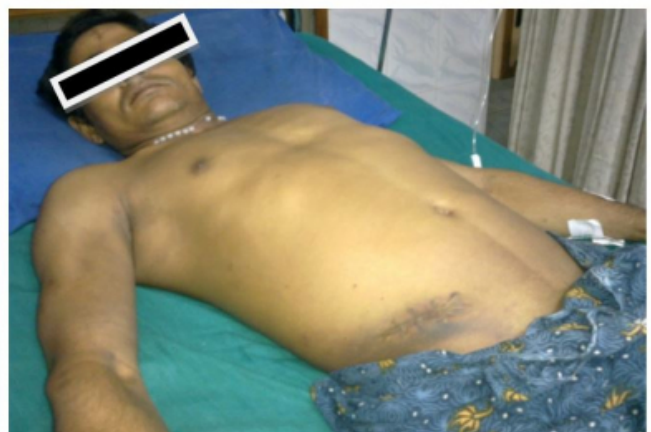At presentation, he had severe abdominal pain especially in the right side, more in lower abdomen and back and inability

to extend the hip. He had no history of trauma and no genitourinary or any other bowel symptoms.

Examination revealed diffuse tenderness in right upper and lower abdomen and in the loin. The hip was in flexed posture and attempts at extension were very painful. He was anemic but his vitals were stable (Figure 1).

Figure 1

Appendectomy scar with surrounding ecchymosis



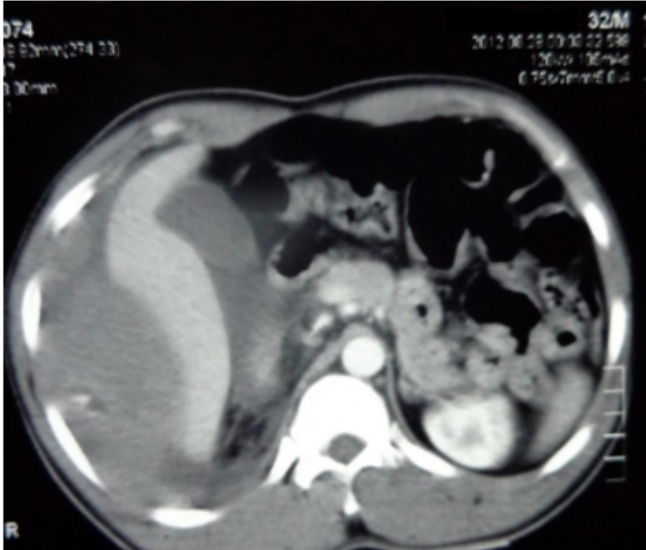
CECT revealed a huge iliopsoas hematoma(50 HU) (Figure 2)extending from the subhepatic space up to pelvis, pushing and rotating the kidney antero medially (Figure 3).

Hemoglobin was 7.7 gm%, Prothrombin time was 11 seconds, INR- 1.06, activated partial thromboplastin time

was elevated 109 seconds (Normal value- 25 s -39 s)

Figure 2

CECT revealing a large retroperitoneal hematoma



Suspecting the possibility of a bleeding disorder, his old records from his childhood were looked into, which revealed the following:

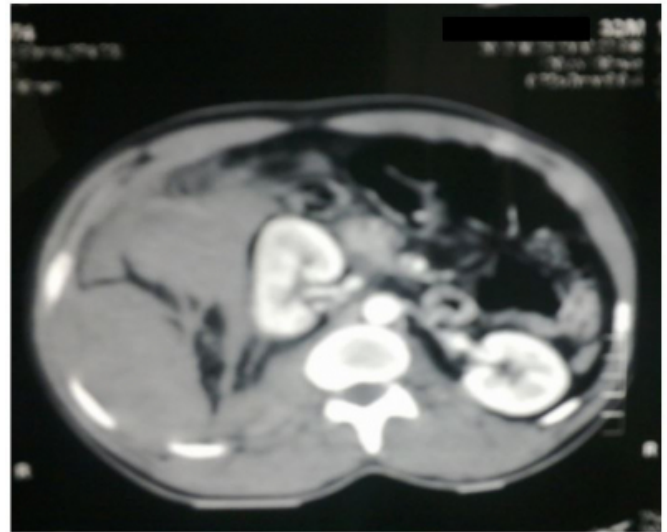
He has been diagnosed to have von Willie brand disease at the age of 9 years (1988) when he presented with continuous bleeding following trivial trauma while playing.

He had history of falling into the well and had treatment in Neurosurgery department for which conservative management was done at the age of 15 years (1995)

He had undergone an appendectomy at the age of 22 years (2002) when he presented with right lower quadrant pain, and he has received 5 units of fresh frozen plasma and 5 units of blood to control the bleeding.

Figure 3

(CECT abdomen showing kidney pushed anteromedially)



In view of the above the final diagnosis of a spontaneous bleed due to Von Willie brand disease was made and he was managed conservatively. He received 8 units of FFP and 8 units of packed cells. The patient gradually improved and his pain decreased, tenderness decreased, aPTT returned to 30 seconds. On recovery we found that he could extend his leg and there is no residual motor or sensory weakness. At the time of discharge (after 12 days) he was able to extend the leg comfortably, stand up and walk without difficulty. Repeat CECT abdomen taken after a month shows significant reduction in size of hematoma and kidney regaining its near normal position (Figure 4).

DISCUSSION

Iliopsoas hemorrhage, whether spontaneous or traumatic, is encountered in a variety of coagulation disorders, such as hemophilia. The first case was reported by Tallroth in 1939 [1].

Symptomatic spontaneous bleeding due to von Willie brand disease is very rare. When it presents with intrabdominal or retroperitoneal bleed the diagnosis can be made by ultrasonography, computed tomography and MRI. Once established, non-operative treatment can be tried using factor VIII replacement and fresh frozen plasma. Our case was successfully managed conservatively using FFP alone. There was only one similar case reported by Beijing Keikhaei and Ahmad Soltani Shirazi [2] who had been treated with high purity factor VIII concentrate.

CONCLUSION

This case report describes that spontaneous iliopsoas hematoma can also occur in Von willie brand disease. Careful history taking, clinical suspicion, appropriate evaluation by CECT or MRI and hematological evaluation will help establishing the diagnosis and appropriate management. Surgery without proper evaluation can prove to be disastrous. After careful search of literature we have

found that our case is the second reported case so far and first one to be treated only with fresh frozen plasma.

References

1. Tallroth A: Hemophilia with spontaneous hemorrhage in the iliopsoas muscle followed by injury to the femoral nerve. Acta Chirurgica Scandinavica 1939, 82:1.
2. Keikhaei and Soltani Shirazi Journal of Medical Case Reports 2011

Author Information

S.M. Chandramohan, MCh, FACS, Head of the Department

Department of Surgical Gastroenterology Center of Excellence for upper GI Surgery, Madras Medical College and Rajiv Gandhi Government General Hospital

Chennai, India

smchandra@yahoo.com

D. Kannan, Professor

Department of Surgical Gastroenterology Center of Excellence for upper GI Surgery, Madras Medical College and Rajiv Gandhi Government General Hospital

Chennai, India

R Rajamahendran, Post graduate

Department of Surgical Gastroenterology Center of Excellence for upper GI Surgery, Madras Medical College and Rajiv Gandhi Government General Hospital

Chennai, India

C Madeswaran, Post graduate

Department of Surgical Gastroenterology Center of Excellence for upper GI Surgery, Madras Medical College and Rajiv Gandhi Government General Hospital

Chennai, India

R Sandeep, Post Graduate

Department of Surgical Gastroenterology Center of Excellence for upper GI Surgery, Madras Medical College and Rajiv Gandhi Government General Hospital

Chennai, India

Benet Duraisamy, Assistant professor

Department of Surgical Gastroenterology Center of Excellence for upper GI Surgery, Madras Medical College and Rajiv Gandhi Government General Hospital

Chennai, India

A Amudhan, Assistant professor

Department of Surgical Gastroenterology Center of Excellence for upper GI Surgery, Madras Medical College and Rajiv Gandhi Government General Hospital

Chennai, India

R. Prabhakaran

Department of Surgical Gastroenterology Center of Excellence for upper GI Surgery, Madras Medical College and Rajiv Gandhi Government General Hospital

Chennai, India